

## Acetazolamide-Induced Bilateral Choroidal Effusion Following Insertion of a Phakic Implantable Collamer Lens

Victoria de Rojas, MD, PhD; Félix González-López, MD;  
Julio Baviera, MD

### ABSTRACT

**PURPOSE:** To present the case of a 28-year-old man with acetazolamide-induced bilateral choroidal effusion after uneventful surgery of the second eye in delayed sequential bilateral insertion of an implantable collamer lens for hyperopia.

**METHODS:** Case report.

**RESULTS:** Surgery of the left eye was uneventful, and the implantable collamer lens was implanted 3 weeks later in the right eye. Twenty-four hours after surgery, the patient presented with bilateral shallow anterior chamber, vault 0, and myopic shift (-8 diopters) in both eyes. B-scan ultrasound showed choroidal thickening in both eyes, which was consistent with choroidal effusion syndrome. A causal relationship was suspected with oral acetazolamide, which had been prescribed after surgery. When the drug was stopped, the condition improved slowly and resolved completely within 5 days.

**CONCLUSIONS:** Choroidal effusion should be included in the differential diagnosis of shallow anterior chamber after implantation of an implantable collamer lens.

[J Refract Surg. 20XX;XX(X):XX-XX.]

Sulfonamide drugs have been associated with choroidal effusion, although this adverse event is infrequent.<sup>1</sup> We present a case of acetazolamide-induced bilateral choroidal effusion with narrow chamber after insertion of an implantable collamer lens (ICL). Although rare, both malignant glaucoma and pupillary block glaucoma are well-known complications of the procedure, that also present with shallow chamber and high intraocular pressure (IOP) early after surgery. Thus, choroidal effusion should be included in the differential diagnosis of high IOP and shallow anterior chamber following implantation of an ICL.

From *Clínica Baviera, Instituto Oftalmológico Europeo, Spain (VR, FG-L, JB); and the Department of Ophthalmology, Complejo Hospitalario Universitario, A Coruña, Spain (VR).*

Submitted: January 12, 2013; Accepted: April 18, 2013

The authors have no financial or proprietary interest in the materials presented herein.

Correspondence: Victoria de Rojas, MD, PhD, *Clínica Baviera, Plaza de Galicia, 2, A Coruña, Spain. E-mail: derojas.v@gmail.com*

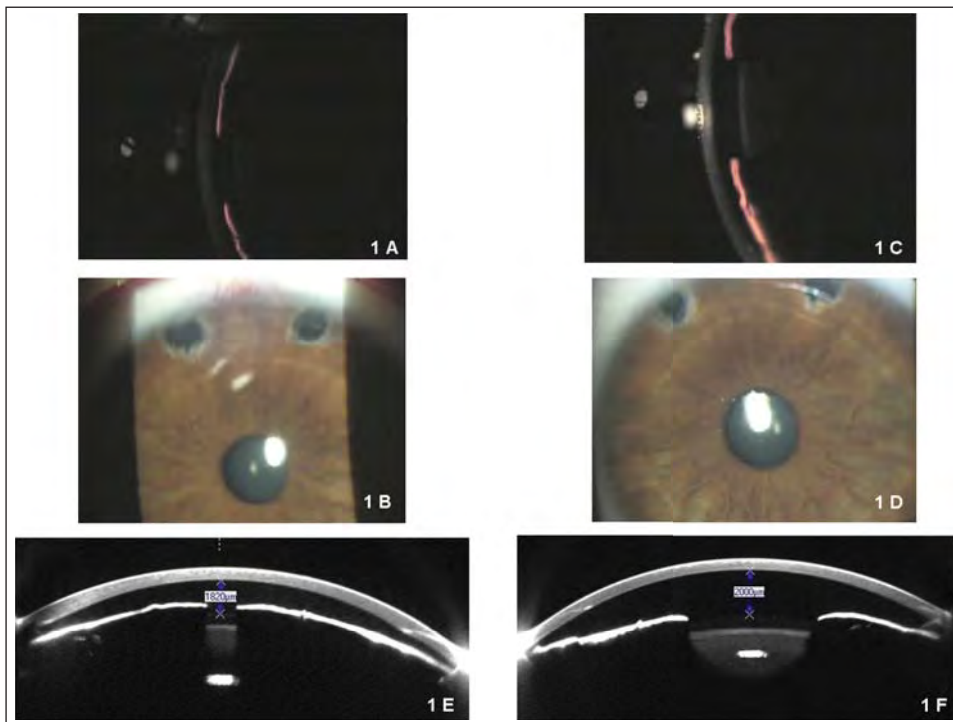
### CASE REPORT

A 28-year-old man underwent surgical correction of hyperopia. Preoperative assessment showed corrected distance visual acuity of 20/20 and 20/32 with a refraction of +6 -1.5 × 10° and +6.25 -1.5 × 165° in the right and left eye, respectively. IOP was 19 mm Hg in both eyes. White-to-white distance as measured with Orbscan (Bausch & Lomb, Rochester, NY) was 12.25 and 12 mm in the right and left eye, respectively, and mean keratometry was 41.25 diopters in both eyes. Automated perimetry was within normal limits in both eyes, and the endothelial cell count measured by noncontact specular microscope SP2000P (Topcon, Oakland, CA) was 2,741 and 2,916 cells/mm<sup>2</sup> in the right and left eye, respectively. The anterior chamber depth measured by A-scan ultrasound was 3.86 mm in both eyes, and thickness was 640 and 611 μm in the right and left eye, respectively; thus, anterior chamber depth from endothelium measured 3.25 and 3.24 mm in the right and left eye, respectively. Fundus examination was normal in both eyes.

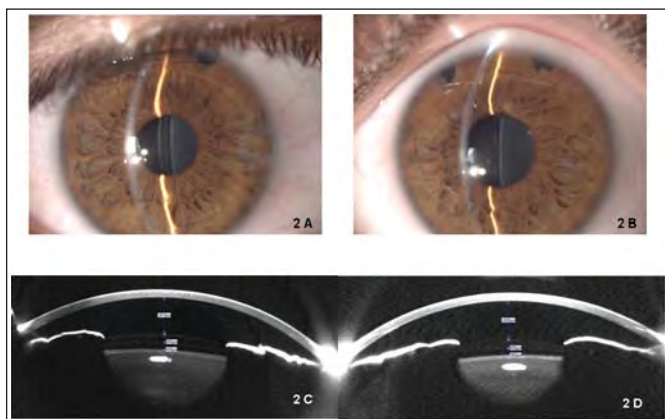
A decision was made to implant ICLs with intraoperative paired opposite incisions in both eyes. Fifteen days before surgery in the left eye, two laser peripheral iridotomies were performed in both eyes. The ICL was implanted in the left eye without complications (VICH 12.6 +6.5AQ1). The patient was prescribed 250 mg of oral acetazolamide every 12 hours (two doses), topical moxifloxacin 0.5% every 8 hours, and tobramycin 0.3% together with dexamethasone 0.1% every 6 hours. On postoperative day 1, uncorrected distance visual acuity in the left eye was 20/32, IOP was 19 mm Hg with a deep and quiet anterior chamber and a vault of 370 μm. Three weeks later, the ICL was implanted in the right eye without complications (VICH 13.2 +6AQ1). The same treatment was prescribed for the left eye.

Twenty-four hours later, uncorrected visual acuity was less than 0.05 in both eyes (counting fingers) and improved to 20/30 and 20/50 with refraction of -8.25 -0.75 × 10° and -8.25 -1.5 × 180° in the right and left eye, respectively. Biomicroscopy showed a shallow chamber with vault 0 in both eyes (**Figure 1**) and an IOP of 27 and 22 mm Hg in the right and left eye, respectively. The Seidel test results were negative. Iridotomies were patent, and gonioscopy revealed appositional angle closure in both eyes. Funduscopy was not performed to avoid pupil dilation in this setting of appositional angle closure, and B-scan ultrasonography showed flat choroidal thickening consistent with choroidal effusion syndrome in both eyes.

Because of the bilateral involvement, a drug etiology was considered and a causal relationship with oral acetazolamide was suspected. The patient was treated with hourly topical prednisolone acetate 1%, topi-



**Figure 1.** Slit-lamp photography of the (A and B) right eye and (C and D) left eye 1 day after surgery in the second eye (right) showing bilateral shallow anterior chamber with vault 0 and patent iridotomies in both eyes. Pentacam (Oculus Optikgeräte GmbH, Wetzlar, Germany) Scheimpflug imaging of the anterior segment revealed an anterior chamber depth of 1,820 and 2,000  $\mu\text{m}$  in the (E) right and (F) left eye, respectively, on day 2 after surgery of the right eye. Vault was 0 in both eyes.



**Figure 2.** Slit-lamp photography 5 days after surgery in the (A) second eye (right) showing complete resolution, with a deep and quiet anterior chamber and appropriate vaulting in the right and (B) left eyes. Pentacam (Oculus Optikgeräte GmbH, Wetzlar, Germany) Scheimpflug imaging of the anterior segment revealed vaulting of 400 and 360  $\mu\text{m}$  in the (C) right and (D) left eye, respectively, and anterior chamber depth (endothelium to anterior surface of intraocular lens) of 2,400  $\mu\text{m}$  5 days after surgery in the right eye.

## DISCUSSION

To our knowledge, we present the first report of ciliochoroidal effusion after implantation of an ICL. However, this condition has previously been considered a theoretical component in the differential diagnosis of shallow anterior chamber early after implantation of an ICL, with the following alternatives<sup>2-4</sup>: pupillary block glaucoma, oversized ICL, incision leakage, ciliochoroidal effusion, suprachoroidal hemorrhage, and malignant glaucoma. In our case, the finding of patent iridotomy and vault 0, which indicated forward displacement of the natural lens, ruled out pupillary block induced by occluded iridotomy or excessive vaulting. The negative Seidel test result and the slightly high IOP enabled us to rule out wound leak. The condition could only have been caused by malignant glaucoma, ciliochoroidal effusion, or suprachoroidal hemorrhage. B-scan ultrasound revealed diffuse choroidal thickening consisting of a ciliochoroidal effusion, which results in anterior rotation of the entire ciliary body and forward shifting of the lens-iris diaphragm, thereby obstructing trabecular outflow. The annular ciliochoroidal effusion decreases the diameter of the ciliary body and produces zonular laxity, thus leading to thickening of the crystalline lens and a further forward shift of the lens. This series of events results in myopic shift and increased IOP.<sup>1</sup>

Because the presentation was bilateral after unilateral surgery the previous day, surgery was ruled out as the cause of the choroidal effusion and a drug-

cal timolol 0.5% every 12 hours, topical moxifloxacin 0.5% every 8 hours, and oral prednisone 50 mg every 24 hours. Five days later, the complication had fully resolved (**Figure 2**). Uncorrected visual acuity was 20/20 and 20/30 with vault of 400 and 360  $\mu\text{m}$  in the right and left eye, respectively. Anterior chamber depth was 2,400  $\mu\text{m}$  and IOP was 19 mm Hg in both eyes. Topical medication and systemic corticosteroids were tapered and withdrawn within 1 week.

associated etiology was suspected. Oral acetazolamide, which was used to prevent IOP spikes associated with the presence of a residual ophthalmologic viscoelastic device behind the ICL, is known to cause ciliochoroidal effusion, although this side effect is rare.<sup>1,5</sup> Two cases of bilateral acute angle-closure glaucoma have been reported after unilateral cataract surgery, and both were related to administration of oral acetazolamide after surgery.<sup>6,7</sup> Topical dorzolamide has also been involved in several cases of choroidal effusion.<sup>8,9</sup>

The exact pathogenic mechanism of ciliary body swelling induced by sulfonamide drugs is unknown. Although an allergic reaction has been proposed by some authors, Krieg and Schipper<sup>5</sup> found that rechallenge with the same medication failed to produce an identical event and speculated that the drug-induced increase in prostaglandin levels contributes to ciliary body edema. This could explain the absence of the complication when our patient underwent surgery in the first eye, after which he also received 250 mg of oral acetazolamide.

Final total anterior chamber depth from endothelium to anterior lens surface, as measured by Pentacam (Oculus Optikgeräte GmbH, Wetzlar, Germany) was 2,400  $\mu\text{m}$  from endothelium to anterior ICL surface, plus 400 and 360  $\mu\text{m}$  of vault in the right and left eye, respectively, plus 450  $\mu\text{m}$  of ICL thickness (**Figures 2C** and **2D**), which yielded a total of 3.2 mm of anterior chamber depth in both eyes after the resolution of the complication. This measurement compares well with preoperative anterior chamber depth as measured by A-scan ultrasound.

It is essential to highlight the importance of early recognition of this rare side effect and of immediate withdrawal of acetazolamide, which, in the setting of high IOP, could be continued erroneously if the surgeon is not aware of this rare adverse reaction.<sup>6-9</sup> The role of systemic corticosteroids is controversial, because these agents have been shown to cause choroidal effusion<sup>10</sup> and were ineffective in one of the cases quoted above.<sup>6</sup> However, Mancino et al.<sup>7</sup> speculated that the use of intravenous methylprednisolone in

their case led to quicker resolution. Fortunately, in our case, IOP was slightly elevated in both eyes but angle-closure glaucoma did not develop despite the narrow chamber. Because the suggested mechanism of angle closure does not involve pupillary block, pilocarpine and peripheral laser iridotomy were not useful; in fact, our patient had two patent iridotomies in each eye when the syndrome developed.

#### AUTHOR CONTRIBUTIONS

*Study concept and design (VR, FG-L, JB); data collection (VR, FG-L, JB); analysis and interpretation of data (VR, FG-L, JB); drafting of the manuscript (VR, FG-L, JB); critical revision of the manuscript (VR, FG-L, JB)*

#### REFERENCES

- Panday VA, Rhee DJ. Review of sulphonamide-induced acute myopia and acute bilateral angle-closure glaucoma. *Compr Ophthalmol Update*. 2007;8:271-276.
- Kohnen T, Kook D, Morral M, Güell JL. Part 2: Results and complications. *J Cataract Refract Surg*. 2010;36:2168-2194.
- Bylsma SS, Zalta AH, Foley E, Osher R. Phakic posterior chamber intraocular lens pupillary block. *J Cataract Refract Surg*. 2002;28:2222-2228.
- Khalifa Y, Goldsmith J, Moshirfar M. Bilateral explantation of Visian Implantable Collamer Lenses secondary to bilateral acute angle closure resulting from a non-pupillary block mechanism. *J Refract Surg*. 2010;26:991-994.
- Krieg PH, Schipper I. Drug-induced ciliary body edema: a new theory. *Eye (Lond)*. 1996;10:121-126.
- Parthasarathi S, Myint K, Singh G, Mon S, Sadasivam P, Dhilon B. Bilateral acetazolamide-induced choroidal effusion following cataract surgery. *Eye (Lond)*. 2007;21:870-872.
- Mancino R, Varesi Ch, Cerulli A, Aiello F, Nucci C. Acute bilateral angle-closure glaucoma and choroidal effusion associated with acetazolamide administration after cataract surgery. *J Cataract Refract Surg*. 2011;37:415-417.
- Doherty MD, Wride NK, Birch MK, Figueiredo FC. Choroidal detachment in association with topical dorzolamide: is hypotony always the cause? *Clin Exp Ophthalmol*. 2009;37:750-752.
- Davani S, Delbosc B, Royer B, Kantelip JP. Choroidal detachment induced by dorzolamide 20 years after cataract surgery. *Br J Ophthalmol*. 2002;86:1457-1458.
- Chandler, Grant. In: Shields BM, ed. *Textbook of Glaucoma*, 4th ed. Baltimore: Lippincott, Williams, & Wilkins; 1997:339-342.

#### AUTHOR QUERIES

**AQ1** Please provide the manufacturer and location.

**AQ2** Please provide the full names of the editors and name of chapter.