

# Complications in Corneal Laser Surgery

Stephan J. Linke  
Toam Katz *Editors*



Springer

# Complications in Corneal Laser Surgery

Stephan J. Linke • Toam Katz  
Editors

# Complications in Corneal Laser Surgery

 Springer

*Editors*

Stephan J. Linke  
Department of Ophthalmology  
University Medical Center Hamburg  
Eppendorf (UKE)  
Hamburg  
Germany

Toam Katz  
Department of Ophthalmology  
University Medical Center Hamburg  
Eppendorf  
Hamburg  
Germany

ISBN 978-3-319-41494-2      ISBN 978-3-319-41496-6 (eBook)  
DOI 10.1007/978-3-319-41496-6

Library of Congress Control Number: 2017931400

© Springer International Publishing Switzerland 2016

This work is subject to copyright. All rights are reserved by the Publisher, whether the whole or part of the material is concerned, specifically the rights of translation, reprinting, reuse of illustrations, recitation, broadcasting, reproduction on microfilms or in any other physical way, and transmission or information storage and retrieval, electronic adaptation, computer software, or by similar or dissimilar methodology now known or hereafter developed.

The use of general descriptive names, registered names, trademarks, service marks, etc. in this publication does not imply, even in the absence of a specific statement, that such names are exempt from the relevant protective laws and regulations and therefore free for general use.

The publisher, the authors and the editors are safe to assume that the advice and information in this book are believed to be true and accurate at the date of publication. Neither the publisher nor the authors or the editors give a warranty, express or implied, with respect to the material contained herein or for any errors or omissions that may have been made. The publisher remains neutral with regard to jurisdictional claims in published maps and institutional affiliations.

Printed on acid-free paper

This Springer imprint is published by Springer Nature  
The registered company is Springer International Publishing AG  
The registered company address is: Gewerbestrasse 11, 6330 Cham, Switzerland

# Preface

Since the early days of Excimer laser surgery to the cornea, the field of refractive and therapeutic laser application has evolved dramatically [1]. Laser refractive surgery of the cornea is at the current state widely accepted as a safe and effective standard procedure for surgical correction of low to moderate ametropia (i.e., myopia/hyperopia/astigmatism). Current literature and own data reveal the high safety and efficacy of the procedures. According to Price et al. [2], the risk of laser refractive surgery is comparable to contact lens wear regarding safety and side effects.

However, complications still occur and can subsequently result in reduced efficacy and safety of the procedure. Both human and technical sources of error exist. The first step in the string of pearls of complication management is the precise detection and correct diagnosis of a complication followed by its targeted immediate management.

In light of millions of refractive laser surgeries performed worldwide per year, we aim to provide a comprehensive textbook on complications and their management in refractive and therapeutic laser surgery of the cornea.

The list of possible complications includes intraoperative flap cutting errors, decentration of optical zone, incorrect transfer of laser parameters, and postoperative complications. Infectious keratitis and keratectasia are among the most severe postoperative complications and can result in permanent loss of vision.

Although the focus of this textbook is complications in corneal laser surgery, we include a chapter about corneal topography/tomography. Knowing and differentiating between regular and irregular shape of the cornea is mandatory for a reliable, safe, and straightforward screening process of refractive surgery candidates.

Establishing a consensus for laser refractive surgery indications/contraindications and treatment based on the current scientific knowledge can significantly improve surgical outcome and patient satisfaction.

A major strength of this book is the introduction of the full spectrum of laser application to the cornea from refractive to therapeutic including Excimer therapeutic and cornea transplant procedures.

The continuum of established (PTK/PRK/LASIK/FemtoLASIK//Femto and Excimer KP) and emerging technologies (ReLEx/SMILE) is covered by experienced experts in the respective fields.

We wish you a fruitful and constructive lecture.

Greetings from Hamburg.

Hamburg, Germany  
Hamburg, Germany  
February 2017

Stephan J. Linke  
Toam Katz

## References

1. Reinstein DZ, Archer TJ, Gobbe M. The history of LASIK. *J Refract Surg.* 2012;28(4):291–8.
2. Price MO, Price DA, Bucci FA Jr, Durrie DS, Bond WI, Price FW Jr. Three-year longitudinal survey comparing visual satisfaction with LASIK and contact lenses. *Ophthalmol.* 2016;123(8):1659–66.

# About the Authors

**Stephan J. Linke, MD, PhD**, graduated from Ruprecht-Karls University in Heidelberg, Germany. He finished his doctoral thesis in the department of transplant immunology in 2000. After specialization, Dr. Linke became the lead surgeon of the Cornea and Refractive Unit at the Department of Ophthalmology University Medical Center Hamburg-Eppendorf (UKE). In 2006, he co-initiated a fruitful clinical and scientific cooperation between CareVision and the UKE. After several years serving as senior refractive surgeon and training young fellows he founded zentrumsehstärke on the University Campus in 2014. The main focus of Dr. Linke is the cornea – he performs all therapeutic and refractive corneal procedures including keratoplasty. As a high volume surgeon he performed >10,000 LASIK surgeries within the past 10 years. He was repeatedly rewarded for his research in the field of refractive data analysis and keratoconus. Recently, Dr. Linke received the Dr. Karl-Robert Brauns prize (2016) for his work on a new technology for applanation free corneal trephination.



**Toam Katz, MD, PhD**, was born in Jerusalem where he also had his education. He graduated from medical school (Israel and Paris) and is a specialist in ophthalmology, anterior segment, and refractive surgery. He has been serving in the position of medical manager at CARE Vision (more than 16,000 refractive surgeries per year) for private refractive surgery in Germany and Austria, since 2006. In 2009, Toam Katz joined the largest ophthalmologist group of clinics in Spain (Clínica Baviera) and so far over 600,000 eye surgeries have been performed. Dr. Katz trained dozens of refractive surgeons and supports them in complication management and quality control. He is also a researcher and published numerous articles in the field of refractive corneal and lens surgeries and senior surgeon at the UKE University Hospital in Hamburg – Germany, specializing in anterior segment pathologies and therapeutic uses of the Excimer laser.





# Contents

## Part I Corneal Refractive Surgery: An Overview

- 1 Past, Present and Future of Excimer and Femtolasers  
Application to the Cornea** . . . . . 3  
Stephan J. Linke
- 2 Standardized Evaluation of Safety, Predictability and Efficacy.** . . . . 11  
Toam R. Katz
- 3 Safety, Predictability and Efficacy of LASIK.** . . . . . 19  
Toam R. Katz
- 4 Safety, Efficacy and Predictability of SAT** . . . . . 23  
Toam R. Katz

## Part II Errors in Corneal Refractive Surgery

- 5 Sources of Error in Corneal Refractive Surgery** . . . . . 33  
Toam R. Katz
- 6 Refractive Surgery in Systemic Diseases and  
Non Ectatic Eye Pathologies.** . . . . . 39  
Fernando Llovet, Julio Ortega-Usobiaga, and Andrea Llovet

## Part III Complications and Management in Laser Refractive Lamellar Surgery and Laser Refractive Surface Ablation

- 7 Microkeratome LASIK Intraoperative Complications.** . . . . . 51  
Toam R. Katz
- 8 FemtoLASIK Intraoperative Complications** . . . . . 65  
Theo Seiler

**9 Early (<3 Months) and Late (>3 Months) Complications of LASIK** . . . . . 75  
 Stephan J. Linke, Fernando Llovet, Julio Ortega-Usobiaga, Andrea Llovet, Julio Baviera, Mercedes Martínez-del-Pozo, Gonzalo Muñoz, Cesar Albarrán, and Toam R. Katz

**10 Complications and Management of SMILE.** . . . . . 111  
 Anders Ivarsen and Jesper Hjortdal

**11 Complications and Management in Laser Refractive Surface Ablation (SA).** . . . . . 127  
 Johannes Steinberg and Stephan J. Linke

**Part IV Post Corneal Refractive Surgery Ectasia (PRSE)**

**12 Post Refractive Surgery Ectasia** . . . . . 157  
 Renato Ambrósio Jr, Isaac Ramos, and Fernando Faria Correia

**Part V Complications and Management in Phototherapeutic and Laser Transplant Surgery**

**13 Therapeutic Excimer Ablation** . . . . . 177  
 Johannes Steinberg, Stephan J. Linke, and Toam R. Katz

**14 Complications and Management in Laser Transplant Surgery** . . . . . 199  
 Berthold Seitz, Moatasem El-Husseiny, and Achim Langenbacher

**Index.** . . . . . 227

# Contributors

**Cesar Albarrán, OD** Department of Refractive and Cataract Surgery,  
Clínica Baviera, Castellon, Spain

**Renato Ambrósio Jr., MD, PhD** Instituto de Olhos Renato Ambrósio,  
Rio de Janeiro, Brazil

VisareRIO, Rio de Janeiro, Brazil

Rio de Janeiro Corneal Tomography and Biomechanics Study Group,  
Rio de Janeiro, Brazil

Brazilian Study Group of Artificial Intelligence and Corneal Analysis – BRAIN,  
Maceio-AI, Brazil

Department of Ophthalmology, Federal University of São Paulo, Sao Paulo, Brazil

**Julio Baviera, MD** Department of Refractive and Cataract Surgery, Care-Vision,  
Frankfurt, Germany

**Fernando Faria Correia, MD** Rio de Janeiro Corneal Tomography  
and Biomechanics Study Group, Rio de Janeiro, Brazil

Life and Health Sciences Research Institute (ICVS), School of Health Sciences,  
University of Minho, Braga, Portugal

ICVS/3B's-PT Government Associate Laboratory, Braga/Guimaraes, Portugal

Ophthalmology Department, Hospital de Braga, Braga, Portugal

**Moatasem El-Husseiny** Department of Ophthalmology, Saarland University  
Medical Center UKS, Homburg/Saar, Germany

**Jesper Hjortdal, MD, DMSci, PhD** Department of Ophthalmology,  
Aarhus University Hospital, Aarhus, Denmark

**Anders Ivarsen, MD, PhD** Department of Ophthalmology,  
Aarhus University Hospital, Aarhus, Denmark

**Toam R. Katz, MD, PhD** Department of Ophthalmology, University Medical Center Hamburg Eppendorf, Hamburg, Germany  
CARE Vision Germany GmbH, Frankfurt/Main, Germany

**Achim Langenbucher, Dipl.-Ing** Department of Experimental Ophthalmology, Saarland University, Homburg/Saar, Germany

**Stephan J. Linke, MD, PhD** Department of Ophthalmology, University Medical Center Hamburg Eppendorf, CareVision, Hamburg, Germany  
CARE Vision Germany GmbH, Hamburg, Germany  
zentrumsehstärke, Hamburg, Germany

**Andrea Llovet, MD** Ophthalmology, Centro de Oftalmología Barraquer, Barcelona, Spain

**Fernando Llovet, MD, PhD** Department of Refractive and Cataract Surgery, Clínica Baviera, Madrid, Spain

**Mercedes Martínez-del-Pozo, MD** Department of Refractive and Cataract Surgery, Clínica Baviera, Madrid, Spain

**Gonzalo Muñoz, MD, PhD** Department of Refractive and Cataract Surgery, Clínica Baviera, Castellon, Spain

**Julio Ortega-Usoabiaga, MD, PhD** Department of Refractive and Cataract Surgery, Clínica Baviera, Bilbao, Spain

**Isaac Ramos, MD** Rio de Janeiro Corneal Tomography and Biomechanics Study Group, Rio de Janeiro, Brazil  
Brazilian Study Group of Artificial Intelligence and Corneal Analysis – BRAIN, Maceio-AL, Brazil  
Hospital de Olhos Santa Luzia, Maceio-AL, Brazil

**Theo Seiler, MD, PhD** Institut für Refraktive und Ophthalmologische Chirurgie, IROC, Zurich, Switzerland

**Berthold Seitz, ML, FEBO** Department of Ophthalmology, Saarland University Medical Center UKS, Homburg/Saar, Germany

**Johannes Steinberg, MD, PhD** zentrumsehstärke, Hamburg, Germany

**Part I**  
**Corneal Refractive Surgery: An Overview**

# Chapter 1

## Past, Present and Future of Excimer and Femtolaser Application to the Cornea

Stephan J. Linke

Lasers (light amplification by stimulated emission of radiation) have a long tradition in ophthalmic diagnostics and treatment. Photocoagulation was initially introduced by Prof. Gerd Meyer-Schwickerath in the eye clinic of the University Medical Center Hamburg Eppendorf (UKE) in 1949 [1, 2]. This was the first application worldwide in the eye transforming sunlight into a therapeutic radiation beam. However since the weather is not very stable in Hamburg the availability of the laser-photocoagulation source (sunlight) was neither stable nor reliable. Figure 1.1 shows Prof. Meyer-Schwickerath focusing the light onto the retina of a patient as long as sunlight was available. Several treatment sessions had to be performed to complete the intended photocoagulation process and safely attach the retina.

Ophthalmic lasers were then developed following initial work on microwave amplifying devices (masers). The first application of an alternative laser source to human tissue was reported by Theodor Maiman using a ruby Laser in 1960. Interestingly Maiman visited Germany several years later to undergo eye laser treatment. The excimer (= excited dimer) laser was originally described by Basov and colleagues in 1970. Trokel and his group developed the use of the 193 nm excimer laser for refractive correction [3]. But only the collaboration with Srinivasan, a photochemist at IBM Thomas J. Watson Laboratories, Ron Krueger (at that time electrical engineer and medical student) and John Marshall from the Institute of Ophthalmology in London improved the understanding of the nature of the excimer laser effect on the cornea and finally replaced the knife in radial keratotomy [4, 5]. A fundamental basic step on the journey to bladeless corneal surgery was done.

---

S.J. Linke, MD, PhD

Department of Ophthalmology, University Medical Center Hamburg Eppendorf,  
Martinistr. 52, 20246 Hamburg, Germany

zentrumsehstärke, Martinistr. 64, 20251 Hamburg, Germany

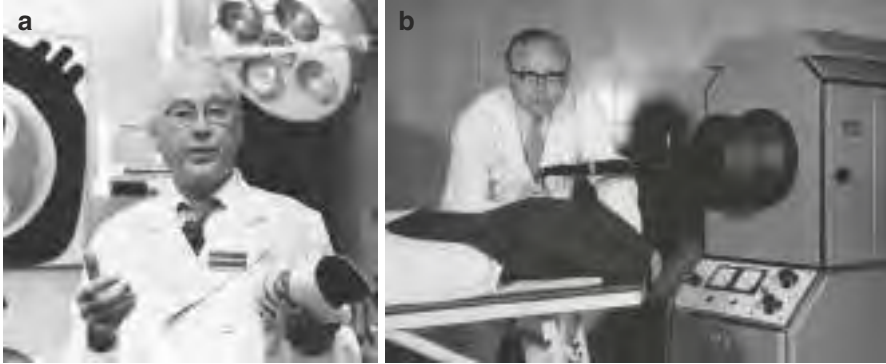CareVision Germany, Martinistr. 52, 20246 Hamburg, Germany

e-mail: [slinke@uke.de](mailto:slinke@uke.de)

© Springer International Publishing Switzerland 2016

S.J. Linke, T. Katz (eds.), *Complications in Corneal Laser Surgery*,

DOI 10.1007/978-3-319-41496-6\_1



**Fig. 1.1** (a, b) Prof. Gerd Meyer-Schwickerath focusing the radiation beam (sunlight) onto the retina of a patient (Courtesy of Dr. Rolf Meyer-Schwickerath, MD)

The first large area excimer laser ablation procedure was performed by Theo Seiler in Germany in 1985 to remove a corneal scar. McDonald treated the first human sighted eye due for enucleation in 1988 after extensive preclinical investigation [6, 7].

Laser frequency (often described through its reciprocal wavelength, for example 193 nanometer), pulse frequency, pulse energy, pulse duration, ablation rate and fluence determine the laser beam characteristics and its consecutive effect on the cornea. Although the “hardware” (=ArF) of excimer laser surgery has been maintained throughout the past 30 years, great advances in laser beam parameters, laser spot sizing, ablation profile and repetition rate have been achieved.

In addition eye tracking systems have been improved allowing seven dimensional tracking of the eye. At the time of the first refractive excimer procedures topography was very crude. Hardware and software have hand in hand greatly advanced in the past 30 years. More sophisticated diagnostic technology to evaluate the shape of the cornea (topography and tomography) in parallel to advances in laser platforms have resulted in better safety and efficacy of the procedures. The excimer laser energy has been delivered with three different types of laser platforms. Broad-beam lasers were used in the first-generation laser systems. They used a full laser beam with a diameter of 4 mm and internal masks or diaphragms for customized ablations, but the ablation plume sometimes resulted in untreated areas, so-called central islands [8]. Scanning-slit lasers used a smaller slit-shaped laser beam capable of rotation and were able to treat cylinders and larger-diameter ablation zones compared to broad-beam laser systems. Today, most modern excimer lasers are flying-spot lasers with precise eye tracking systems, allowing for more complex treatments such as wavefront-optimized, topography- and wavefront-guided treatments. Flying spot lasers use small circular laser spots with a diameter of <1 mm at high frequency (500 Hz) and sufficiently spatially and timely spaced to avoid thermal effects.

Overall, laser pulse frequency, energy and duration are important parameters to avoid slow treatment, thermal effects and variation in the laser ablation effect.

The amount of laser energy per unit of area needed for corneal photoablation is approximately  $50 \text{ mJ/cm}^2$  with temperature rise of  $11 \text{ }^\circ\text{C}$ . A subthreshold fluence can cause irregular and incomplete ablation. Corneal hydration affects ablation depth. Dehydration increases ablation depth and vice versa [9]. Individual surgeons' factors (treatment time, flap hydration and handling) have optimized the efficacy of the laser treatment. Nomogramms compensate for tissue dehydration during the treatment time.

## **Therapeutic Excimer Laser Application to the Cornea**

The first therapeutic application of excimer laser was to remove superficial corneal scars and to improve epithelial stability in recurrent corneal erosions (RCE). The second field of application has evolved with the merging advents of modern small diameter flying spot laser systems and topographic high precision corneal imaging systems enabling to precisely analyze and treat irregular corneas. The third domain is the use of excimer laser systems in the field of corneal transplantation. This technique was introduced by Prof Naumann and has been preserved and optimized by Prof. Seitz and colleagues.

Understanding the complex interaction between the laser beam and the corneal tissue at a cellular and molecular level has become an essential element in improving the efficacy and safety of refractive surgery procedures [10]. Corneal wound healing is one of the most important factors contributing to the predictability of laser refractive surgery. The biological response of the corneal tissue results in epithelial hyperplasia and stromal remodelling [11] and affects refractive stability and regression.

## **Photorefractive Keratectomy (PRK)**

The PRK procedure involves removal of the central corneal epithelium, most commonly performed mechanically after brief alcohol application to loosen the epithelium. Alternatively the epithelium can be removed in one layer with a blunt oscillating blade (EpiLASIK). The denuded anterior stroma is then reshaped by the excimer laser. Due to significant postoperative pain, slow visual recovery and high haze incidence in the early days, especially when treating high myopia [12], the intrastromal LASIK procedure was invented [13]. LASIK virtually eliminated the previously mentioned drawbacks, but instead flap-related complications appeared, as well as a higher risk of corneal ectasia [9]. Surface ablation of the cornea is therefore, by some surgeons, still considered the overall safest procedure for treatment of low to moderate myopia [14]. However the exceptionally long individual recovery time (>3 months) must be included into the preoperative considerations.



The introduction of mitomycin C, modern flying spot laser systems and the use of larger optical zones in modern surface ablation techniques have lowered the risk of haze and regression after PRK [15].

Apart from night-time visual disturbances and haze development, complications after treatment of low to moderate degrees of myopia are few. Also, patient satisfaction was often reported to be high, with most patients stating that they would undergo the procedure again [16].

## **Laser-Assisted In Situ Keratomileusis (LASIK)**

The term LASIK was first used in 1990 by Pallikaris, in which a micro-keratome was used to cut a hinged corneal flap, followed by excimer ablation of the stromal bed and flap repositioning [13]. LASIK/FemtoLASIK has now become the most common elective surgical procedure in the world, presumably because it is an almost painless surgical procedure with fast visual recovery, as compared to PRK [7]. These advantages have been documented in several reviews comparing PRK and LASIK, but they have also underlined that accuracy and safety were very similar in the two techniques for treatment of low to moderate myopia and when contemporary techniques such as wave-front-guided/optimized treatments and FSL flap creation were used [17]. Nonetheless, the deeper corneal cut in LASIK has made careful preoperative screening of patients even more important, to minimize the risk of the rare but feared complication of ectasia.

## **The Femtosecond Laser (FSL)**

The advent of the femtosecond-laser technology has further changed the field and application of lamellar refractive procedures. Although originally developed with the aim of performing intrastromal ablation [18] the femtolaser assisted preparation of a lamellar flap instead of using a microkeratome in 1999 was a turning point.

Meanwhile an estimated of 60% of LASIK procedures are performed as FemtoLASIK surgeries. The penetration rate of FemtoLASIK in the different regions worldwide varies widely.

The FSL utilizes a solid-state Nd:Glass laser source and applies ultra-fast ( $10^{-15}$  s) focused pulses at near-infrared wave-lengths (1064 nm) to create photo disruption at their focal point. The laser pulse generates a high-intensity electric field causing the formation of a mixture of free electrons and ions that constitutes the plasma state. The plasma then expands rapidly and displaces the surrounding tissue. The vaporized tissue forms a cavitation bubble in the focal volume of the laser beam, and when the laser bubbles fuse, cutting is completed. The process is called laser-induced optical breakdown (OBD), and the result is high-precision tissue cleavage

with minimum collateral damage. The technological evolution has resulted in a gradual increase in laser firing frequency from the original 6 kHz to 500 kHz that is used today, for faster and smoother corneal cuts. Different FSL platforms differ in pulse energy and frequency, appplanation surface (flat or curved), laser delivery (raster or spiral pattern), flap cutting time and mobility. The main difference is pulse frequency (kHz versus MHz) and energy ( $\mu\text{J}$  versus nJ).

The FSL's primary application has been as a replacement for the microkeratome in laser-assisted in situ keratomileusis (LASIK), offering increased precision in flap creation [19]. Other applications include corneal intrastromal ring implantation, astigmatic keratotomy, lamellar cutting during corneal transplantation and cataract surgery.

## **Femtolaser Assisted Lenticule Extraction (FLEX) and Small Incision Lenticule Extraction (SMILE)**

With the advent of femtolaser assisted lenticule extraction (FLEX and SMILE) the dream and idea of intrastromal tissue removal is reappraised. At its current state the obvious advantages of the minimal invasive approach and improved biomechanical stability have to be weighted against the limited capacity to treat low amounts of myopia, astigmatism and hyperopia. There is still controversy among the users regarding the best retreatment option for residual refractive errors (intrastromal versus surface).

## **Femtolaser Keratoplasty**

Postoperative outcomes for FS keratoplasty had significant improvement in astigmatism before the 6 month postoperative follow-up and earlier suture removal was possible. However although limited by their methodology in some points, recent reviews comparing FS versus manual mechanically guided penetrating keratoplasty have shown no final differences in terms of astigmatism and visual outcome [20]. Thus, at present, arguments could be raised against using FS laser keratoplasty. Better docking systems with liquid interfaces that do not distort corneal geometry or even contact-free laser cutting might be options to solve the current problems. Improvements in reducing the laser-pulse collateral tissue damage would help in decreasing the endothelial cell damage and the preservation of collagen fibers. The second main drawback of FS laser-assisted corneal trephination is the limited capability for cutting scarred tissue. Unlike LASIK, keratoplasty needs lasers that are operational in the volume of scattering tissue. Clinical experience confirms that cutting scarred tissue, e.g. opacified herpetic corneae, cannot be performed with modern FS-assisted platforms in a non-contact procedure.

For surgery on healthy cornea, the usual wavelengths of 800 nm and 1  $\mu\text{m}$  can be used, while edematous and scarred cornea require specific optimization as suggested by Crotti et al. [21]

## Picosecond Infrared Laser (PIRL) Keratoplasty

Mid-infrared pulses might prove as an effective tool for corneal incisional surgery, such as cornea transplantation [22]. The pulses are tuned to one of the dominant vibrational states of the tissue ( $\lambda = 2.96 \mu\text{m}$ ) with pulse durations that are sufficiently short (300 ps) to deposit heat through ultrafast vibrational relaxation but with intensities small enough to avoid plasma formation. This study is the first report showing that wavelengths in the mid-infrared range centered at 3  $\mu\text{m}$  are efficient for obtaining aplanation-free deep cuts on healthy postmortem cornea. Wound healing and in vivo experiments will be needed to confirm this promising approach.

## Summary

Interestingly there is a steady alternating pendulum from new therapeutic to refractive laser applications throughout the evolutionary process of corneal laser surgery. First excimer PTK was followed by introduction of PRK. Then lamellar refractive surgery (LASIK) was followed by new lamellar therapeutic developments such as therapeutic lamellar transplant procedures for Keratokonus [23] and endothelial failure [24]. And latest small incision lenticular extraction [25, 26] is followed by first studies introducing therapeutic stromal lenticular implantation procedure for corneal thinning disorders [27].

## References

1. Meyer-Schwickerath G. History and development of photocoagulation. *Am J Ophthalmol.* 1967;63(6):1812–4.
2. Meyer-Schwickerath G. Twenty-five years of photocoagulation. *Trans Am Acad Ophthalmol Otolaryngol.* 1973;77(1):OP3–5.
3. Trokel SL, Srinivasan R, Braren B. Excimer laser surgery of the cornea. *Am J Ophthalmol.* 1983;96(6):710–5.
4. Marshall J, Trokel S, Rothery S, Schubert H. An ultrastructural study of corneal incisions induced by an excimer laser at 193 nm. *Ophthalmology.* 1985;92(6):749–58.
5. Marshall J, Trokel S, Rothery S, Krueger RR. A comparative study of corneal incisions induced by diamond and steel knives and two ultraviolet radiations from an excimer laser. *Br J Ophthalmol.* 1986;70(7):482–501.
6. Seiler T, Bende T, Wollensak J, Trokel S. Excimer laser keratectomy for correction of astigmatism. *Am J Ophthalmol.* 1988;105(2):117–24.

7. Reinstein DZ, Archer TJ, Gobbe M. The history of LASIK. *J Refract Surg.* 2012;28(4):291–8.
8. Levin S, Carson CA, Garrett SK, Taylor HR. Prevalence of central islands after excimer laser refractive surgery. *J Cataract Refract Surg.* 1995;21(1):21–6.
9. McAlinden C. Corneal refractive surgery: past to present. *Clin Exp Optom.* 2012;95(4):386–98.
10. Spadea L, Giammaria D, Trabucchi P. Corneal wound healing after laser vision correction. *Br J Ophthalmol.* 2016;100(1):28–33.
11. Reinstein DZ, Silverman RH, Sutton HF, Coleman DJ. Very high-frequency ultrasound corneal analysis identifies anatomic correlates of optical complications of lamellar refractive surgery: anatomic diagnosis in lamellar surgery. *Ophthalmology.* 1999;106(3):474–82.
12. Gartry DS, Kerr Muir MG, Marshall J. Excimer laser photorefractive keratectomy. 18-month follow-up. *Ophthalmology.* 1992;99(8):1209–19.
13. Pallikaris IG, Papatzanaki ME, Stathi EZ, Frenschok O, Georgiadis A. Laser in situ keratomileusis. *Lasers Surg Med.* 1990;10(5):463–8.
14. Ghadhfan F, Al-Rajhi A, Wagoner MD. Laser in situ keratomileusis versus surface ablation: visual outcomes and complications. *J Cataract Refract Surg.* 2007;33(12):2041–8.
15. Hofmeister EM, Bishop FM, Kaupp SE, Schallhorn SC. Randomized dose–response analysis of mitomycin-C to prevent haze after photorefractive keratectomy for high myopia. *J Cataract Refract Surg.* 2013;39(9):1358–65.
16. Guerin MB, Darcy F, O’Connor J, O’Keeffe M. Excimer laser photorefractive keratectomy for low to moderate myopia using a 5.0 mm treatment zone and no transitional zone: 16-year follow-up. *J Cataract Refract Surg.* 2012;38(7):1246–50.
17. Shortt AJ, Allan BD, Evans JR. Laser-assisted in-situ keratomileusis (LASIK) versus photorefractive keratectomy (PRK) for myopia. *Cochrane Database Syst Rev.* 2013;1:CD005135.
18. Niemi MH, Klancnik EG, Bille JF. Plasma-mediated ablation of corneal tissue at 1053 nm using a Nd:YLF oscillator/regenerative amplifier laser. *Lasers Surg Med.* 1991;11(5):426–31.
19. Kasetsuwan N, Satitpitakul V, Puangsrichareon V, Reinprayoon U, Pariyakanok L. Comparison of performances of femtosecond laser and microkeratome for thin-flap laser in situ keratomileusis. *Lasers Surg Med.* 2016;48(6):596–601.
20. Daniel MC, Bohringer D, Maier P, Eberwein P, Birnbaum F, Reinhard T. Comparison of long-term outcomes of femtosecond laser-assisted keratoplasty with conventional keratoplasty. *Cornea.* 2016;35(3):293–8.
21. Crotti C, Deloison F, Alahyane F, Aptel F, Kowalczyk L, Legeais JM, et al. Wavelength optimization in femtosecond laser corneal surgery. *Invest Ophthalmol Vis Sci.* 2013;54(5):3340–9.
22. Linke SJ, Frings A, Ren L, Gomolka A, Schumacher U, Reimer R, et al. A new technology for appplanation free corneal trephination: the picosecond infrared laser (PIRL). *PLoS One.* 2015;10(3):e0120944.
23. Busin M, Arffa RC. Microkeratome-assisted mushroom keratoplasty with minimal endothelial replacement. *Am J Ophthalmol.* 2005;140(1):138–40.
24. Busin M. A new lamellar wound configuration for penetrating keratoplasty surgery. *Arch Ophthalmol.* 2003;121(2):260–5.
25. Sekundo W, Kunert K, Russmann C, Gille A, Bissmann W, Stobrawa G, et al. First efficacy and safety study of femtosecond lenticule extraction for the correction of myopia: six-month results. *J Cataract Refract Surg.* 2008;34(9):1513–20.
26. Blum M, Taubig K, Gruhn C, Sekundo W, Kunert KS. Five-year results of Small Incision Lenticule Extraction (ReLEx SMILE). *Br J ophthalmol.* 2016;100(9):1192–5.
27. Ganesh S, Brar S. Femtosecond intrastromal lenticular implantation combined with accelerated collagen cross-linking for the treatment of keratoconus – initial clinical result in 6 eyes. *Cornea.* 2015;34(10):1331–9.

# Chapter 2

## Standardized Evaluation of Safety, Predictability and Efficacy

Toam R. Katz

### How to Measure a Success?

The target of the refractive surgery may be defined as reaching the best possible visual performance without visual aids. This definition is only part of the truth. When evaluating the success of a cosmetic not medically indicated surgery our target should be to satisfy the subjective expectations of our customer. Such a subjective goal does not necessarily coincide with a visual acuity (VA) of 20/20 or decimally described VA of 1.0. Many social, psychological and cultural factors may influence this vague description of “satisfaction”. Some surgeons base on this principle and set their target as “20/happy” as a paraphrase to the accepted 1.0 or the american term “20/20” VA. That means, as long as the patient is happy with his vision we can take it as a “success”. Quantifying satisfaction may be done through different satisfaction surveys including elaborate questionnaires that the customer is asked to complete in a certain time point after the surgery, or before and after surgery for a better validation. Many studies compared the satisfaction of the patient after their corneal refractive surgery using “quality of Life” questionnaire or “satisfaction outcome”. However small specific myopic or hyperopic groups were analyzed and none of the subjective survey was accepted as standard in refractive surgery, and the known studies are not comparable. Never the less all studies reported a high satisfaction rate among corneal refractive surgery patients.

Even if we ignore the problematic of subjective satisfaction and limit ourselves to visual performances of the operated eye or binocular system, we must remember that measuring the VA alone is subject to changes over time and mental status, and

---

T.R. Katz, MD, PhD  
Department of Ophthalmology, University Medical Center Hamburg Eppendorf,  
Martinistr. 52, Hamburg 20246, Germany

CARE Vision Germany GmbH, Ruesterst. 1, Frankfurt/Main 60325, Germany  
e-mail: [t.katz@uke.de](mailto:t.katz@uke.de)

neglects very important other visual parameters such as night vision, contrast sensitivity, color vision, visual field, depth perception, halos and glare. These non VA parameters demand time demanding examinations and are not standardized in refractive surgery centers. Some of these visual qualities, mainly night vision, contrast sensitivity, halos and glare are related to measureable parameters of high order optical aberrations (HOA) that are discussed later in this book.

## Visual Acuity Parameters

In order to allow clear comparison of refractive surgery results we would use in the following chapters the simplest and most widely measured and analyzed parameter of distance VA.

The VA will be measured in a decimal scale and in logMAR which are the standard in peer reviewed studies. VA of 1.0 decimal is LogMAR 0. The Snellen chart used decimal VA in decimal steps of doubling the visual angle from decimal 0.1 to 0.13, 0.16, 0.20, 0.25 and so on up to 1.0 and above.

Measuring a change in VA may use loss or gain of Snellen chart lines, in which a decrease of VA from 1.25 to 0.8 implies loss of 2 Snellen lines and an increase from 0.32 to 0.63 decimal lines implies a gain of 4 Snellen lines. The complete visual acuity conversion chart compares the decimal and LogMAR VA steps with other traditional VA scales [1].

When we assess the VA of presbyopes one should use accepted terms for VA in distance, intermediate and near targets, with and without visual aids, monocularly and binocularly.

The following visual acuity Terms and abbreviations will be used in this book (Table 2.1):

## Safety and Efficacy Parameters

Based on the VA of the same eye before and after the surgery we can retrospectively define the effectiveness and the safety of the surgery. If the postoperative UDVA equals and even surpasses the preoperative CDVA we can define this as an effective procedure. The efficacy index (EI) is defined as follows:

$$\text{Efficacy index} = \text{post operatively UDVA} / \text{preoperatively CDVA}$$

Hence an EI of 1.0 or better reflects a highly effective surgery.

If the postoperative eye has a low EI it may still reach a better CDVA postoperatively. If unfortunately even the DCVA postoperatively is lower than DCVA preoperatively we say the eye has lost some visual potential and is damaged. Similarly we define the safety index (SI):

**Table 2.1** Visual acuity terms and abbreviations

UDVA	Uncorrected distance visual acuity
UIVA <sup>a</sup>	Uncorrected intermediate visual acuity
UNVA <sup>a</sup>	Uncorrected near visual acuity
Binocular UDVA	Binocular uncorrected distance visual acuity
Binocular UIVA <sup>a</sup>	Binocular uncorrected intermediate visual acuity
Binocular UNVA <sup>a</sup>	Binocular uncorrected near visual acuity
CDVA	Corrected distance visual acuity
CIVA <sup>a</sup>	Corrected intermediate visual acuity
DCIVA <sup>a</sup>	Distance-corrected intermediate visual acuity
CNVA <sup>a</sup>	Corrected near visual acuity
DCNVA	Distance-corrected near visual acuity
Binocular CDVA	Binocular corrected distance visual acuity
Binocular CIVA <sup>a</sup>	Binocular corrected intermediate visual acuity
Binocular DCIVA <sup>a</sup>	Binocular distance-corrected intermediate visual acuity
Binocular CNVA <sup>a</sup>	Binocular corrected near visual acuity
Binocular DCNVA	Binocular distance-corrected near visual acuity

Adapted from Kohnen [4] with permission

<sup>a</sup>Specify distance at which measurement was made

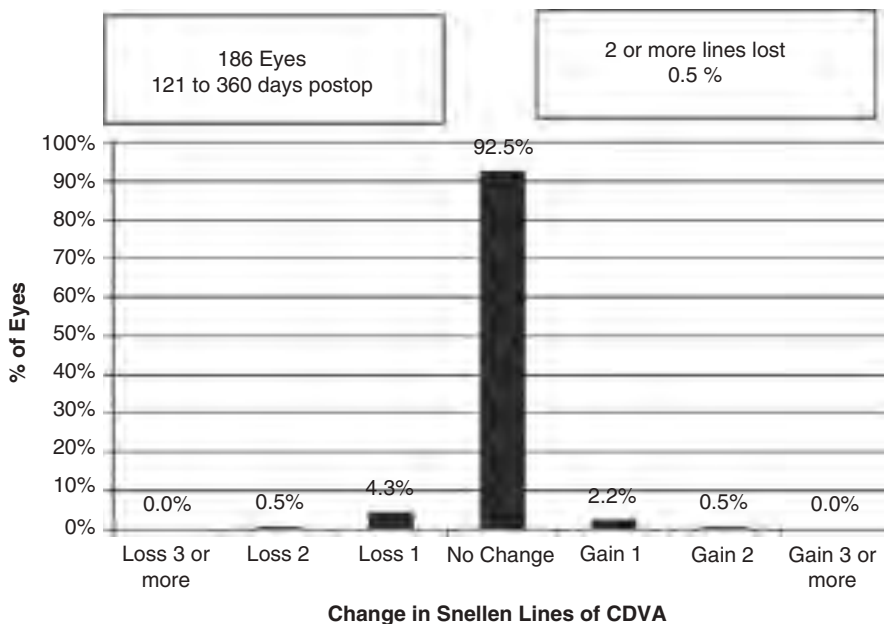
***Safety index = post operatively CDVA/preoperatively CDVA***

The safety and efficacy may also be described as a subtraction of the decimal VA before and after surgery. We may present the percentage of eyes which changed (gained or lost) UDVA and CDVA and group them in Snellen lines of VA or in accumulative VA as presented in the standard graphs [2] in the examples below (Figs. 2.1 and 2.2):

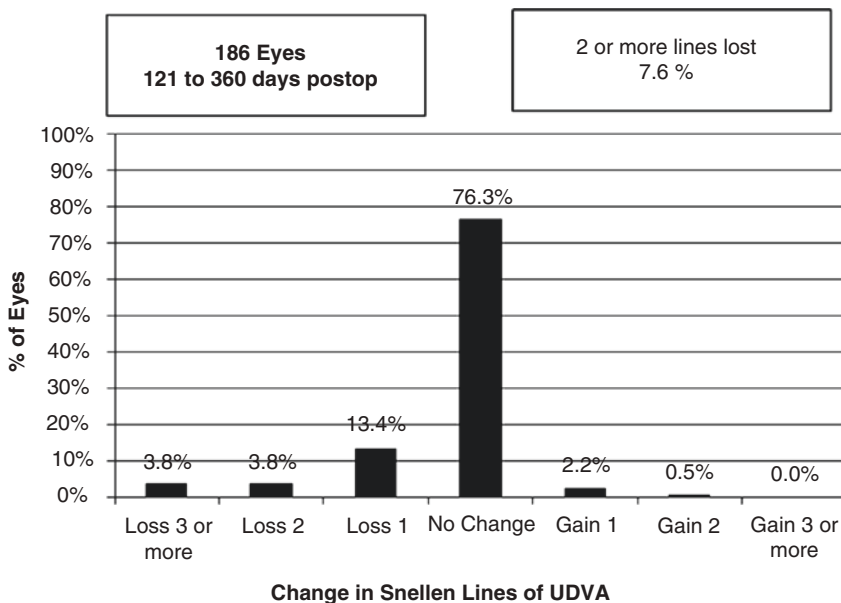
A surgically induced change in CDVA as shown in Fig. 2.1 diagram reflects the safety of the procedure. Comparing the preoperative CDVA to the postoperative UDVA as shown in Fig. 2.2 reflects the efficacy.

**The Predictability of the Dioptric Change**

Another set of parameters that we wish to change as safe and as effective as possible is the refraction parameters. We are using Diopter (D) to measure the sphere and cylinder magnitude and degrees of angles to measure the axis of the cylinder. The manual refraction, as accurate as it may be, still uses a low resolution of up to 0.25 D and axis of 1°. Although our automated measuring and laser devices can reach a much higher resolution we still traditionally use steps of 0.25 D to analyze our results.



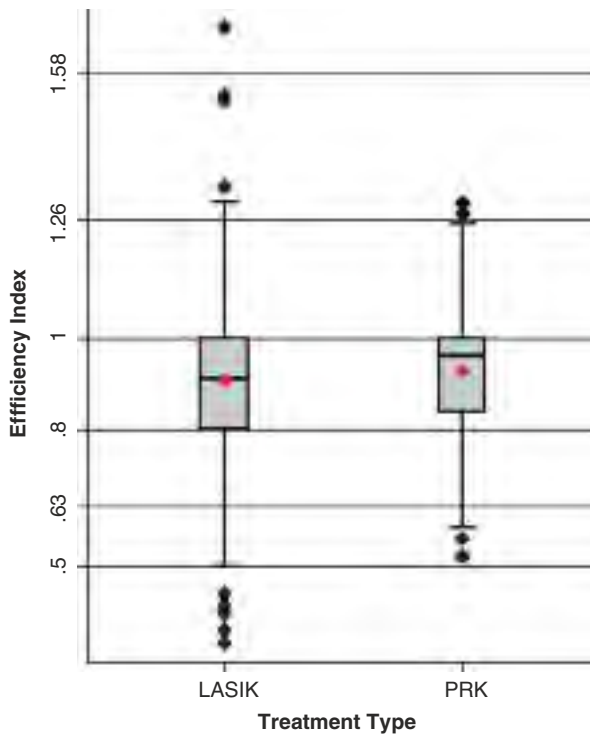
**Fig. 2.1** An example of percent of eyes which gained or lost Snellen lines of CDVA post operative compared to preoperative DCVA (Safety gain of lines)



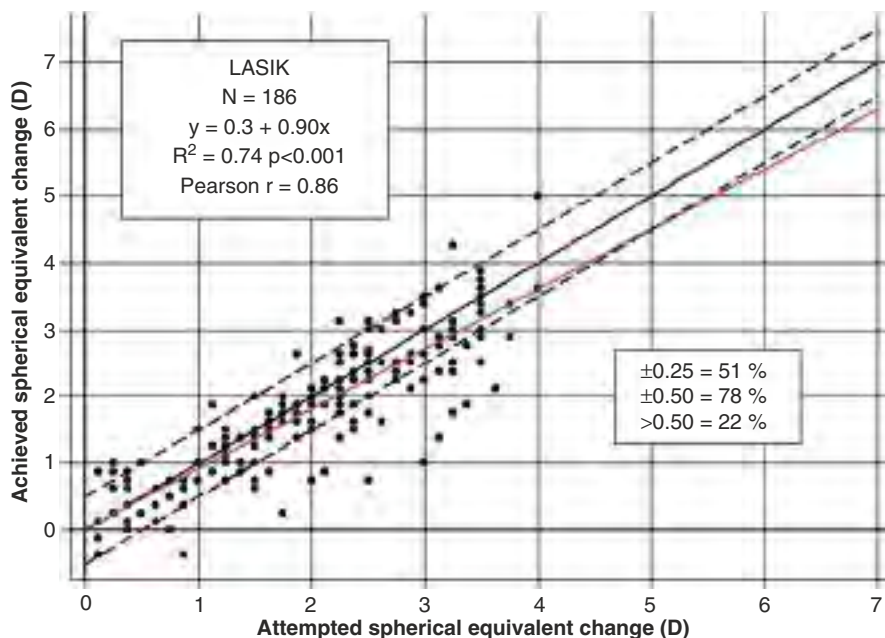
**Fig. 2.2** An example of percent of eyes which gained or lost Snellen lines of post operative UCVA compared to preoperative DCVA (Efficacy gain of lines)



The predictability of the refractive surgery compares the targeted change in sphere, cylinder and axis with the achieved changes. A very crude but easy to use refractive parameter is the spherical equivalent (SE).  $SE = (\text{sphere}) + 1/2 (\text{cylinder})$  and correlated to the mean targeted or achieved flattening or steepening of the corneal surface. By correcting myopia we aim to flatten the central cornea. Too much flattening would cause overcorrection and too less flattening causes under correction of the myopia. By hyperopic correction conversely we aim to steepen the cornea. Too flat cornea would be an undercorrected hyperopic refractive result. A perfect predictability means that 100% of the treated eyes have reached a point landing after some defined healing time and stayed in this form and refraction, commonly emmetropia, over the longer post operative period. When we assess the predictability of SE or sphere change a deviation of up to 0.25 D from target is considered a good accuracy, and a deviation of up to 0.5 D from target is still acceptable. Clinically speaking it is well known that correcting high myopias and high hyperopy suffer from lower predictability and lower stability of the refractive result over time. Figures 2.3 and 2.4 demonstrate the predictability as attempted SE versus achieved SE and assuming the target refraction was emmetropia we see in the right diagram which percentage reached the zero SE postoperatively.



**Fig. 2.3** An example of comparing the Efficacy Index (EI) of LASIK vs. PRK using a Tukey box plot. The grey box describes the interquartile range (IQR) including 1st, 2nd and 3rd quartiles, the horizontal line is the median and the red square is the mean. The whiskers are  $Q1 - 1.5 \times IQR$  and  $Q3 + 1.5 \times IQR$ . The black squares describe the outliers



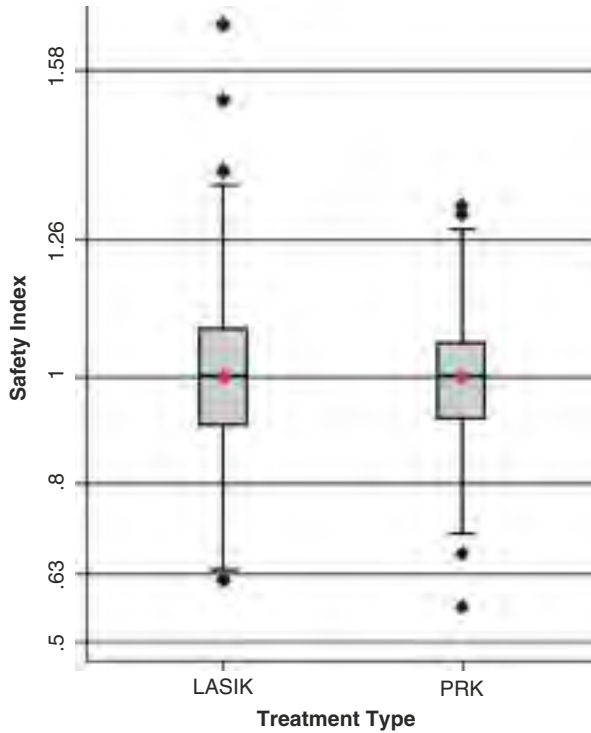
**Fig. 2.4** Example for presentation of the predictability of spherical equivalent after LASIK. The black line represent the perfect predictability, the dotted lines a bias of 0.5 D (78%). The area below the black line is undercorrected, above is over corrected. The red line is regression line with a constant of 0.3 D and slope of 0.9

The predictability of the refraction over time reflects the stability of the results. Here again we see in this example the stability of the SE and not the separate sphere or cylinder (Figs. 2.5, 2.6 and 2.7):

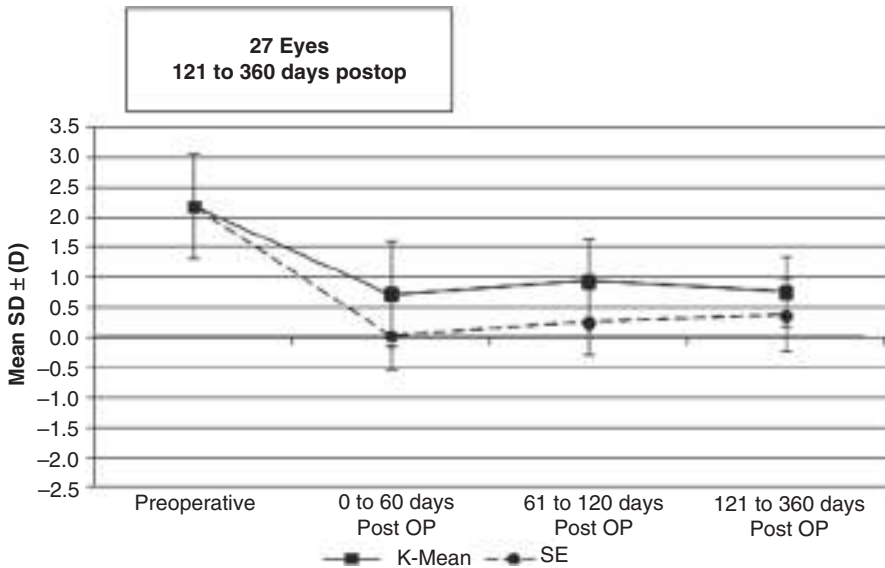
## Predictability of the cylindric correction

The SE is per definition a rough refractive parameter. If instead of plano refraction we reached a post operative refraction of S  $-0.25$ , C  $+0.50$ , A  $120^\circ$  or S  $-2.0$  C  $+4.0$  A  $16^\circ$  they would both have a SE of 0 D and would appear in the diagrams above as a predictable successful surgery.

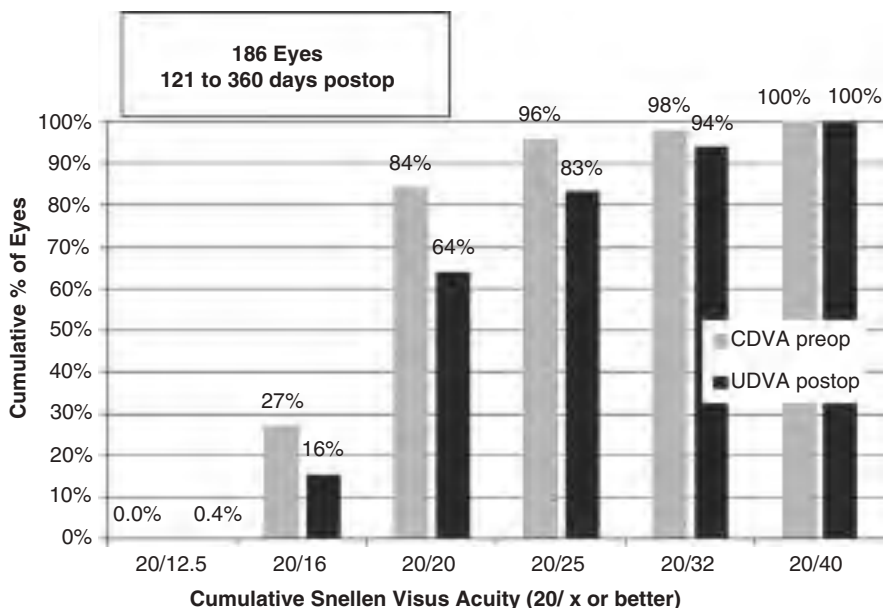
The predictability of the cylindric correction demands different tools. We may calculate the predictability of the cylindric magnitude in D as we did with sphere or SE results. This is of course only half of the picture since we did not include the axis. Analyzing the cylindrical magnitude and axis uses vectorial tools and indexes which measure how much of the desired magnitude change was done on axis. Too much magnitude change on the correct axis means cylindrical overcorrection but too much magnitude change on the vertical axis will cause under correction of the cylinder. Since vectorial algebra uses  $360^\circ$  cycle but refractive values use only  $180^\circ$  cycle a method of double angle vectorial analysis was developed by Alpíns, we recommend to use double angle vector analysis together with a set of efficacy and



**Fig. 2.5** An example of Tukey Boxplot of safety index in LASIK vs. PRK. The mean and median SI for both treatments is 1.0



**Fig. 2.6** An example of stability of mean keratometry and spherical equivalent pre operative and 360 days post operatively after hyperopic LASIK



**Fig. 2.7** An example of cumulative visual acuity corrected pre operatively and uncorrected post operatively measured in feet ratio. 20/20 is equivalent to 1.0 decimal scale and 0 in LogMAR scale

predictability parameters for the cylindrical correction of refractive surgery [3]. The target induced astigmatism (TIA) and the actual surgically induced astigmatism (SIA) were used to calculate the deviation vector (DV) which is the counterpart of under or over correction in spherical diopters.

## Safety, Efficacy and Predictability of Complicated Refractive Surgeries

This book deals with a variety of complications and their prevention and management. Naturally we discuss rare cases and can not present large cohorts or compare subgroups accurately. The refractive data is often inaccurate when we describe irregular astigmatism or refract a scarred cornea. We would use the common VA based safety and efficacy indexes and Snellen lines change as well as descriptive parameters to analyze the success of complications management.

## References

1. Holladay JT. Visual acuity measurements. *J Cataract Refract Surg.* 2004;30:287–90.
2. Waring GO. Standard graphs for reporting refractive surgery. *J Cataract Refract Surg.* 2000;16:459–66.
3. Alpins N. A new method of analyzing vectors for changes in astigmatism. *J Cataract Refract Surg.* 1993;19:524–33.
4. Kohnen T. New abbreviations for visual acuity values. *J Cataract Refract Surg.* 2009;35:1145.

# Chapter 3

## Safety, Predictability and Efficacy of LASIK

**Toam R. Katz**

LASIK is being used worldwide due to its well known low complication rate and high accuracy in correcting refractive errors. The rarity of the complications and their successful management discussed in this book contribute to the high acceptance of Excimer laser surgery in previously healthy corneas. As in many popular surgical techniques the database accumulated over 25 years helped to improve the results of LASIK with such as two main strategies: first by gradually introducing new techniques of flap making, better eye-trackers, faster FSL and accurate sub-Bowmann microkeratom (MK), and secondly by learning the limits of LASIK in certain refractions and populations hence avoiding high risk treatments. An excellent example is the newly developed technique of “Small Incision Lenticule Extraction” (SMILE) presented separately in this book.

In order to understand the impact of the complications presented in this book one must understand what to expect from a non complicated LASIK. The safety, efficacy and predictability are shortly presented with the standardized tools discussed in the chapter “standardized evaluation of safety predictability and efficacy”.

The LASIK industry is heavily supported and changed by the success of FSL-LASIK and MK-LASIK over the last 25 years. The technical progress allowed better results than 10 years ago in both modern methods. The updated literature since 2010, shortly summarized below, shows similar efficacy, safety and predictability in all Excimer platforms of all manufacturers. The truly most influencing factor on LASIK results is not the laser platform or flap making but rather the different refraction groups. In addition other preoperative conditions such as age, dry eye, patient’s expectation do also influence the postoperative outcome.

---

T.R. Katz, MD, PhD  
Department of Ophthalmology, University Medical Center Hamburg Eppendorf,  
Martinistr. 52, Hamburg 20246, Germany

CARE Vision Germany GmbH, Ruesterst. 1, Frankfurt/Main 60325, Germany  
e-mail: [t.katz@uke.de](mailto:t.katz@uke.de)

© Springer International Publishing Switzerland 2016  
S.J. Linke, T. Katz (eds.), *Complications in Corneal Laser Surgery*,  
DOI 10.1007/978-3-319-41496-6\_3

19

LASIK is most predictable and safer in low myopia and less predictable and less safe in very high myopia and hyperopia. LASIK results are described in relation to their refraction groups.

## Results of LASIK for Low and High Myopia with Astigmatism

Myopia may be classified by its manifest refractive spherical equivalent (MRSE) as low (0-3 D), moderate (3,01-6 D), high (6.01-9D) and very high (>9D). A higher myopia correction consumes more stromal tissue, induces more HOA and tends to lower predictability in short term and more long term regression than lower myopic correction. In a case series [1] of 1280 myopic astigmatic eyes going through a FSL-LASIK none had an adverse effect. The overall early post operative results of myopic LASIK were very good. The EI in low, moderate, high and very high myopia were 1.04; 1.03; 0.97 and 0.96 respectively and the SI ranged between 1.07 and 1.04 in all four groups. Loss of 2 safety lines was seen only in high myopia (1.0 %) and very high myopia (2.3 %). These results are similar to other Excimers with scanning spots or variable spot size and high repetition rates. FSL-LASIK for high myopia with a 500 Hz Excimer produced similar results [2] with only 1/52 eyes losing 1 safety line. Predictability of 0.5 D was achieved in 84.3 %. A MK-LASIK for low to high myopic astigmatism achieved 0.5D predictability in 96 % of the 356 eyes and none lost 2 safety lines [3]. A review from 2012 with meta analysis [4] of 15 articles describing a total of 3679 myopic eyes comparing between MK-LASIK and FSL-LASIK showed no significant difference in safety (loss of 2 lines) and efficacy (patient achieving UDVA of 1.0 or better,) and predictability of MRSE.

## Result of LASIK in Correcting Astigmatism

In order to correct astigmatism we should achieve not only precise ablation but also precise axis of ablation. This may be prone to cyclotorsion and to interaction between the sphere and the cylindrical ablation components. The higher the corrected cylinder the greater the error caused by smaller cyclotorsion. The modern platforms [5] correct the cyclotorsion or follow it with iris- or limbal-based eye tracking with an accuracy of 1.5°.

Correction of very low astigmatism is not problem free. Changes of 0.25 D post operatively may happen non symmetrically as a consequence of minute variations in corneal healing, causing over correction of the very low cylinder [6]. The astigmatism is produced mainly by the anterior corneal surface. The astigmatism arising from posterior cornea and intraocular structures (ocular residual astigmatism, ORA) may reduce the efficacy of Excimer ablation performed in the corneal stroma [7].

Apart from the ablation pattern the flap itself with a superior or nasal hinge may influence the astigmatism post operatively [8].

The efficacy of astigmatic correction can not be analyzed with SE but rather should be done using vectorial parameters. The results FSL-LASIK of 46 myopic and 52 hyperopic eyes all with astigmatism of 2 D or more showed an undercorrection of 28 % of the astigmatism and particularly in hyperopic astigmatism [9].

## Results of LASIK for Hyperopia

The correction of Hyperopia with LASIK is prone to two major disadvantages: the resultant steep conus reduces the CDVA and visual quality, and the post operative cornea tends to regression over time causing under correction. In very long term follow-up of large populations (blue mountain eye study, beaver dam eye study) of normal 30 year olds or older we see a hyperopic progression over the years. These problems are more common in higher hyperopic correction, which led to the recommendation of no more than 3–4 D as upper limit for hyperopic LASIK [10], compared to 8 D in myopic LASIK. In a recent 3-year follow-up of 86 hyperopic LASIK eyes the EI was 0.94 and 0.5D predictability was 70 %. Regression of more than 0.5 D in 3 years was observed in 36 % of the eyes and 5/86 eyes lost one or more safety lines [11]. Twenty nine percent needed a retreatment during the follow-up period.

As a rule of thumb we may consider the LASIK procedure as very predictable if done within the safety range. The option of retreatment in case of low predictability is technically and medically as simple as the first treatment. The 0.5D predictability of modern LASIK is in the range of 97 %.

## References

1. Tomita W, Yukawa N, Nakamura M. Safety, efficacy, and predictability of laser in situ keratomileusis to correct myopia or myopic astigmatism with a 750 Hz scanning-spot laser system. *J Cataract Refract Surg.* 2014;40:251–8.
2. Alio JL, Vega-Estrada A, Pinero DP. Laser-assisted in situ keratomileusis in high levels of myopia with the Amaris Excimer laser using optimized aspherical profiles. *Am J Ophthalmol.* 2011;152:954–63.
3. Arbelaez MC, Aslanides IM, Barraquer C, Carones F, Feuermannova A, Neuhann T, Rozsival P. LASIK for myopia and astigmatism using the Schwind Amaris excimer laser: an international multicenter trial. *J Refract Surg.* 2010;26:88–98.
4. Chen S, Feng Y, Stojanovic A, Jankov MR, Wang Q. IntraLase femtosecond laser vs mechanical microkeratomes in LASIK for myopia: a systematic review and metaanalysis. *J Refract Surg.* 2012;28(1):15–24.
5. Mosquera V. Effects of torsional movements in refractive procedures. *J Cataract Refract Surg.* 2015;41:1752–66.
6. Frings A, Katz T, Richard G, Druchkiv V, Linke SJ. Efficacy and predictability of laser in situ keratomileusis for low astigmatism of 0.75 diopter or less. *J Cataract Refract Surg.* 2013;39(3):366–77.

7. Frings A, Richard G, Steinberg J, Skevas C, Druchkiv V, Katz T, Linke SJ. LASIK for spherical refractive myopia: effect of topographic astigmatism (ocular residual astigmatism, ORA) on refractive outcome. *PLoS One*. 2015;15:10(4).
8. Katz T, Frings A, Richard G, Steinberg J, Druchkiv V, Linke SJ. Flap-induced astigmatism in eyes with sphere myopia correction: superior hinge using a rotating microkeratome versus nasal hinge using a linear microkeratome. *J Cataract Refract Surg*. 2015;41(6):1160–7.
9. Ivarsen N, Hjortdal, laser in situ keratomileusis for high astigmatism in myopic and hyperopic eyes. *J Cataract Refract Surg*. 2013;39:74–80.
10. <http://aad.to/krc/qualit.pdf> (German language).
11. Plaza-Puche AB, Pilar Y, Samuel A-M, Alió JL. Three-year follow-up of hyperopic LASIK using a 500-Hz excimer laser system. *J Refract Surg*. 2015;31(10):674–81.



# Chapter 4

## Safety, Efficacy and Predictability of SAT

Toam R. Katz

### Modern PRK

The surface ablation techniques have different names and origins. The most widely used method today includes the following steps: loosening and removing the epithelium with alcohol 20% solution, thus exposing the Bowman layer, aiming the Excimer laser ablating through the Bowman and stroma, and applying MMC 0.02% for a predefined time to prevent scarring. Some surgeons use MMC only for deeper ablations and some use it routinely. The peeled off epithelium is discarded (epithelium off technique) and the cornea is protected with a contact lens and local therapy. This method was described in the literature as PRK, LASEK, or Surface Ablation Technique (SAT). To simplify the discussion we will use the broadly used term PRK for these procedure. Other variations of removing the epithelium by automated separator similar to MK (Epi-K, Epi-LASIK) or ablating the epithelium (transepithelial PRK, PTK) did not show a clear advantage over PRK are used rarely as standard SAT. This book evaluates the results of the currently modern refractive surgery techniques and does not present the older history. The older PRK result suffered from low safety because of stromal Haze and optical aberrations using an optical zones of 5 mm or less, and low efficacy because of common regression. The modern PRK uses large optical zones of typically 6.5 mm or larger and MMC to prevent haze and regression.

This book focuses on the complications of corneal refractive surgery, including those of PRK. The indication for PRK, mainly saving on corneal tissue and avoiding short term and long term complications of the flap creation will not be discussed

---

T.R. Katz, MD, PhD  
Department of Ophthalmology, University Medical Center Hamburg Eppendorf,  
Martinistr. 52, 20246 Hamburg, Germany

CARE Vision Germany GmbH, Ruesterst. 1, 60325 Frankfurt/Main, Germany  
e-mail: [t.katz@uke.de](mailto:t.katz@uke.de)

here. In order to understand the impact of the complications presented in this book one must understand what to expect from a non complicated modern PRK. The safety, efficacy and predictability are shortly presented with the standardized tools discussed in the chapter “standardized evaluation of safety predictability and efficacy”.

The candidates for PRK are usually deferred from LASIK because of lower pachymetry, more irregular topographies as far as ectasia risk concerns, and higher myopic correction target in comparison to LASIK indicated eyes. One may expect that this bias will lead to a lower efficacy and safety compared to LASIK. Considering the steps of the procedures, the Excimer refractive ablation itself is identical for LASIK and PRK so differences in efficacy and safety should only depend on flap healing in LASIK vs. stromal and epithelial healing in PRK. In fact, the efficacy of a MMC assisted non complicated PRK is not different than of a non complicated LASIK. It depends mainly on the attempted refraction correction. Both methods are more predictable in low and moderate myopias, and less predictable in higher myopias, high astigmatism and Hyperopia.

The safety and efficacy of PRK will be presented in Hyperopia and myopia separately

## **PRK for Hyperopic and Hyperopic Astigmatism Correction**

The very few studies describing modern PRK, i.e. with fast eye trackers, large optical zone of 6.5 mm or more, modern ablation profiles and use of MMC report excellent safety and high accuracy in correcting Hyperopia. The typical over correction initially resolves in a few weeks and the long term results show stability and good predictability after more than 6 months. Haze occurs rarely and differently than by myopic PRK the hyperopic haze does not involve the visual axis. It may induce regression and astigmatism but does not reduce the DCVA. Several hyperopic PRK studies are summarized below.

In a prospective study [1] analyzing 28 eyes of 14 patients with preoperative manifest SE of  $+2.71 \pm 0.72$  D (range: +1.50 to +4.50 D) all eyes underwent LASEK with an Aberration-Free algorithm followed by a 35-second application of MMC with a 6.7-mm optical zone size. At 1 year, mean manifest SE was  $0.03 \pm 0.30$  D (range:  $-0.53$  to  $+0.50$  D), with 13 eyes within  $-0.13$  to  $+0.13$  D and all 28 eyes within  $\pm 0.50$  D. Mean UCVA was  $-0.03 \pm 0.09$  logMAR, and the efficacy and safety indices were 1, respectively, at 1 year. The postoperative manifest SE was stable between 1 and 3 months and 1 year.

A variation of PRK was analyzed in another study [2] included 70 eyes of 47 patients with Hyperopia (SE 0 to 5 D) with 7 mm optical zone. They were treated with LASEK and the epithelial layer was repositioned on the ablated stromal bed (Epithelial flap on technique). At 12 months, the SE was  $+0.09$  D (range:  $-0.75$  to  $+1.00$  D) with all eyes within  $\pm 1.00$  D of the intended correction and 60 (86%) eyes within  $\pm 0.50$  D. In 40 eyes with 24-month follow-up, the refractive correction

remained stable after 6 months. 11 % had haze after 12 months. The safety index was 1.06 with an efficacy index of 0.95. Analysis of higher order wavefront aberrations showed no significant changes in root-mean-square values postoperatively, except for a significant reduction of fourth order spherical aberration ( $P < .05$ ).

Another PRK surgical variation in which the epithelial layer was not mechanically removed but ablated followed by the refractive ablation (one step transepithelial PRK) using the Amaris 500 Hz excimer was recently analyzed [3]. In this modification, an ablation depth based on a population-based profile of the epithelium thickness was used to adjust the energy delivered to the central (50  $\mu\text{m}$ ) and peripheral cornea (65  $\mu\text{m}$ ), resulting in even epithelium removal. The treatments were done in Germany or in Iran without Alcohol, with optical zone of 6.8–7.6 mm and with MMC application for 5–30 s. The study included 55 Eyes of 31 patients with manifest SE of  $+2.56 \pm 0.19$  D ( $+0.5$  to  $+6.0$  D) with up to 3 D of astigmatism. A typical temporary over correction in the first month was noted. Regression was about 1 D in the first 6 months but stabilized later. The mean rate of regression between months 6 and 12 was only 0.004 D per month. The efficacy and safety of the Iranian eyes after 12 months was better than of the German eyes with  $\pm 0.5$  D predictability of 100 % and 64 % respectively and  $\pm 1$  D predictability of 100 % and 79 % respectively. None of the eyes lost more than 1 line of DCVA after 12 months. The manifest refraction in Iran and in Germany was  $0 \pm 0.06$  and  $0.08 \pm 0.16$  respectively (LogMAR). UDVA of 0.1 LogMAR or better after 1 year was achieved in 100 % of Iranian eyes and 46 % of German eyes. As expected the Hyperopia  $> 3$ D tended to more to regression and under correction after 1 year compared to lower hyperopic correction.

## PRK for Myopic and Myopic Astigmatism Correction

PRK proved to produce very stable keratometry and good efficacy over time. The few studies describing low predictability of PRK after very long time follow-up of more than 10 years reflect the disadvantages of the early PRK techniques, mainly regression and should be regarded as old reference. In contrast we present the better predictability and efficacy in the modern publications:

Corneas thinner than 500  $\mu$  are often indicated to PRK. In 10-year follow-up [4] of 75 myopic eyes ( $-2$  to  $-14$  D SE) with minimal thickness of 438 to 499  $\mu\text{m}$  a slow myopic regression was seen, although with improvement of UDVA, stable keratometry and no ectasia. Safety index was always greater than 0.9 and improved continuously, probably by diminishing haze. Efficacy index remained stable around 0.8. After 10 years 40 % were within  $\pm 0.5$  D and 57 % within  $\pm 1.0$  D from emmetropia. 40 % needed retreatment.

A retrospective analysis [5] from 2010 of 42 eyes of 29 myopic eyes after a single PRK, (32 % of the eyes that got retreatments were excluded) for moderate, high and extreme high myopic astigmatism ( $-2.25$  to  $-14.125$  D SE) with trans epithelial ablation, 6 mm optical zone and without MMC demonstrated after 10 years a mean

myopic regression of  $0.51 \pm 1.78$  D, minimal haze and no loss of more than 1 line DCVA. 17/42 eyes had UDVA of 1.0 or better, and 35/42 eyes had UDVA of 0.5 or better. DCVA was same or improved in 95 % of eyes. This study did report a slightly higher rate of endothelial cell loss (8.3 % in 10 years) than age related.

Differently than hyperopic correction, the results of myopic PRK stabilize earlier and are less prone to regression, although a central haze may reduce the safety index. The variations in technique do not seem to have advantages over each other.

A recent prospective case control study [6] compared the results of correcting myopic astigmatism (SE  $-1$  to  $-9.5$  D) in 173 eyes of 93 patients who underwent trans epithelial PRK (tPRK) compared with 103 eyes of 55 patients who underwent the standard alcohol assisted PRK (aaPRK). All eyes were lasered with a modern laser (Schwind Amaris) and MMC was applied for 2 min. After 3 months both methods reached non significantly different results: UDVA of LogMAR 0 or better was 97–94 %, loss of 1 line DCVA in 13 and 21 %, and gain of 1–2 lines DCVA in 30 and 31 %. Post operative SE at 3 months was  $-0.14 \pm 0.26$  D in the tPRK group and  $-0.12 \pm 0.20$  D in the aaPRK group.

Low level of haze was seen on the slit lamp in 14 % and 9 % respectively. This complication and others did not differ significantly between tPRK and aaPRK.

## **Efficacy of LASIK and PRK Compared**

The disadvantages of early LASIK, mainly ectasia, and early PRK, mainly scarring, effects the reputation of the Excimer ablation corneal refractive surgery even now. Both methods have improved their safety and efficacy and are indicated today side by side. The indication is mainly effected by desire to benefit the fast recovery after LASIK on one hand, versus the need to save stromal tissue in deep ablations and avoid the risks of flap making on the other. Which method is more predictable and which is safer on the long term?

### ***Hyperopia and Hyperopic Astigmatism Correction in PRK Versus LASIK***

Unfortunately there are no randomized controlled studies comparing LASIK and PRK in correcting hyperopia. Only five non randomized studies were published between 2000 and 2012. As expected all comparisons present the painful, slower visual rehabilitation in the first weeks after PRK compared to LASIK. The long term efficacy and safety results however are similar in both methods.

In a prospective comparison of Hyperopia correction of 200 PRK eyes versus 186 LASIK eyes with 2 years follow-up [7] both methods led to loss of 2 lines of corrected vision in 1 % of the eyes. Complications appears in 4.5 % of PRK eyes and 1.6 % of LASIK eyes. This study from 1999 may reflect the disadvantages of

non-modern PRK. A later comparison [8] from 2003 also showed similar safety and efficacy for hyperopic and hyperopic astigmatic 41 PRK and 24 LASIK eyes (sphere +1 to +6 D, Cylinder +0.5 to +4 D). In the short term PRK eyes suffered of mild haze in 19.5% and over correction (temporary myopia). None of the LASIK or PRK eyes lost more than two lines of DCVA. As the refractive result is caused by the changes in corneal topography a hyperopic sphere PRK or LASIK should not induce topographic astigmatism. An irregular astigmatism may reduce the DCVA post-operatively. A cohort study [9] included 36 eyes of 18 patients with sphere Hyperopia between +1 and +4 D. Each patient had PRK without MMC in the first eyes and 3 months later LASIK in the fellow eye. The purely sphere ablation of 6.5 mm optical zone was done with a masking disc with 10 Hz pulses which is less accurate than the modern ablation profiles used today. The induced irregular topographic astigmatism after 1 year was higher than pre-operatively and similar in both PRK and LASIK.

The “wave front optimized” ablation is aimed at correcting the low order aberrations without inducing HOA. This wavelight-optimized method is widely used by our group. When we compared [10] our own hyperopic 186 LASIK eyes and 78 PRK eyes (1 eye per patient randomly selected) the results 4–12 months post operatively were similar. Mean EI was  $0.91 \pm 0.20$  for LASIK and  $0.93 \pm 0.16$  for PRK. The SI was  $1.00 \pm 0.14$  and  $1.0 \pm 0.13$  respectively. Post operative UDVA was  $0.06 \pm 0.12$  and  $0.04 \pm 0.09$  LogMAR respectively. The 0.5D predictability was 78% of LASIK eyes and 77% of PRK eyes. (Diagrams 4.1 and 4.2). In both LASIK and

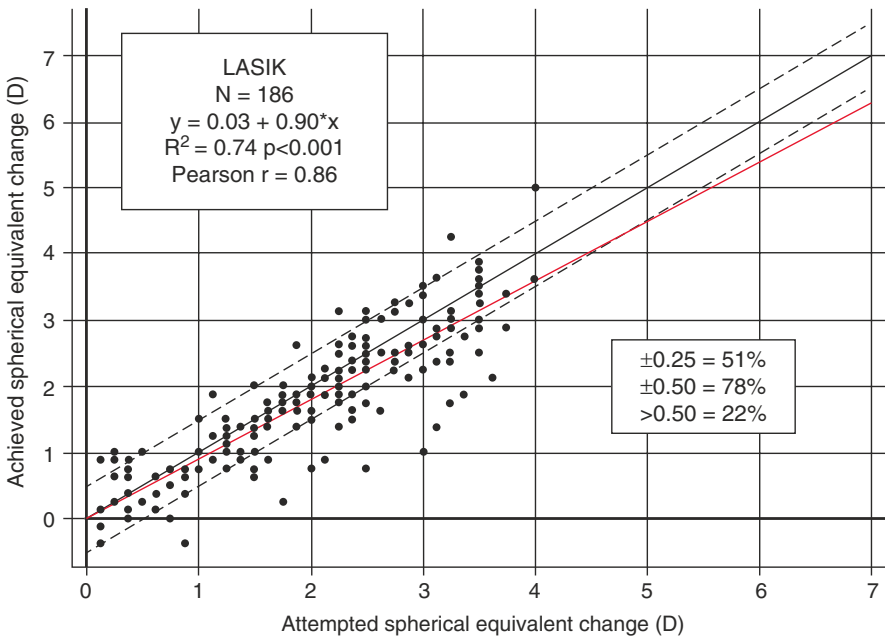
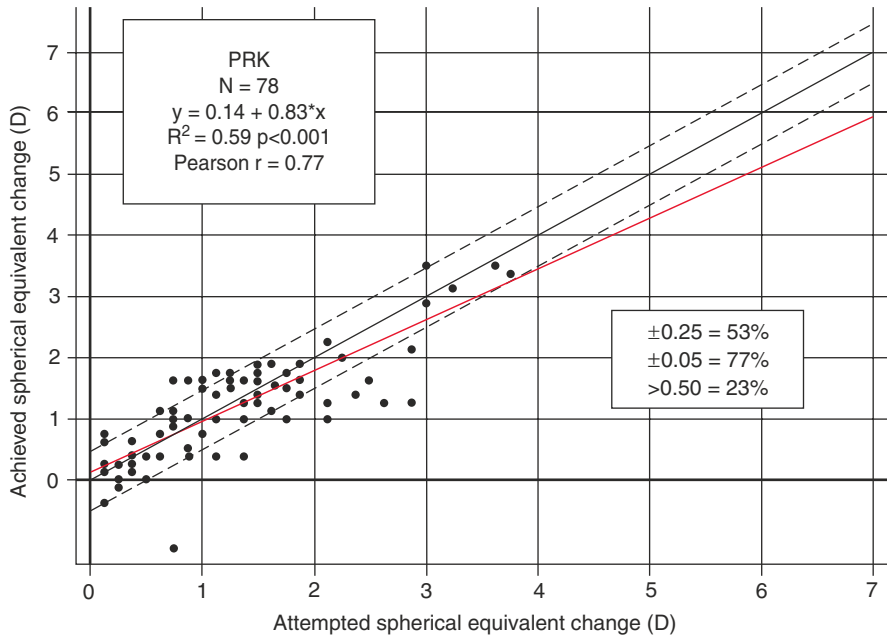


Diagram 4.1 Predictability of hyperopic LASIK



**Diagram 4.2** Predictability of hyperopic PRK

PRK the predictability is better in low hyperopias and regression is higher the higher the attempted correction.

### ***Myopic and Myopic Astigmatism Correction with PRK Versus LASIK***

In a randomized study [11] from 2012 of 45 myopic eyes (−6 to −8 D SE) 20 randomly selected eyes were treated with PRK without MMC and 25 eyes with LASIK and mechanical 130 μm thick flap and the same ablation plan for both methods. After 7 years 9 PRK eyes and 7 LASIK eyes were available for follow-up. While the PRK eyes had stable keratometries after the first year, the LASIK eyes had continuously increase of corneal power. The coma and spherical aberrations increased in all treated eyes in 4 mm and 6 mm pupils. The refractive result showed non-significant myopisation in both methods after 7 years.

PRK does have a small advantage inducing less high order aberrations than LASIK using the same myopic ablation profile, indicating that the aberrations may be induced by LASIK-Flap. The myopic ablation produces spherical aberrations and coma thus increasing the total HOA compared to pre operatively. In a study [12] comparing 65 eyes of 36 LASIK patients and 50 eyes of 28 PRK patients 3 months after myopic correction the root mean square (RMS) of total HOA was raised

significantly more ( $P=.03$ ) after LASIK (1.46-factor increase) than LASEK (1.25-factor increase). One year after surgery, a reduction in total HOAs was observed in 13.8 % of LASIK- and 48.5 % of LASEK-treated eyes compared with preoperative levels. As in other studies the efficacy and safety of LASIK and LASEK after 1 year did not differ significantly.

A randomized LASIK vs. PRK study [13] in which one eye of 42 myopic patients was randomly indicated for PRK and the fellow eyes was treated with LASIK did show an advantage to PRK over LASIK after 1 year. MMC-PRK eyes achieved better uncorrected visual acuity ( $p=0.03$ ) and better best-spectacle-corrected visual acuity ( $p<0.001$ ) 1 year after surgery. SE did not differ in the two groups during follow-up ( $p=0.12$ ). Clinically significant haze was not found in surface ablation eyes. LASIK eyes showed a greater higher-order aberration ( $p=0.01$ ) and lower contrast sensitivity ( $p<0.05$ ) than MMC-PRK eyes postoperatively.

A cohort study [14] compared “wave front optimized” ablation in 34 myopic patients, each treated with PRK in 1 eye and with LASIK in the fellow eye using wave front optimized ablation profile. LASIK and PRK results were compared. As expected at 1 months LASIK had better efficacy and safety than PRK. Later on the modern PRK caught up with LASIK and the differences have resolved giving no significant advantage to either: At 1 year, 91 % of eyes were within  $\pm 0.50$  D and 97 % were within  $\pm 1.0$  D in the PRK group. At 1 year, 88 % of eyes were within  $\pm 0.50$  D and 97 % were within  $\pm 1.0$  D in the LASIK group. At 1 year, 97 % of eyes in the PRK group and 94 % of eyes in the LASIK group achieved an UCVA of 20/20 or better ( $P=0.72$ ).

## Summary

In summery PRK has similar predictability efficacy and safety as LASIK in the different refractive groups. PRK has a slight advantage in long term stability and induces less HOAs compared to LASIK.

Hence indicating LASIK or PRK should depend on the individual risk factors of the patient and on desired healing time, but not on the efficacy of both methods.

## References

1. Mc Alinden C, Skiadaresi E, Moore JE. Hyperopic LASEK treatments with mitomycin C using the SCWIND AMARIS. *J Refract Surg.* 2011;27:380–3.
2. Mellington F, Jones S, Marshall J. Laser epithelial keratomileusis for the correction of hyperopia using a 7.0-mm optical zone with the schwind ESIRIS laser. *J Refract Surg.* 2007;23:343–54.
3. Moghaddam S, Arba-Mosquera S, Walter-Fincke R, Jahi S, Adili-Aghdam F. Transepithelial photorefractive keratectomy for hyperopia: a 12-month bicentral study. *J Refract Surg.* 2016;32(3):172–80.

4. De Benito-Llopis L, Alió JL, Ortiz D, Teus MA, Artola A. Ten-year follow-up of excimer laser surface ablation for myopia in thin corneas. *Am J Ophthalmol.* 2009;147:768–73.
5. Koshimizu J, Dhanuka R, Yamaguchi T. Ten-year follow-up of PRK for myopia. *Graefes Arch Clin Exp Ophthalmol.* 2010;248:1817–25.
6. Kaluzny BJ, Cieslinska I, Mosquera S, Verma S. Single-step transepithelial PRK vs alcohol-assisted PRK in myopia and compound myopic astigmatism correction. *Medicine (Baltimore).* 2016;95(6):e1993.
7. Stein RM. Comparison between hyperopic PRK and hyperopic LASIK with the VISX STAR excimer laser system. *Am Acad Ophthalmol.* 1999:246.
8. El-Agha MS, Bowmann RW, Cavanagh HD, McCully JP. Comparison of PRK and LASIK for the treatment of compound hyperopic astigmatism. *J Cataract Refract Surg.* 2003;29:900–7.
9. Scisio A, Hull CC, Baldwin H, O’Bratt D, Marshall J. Fourier analysis of induced irregular astigmatism. PRK Vs. LASIK in bilateral cohort of hyperopic patients. *J Cataract Refract Surg.* 2003;29(9):1709–17.
10. Frings A, Katz T. Presented in German ophthalmological society Congress. Leipzig. 2014.
11. Ivarsen A, Hjortdal J. Seven-year changes in corneal power and aberrations after PRK or LASIK. *Invest Ophthalmol Vis Sci.* 2012;53:6011–6.
12. Kirwan C, O’Keefe M. Comparative study of higher order aberrations after conventional laser in situ keratomileusis and laser epithelial keratomileusis for myopia using the Technolas 217z laser platform. *Am J Ophthalmol.* 2009;147:77–83.
13. Wallau AD, Campos M. One-year outcomes of a bilateral randomised prospective clinical trial comparing PRK with mitomycin C and LASIK. *Br J Ophthalmol.* 2009;93:1634–8.
14. Manche EE, Haw WW. Wavefront-guided laser in situ keratomileusis (LASIK) versus wavefront guided photorefractive keratectomy (PRK): a prospective randomized eye-to-eye comparison (An American Ophthalmological Society thesis). *Trans Am Ophthalmol Soc.* 2011;109:201–20.



**Part II**  
**Errors in Corneal Refractive Surgery**

# Chapter 5

## Sources of Error in Corneal Refractive Surgery

Toam R. Katz

The LASIK procedure today has reached very high predictability in terms of refractive and visual acuity parameters. Commonly the reported high predictability (0.5D) is over 97 %, the EI is around 1.0, and the SI is even higher, which means the typical operated eye has maintained or improved its DCVA after Lasik. The rash progress in technology gives us diagnostic and surgical tools that are extremely accurate, measuring and ablating 0.01 of a Diopter and HOA in micrometer scale. One may expect that a non complicated corneal refractive surgery such as LASIK, surface ablation or intrastromal lenticule extraction should gap the distance to optimum. However this will always stay an Utopia. The weak link is not the instruments we use but rather the humans around it, the surgeon as well as the patient himself. Moreover, the subjective success of a corneal refractive surgery can not be measured with mere SI and EI. The success of a refractive surgery should be analyzed in a holistic approach. Which factors may differentiate between success and failure?

### Refraction Measurement

When we measure the accuracy of the Excimer surgery in term of UDVA, CDVA and predictability we base on the pre-operative and post-operative refraction data. Our efficacy of the surgical procedure is a result of our efficacy in refraction measurement. The refraction of every refractive candidate is prone to variations of

---

T.R. Katz, MD, PhD  
Department of Ophthalmology, University Medical Center Hamburg Eppendorf,  
Martinistr. 52, Hamburg 20246, Germany

CARE Vision Germany GmbH, Ruesterst. 1, Frankfurt/Main 60325, Germany  
e-mail: [t.katz@uke.de](mailto:t.katz@uke.de)

© Springer International Publishing Switzerland 2016  
S.J. Linke, T. Katz (eds.), *Complications in Corneal Laser Surgery*,  
DOI 10.1007/978-3-319-41496-6\_5

33

different sources: the method of measurement, the examined person, the examined eye and the examiner.

The commonly used refraction methods vary from automatic refraction by an auto-refractometer, manifest refraction done by subjective assessment interacted between examined and examiner and cycloplegic refraction done in mydriasis under cycloplegia. The golden standard is the correctly done manifest subjective refraction (MSR). Modern techniques for automated refraction like the WASCA aberrometry refraction in myopes [1] was proved to be less accurate than MSR.

The automatic refraction is fairly accurate but prone to errors due to examined person cooperation, the centration on the projected visual target, the accommodation, pupil size, tear film and machine errors. It has the advantage of time sparing and objectivity and may be used as a general guideline to the refraction range of the examined eye. Due to the inherent errors the auto-refractometer presents the mean values of several automatic measurements.

The manifest subjective refraction is done as trial and error test series of visual acuity preference with the aid of different dioptric correction. The examined person should identify standard optotypes under standard room conditions. The MSR is subjective to errors due to concentration and communication of both examiner and examined person, different room conditions, maximal visus tested, visus table used and machine failures. Most examiners stop testing when the visus reached a level of 1.0 or 1.2. Some examiners round the visus level to full decimal lines; for example visus of 0.58 may sometimes be taken as 0.6 and rounded in Snellen Log MAR scale to 0.63. This mistake is even worse when the pre- and post-operative MSRs are done by different examiners and in different setups.

The repeatability of manifest refraction (intra-examiner reliability) and the reproducibility (inter-examiner reliability) should be evaluated when as many measurements as possible are compared. The mean standard deviation for MSR measured [2] when 12 eyes were refracted on 5 separate occasions, and the examiner was not able to know the previous refraction, was  $\pm 0.14$  D, indicating a 95 % confidence limits of  $\pm 0.27$ D. The coefficient of repeatability (the interval within 95 % of test-retest measurements differences lie) of manifest SE for all eyes is approximately 0.74 D [3].

The reproducibility of MSR measured by the 40 examiners was twice as large:

An eye opening study [4] showed that when the same mild myopic astigmatic eye (mean SE  $-0.83$  D) of a non presbyopic healthy 29-year-old male was refracted by 40 different experienced examiners in different setups the SE values were estimated between  $-1.38$  and  $-0.28$  D and the 95 % reproducibility limit was 0.78 D for the SE and  $\pm 0.17$  D for the cylindrical powers.

In a literature review [5] of the reproducibility of MSR in most studies were close to 80 % agreement within  $\pm 0.25$ D and 95 % agreement within  $\pm 0.5$ D.

It seems that in spite of effort to standardize the MSR a certain inconsistency is inherent in the MSR method itself. This human natural inconsistency is the limiting factor in achieving a better predictability of corneal refractive surgery. The much higher technical accuracy reached in the up to date laser platform plays probably a secondary role.

## The Cycloplagic Refraction (CR)

The goal of pharmacological cycloplegia is to paralyze the accommodation hence to measure the “pure” refraction of the relaxed eye. By cycloplegia we should measure more hyperopic, less myopic refraction than MSR. The importance of CR in refractive surgery is with its relation to the MSR. A high CR-MSR difference pre operatively may predict an accommodation spasm, especially by young hyperopes, that may persist or relax after the refractive surgery. If it persists post operatively the surgery refraction parameters should base on CR. If fully relaxes post operatively the surgery refraction parameters should base on CR. Several nomograms relate to this question. Ideally the MSR should be measured while fixating at distance hence relaxing the accommodation. The MSR-CR difference should be ideally zero. The higher the MSR-CR difference, the lower the predictability of the post operative result. Errors in the CR per se are due to different pharmacological cycloplegics (Cyclopentolate or Mydramide) with different amount and duration of accommodation paralysis, different individual reaction of the same eye drops, the change in sphere and cylinder measurements between photopic and cycloplegic pupils, and the lower DCVA under cycloplegia.

## Flap and Epithelium

Preparing the LASIK Flap and removing the epithelium before PRK is a must to allow the Excimer ablation. We assume that this action does not change the postoperative result in the long run. It seem however that cutting the flap until its hinge and replacing it back correctly are not refraction neutral. Since the flap is placed on a flatter stroma after myopic correction or steeper stroma after hyperopic correction it must be somewhat distorted, inducing astigmatism. The asymmetric fixation by the hinge can effect these 3 dimensional changes causing an uncalculated astigmatism [6]. The healing of the epithelium after PRK is known to produce temporary irregular surface and irregular astigmatism with low DCVA over several weeks. The long term efficacy may be effected by epithelial remodelling thinning over step stroma and thickening to fill up stromal indentation. A dry eye syndrome post LASIK or surface ablation (SA) may extend these problems over many months and is discussed later in this book. The healing is controlled with application of cortisone, antibiotics and artificial tears eye drops. It is well known that not all patient react to the post operative treatment as expected. Subjective healing variations are a constant source of suboptimal refractive results.

## Excimer Nomograms

Even if we assume that only the Excimer ablation effects the change in refraction of the operated eye, we should look for possible errors in the ablation itself. The effect of the intended ablation depends on many factors. The main players

are the Excimer pulses targeted at the stroma, the stroma that reacts to the laser, and the centering and tracking mechanisms which decide the interaction between them.

The Excimer pulses aim to produce a smooth stepless ablation profile, without heating the stroma or even letting it desiccate. All modern Excimer platforms adopt a narrow “floating” beam ablating the surface in a partly randomly order to avoid over heating of one spot while the rest dries out. The common beams have a diameter of 1 mm or less, Gaussian profile and a repetition rate of 200–1000 Hz and consume about 15  $\mu\text{m}$  stroma per myopic Diopter correction. A certain amount of stromal desiccation by opened flap or removed epithelium is unavoidable. A dried stroma will absorb more Excimer energy and will be over ablated. A high water content in a wet stroma absorbs some of the energy causing under ablation. Special ablation nomograms are used to compensate for the desiccation time either by increasing the repetition rate to reduce the total desiccation time or by over ablation of shorter ablations under 2 D of myopia and under ablation for longer ablation over 6.5 D of myopia. More complex nomograms include interactions between sphere and cylindric ablations and compensate for optical zone size, spherical and other HOAs and platform specific parameters. All these nomogram are secret of trade of each manufacturer and are averagely calculated. However a surgeon specific as well as model and platform specific factors should be analyzed with time and implemented. A less effective laser head or a very quick surgeon may affect the actual ablation.

The eye tracking and the centration of the ablation allow the interaction between the ablation pulse and the actual stromal change. The multi dimensional eye trackers identify biometric data of the operated eye such as pupil size and center, iris contours or limbal blood vessels. Some may be acquired pre-operatively in sitting position and used intra operatively in supine position. Correct and continuous tracking is a must for targeted ablation. These may include errors due to platform calibration errors, low cooperation of the patient, difference in pupil size and its center, mydiatics, and cyclotorsion.

The ablation center should be decided and controlled by the surgeon. It is measured in relation to the eye tracking reference point, such as image of the pupil center on the cornea. This reference point on the cornea is not necessarily the optimal ablation center [6]. Optically speaking the ideal ablation center on the cornea should be on the straight line connecting the target and its image on the fovea (line of sight). In most eyes and especially in hyperopic eyes the corneal reflection of this line (1st Purkinje image) lays a bit nasal to the pupil center reflection. This offset is known as angle kappa and may be measured pre-operatively or intra-operatively [7]. The position of Purkinje image is theoretically the best location for the center of ablation. However there is no evidence in literature for this advantage over the mere pupil center as ablation center [8]. The head tilt during the ablation and the patient cooperation may also compromise the correct centering of the ablation [9].

## Technical Errors and Failures

As in any laser assisted microsurgical procedure an exact calibration of the Excimer laser and testing of the microkeratom or FSL is mandatory. The proper maintenance includes changing of gases, maintaining the cleanness and calibration of the optical surfaces and mirrors and routine laser energy checks. The FST docking and MK-fixation ring attachment use vacuum produced by an air pump. The surgeon should be aware of signs for correct vacuum before and during the keratectomy.

A proper vacuum should be short but strong enough to allow the linear progression of the FSL raster or the MK blade. The signs for adequate vacuum are:

1. Pump control shows a constant sufficient vacuum
2. The eye may be pulled up by the MK/FS vacuum ring without disengagement
3. The intra ocular pressure is palpable high
4. The patient reports a total scotoma and pressure
5. The pupil is non reactive

After verifying this signs the surgeons may proceed with the MK or FSL keratectomy. This does not guarantee a perfect flap as irregular flaps may happen without identified reason. Even a perfect position and size of the flap, accurate centration of the ablation and exact repositioning of the flap on the stromal bed do not assure an error free result.

In summary, numerous sources of error emerging from the pre-operative measurements, accuracy of the MK/FSL and Excimer platform, patients' cooperation and individual post operative healing may affect the predictability of the corneal refractive surgery. It seems that the biggest source of error is the accuracy of the pre-operative refraction. In spite of all that the corneal laser surgery is one of the safest and most accurate surgical procedures in medicine.

## References

1. Zhu X, Dai J, Chu R, Lu Y, Zhou X, Wang L. Accuracy of WASCA aberrometer refraction compared to manifest refraction in Chinese adult myopes. *J Refract Surg.* 2009;25(11):1026–33.
2. Rosenfield M, Chiu NN. Repeatability of subjective and objective refraction. *Optom Vis Sci.* 1995;72(8):577–9.
3. Leionen J, Laakkonen E, Laatikainen L. Repeatability (test-retest variability) of refractive error measurement in clinical setting. *Acta Ophthalmol Scand.* 2006;84(4):532–6.
4. MacKenzie GE. Reproducibility of spherocylindrical prescriptions. *Ophthalmic Physiol Opt.* 2008;28:143–50.
5. Goss DA, Grosvenor T. Reliability of refraction- a literature review. *Am Optom Assoc.* 1996;67(10):619–30.
6. Katz T, Frings A, Richard G, Steinberg J, Druchkiv V, Linke SJ. Flap-induced astigmatism in eyes with sphere myopia correction: superior hinge using a rotating microkeratome versus nasal hinge using a linear microkeratome. *J Cataract Refract Surg.* 2015;41(6):1160–7.

7. Boxer Wachler BS, Korn TS, Chandra NS, Michel FK. Decentration of the optical zone: centering on the pupil versus the coaxially sighted corneal light reflex in LASIK for hyperopia. *J Refract Surg.* 2003;19:464–5.
8. Basmak H, Sahin A, Yildirim N, Papakostas TD, Kanellopoulos JA. Measurement of angle kappa with synoptophore and Orbscan II in a normal population. *J Refract Surg.* 2007;23:456–60.
9. Arbelaez MC, Vidal C, Arba-Mosquera S. Clinical outcomes of corneal vertex versus central pupil references with aberration-free ablation strategies and LASIK. *Invest Ophthalmol Vis Sci.* 2008;49(12):5287–94.

# Chapter 6

## Refractive Surgery in Systemic Diseases and Non Ectatic Eye Pathologies

Fernando Llovet, Julio Ortega-Usoabiaga, and Andrea Llovet

### Refractive Corneal Surgery in Systemic Diseases

Every patient who wants to go in for refractive surgery should be asked about their general clinical history. Every medical or surgical event in the past could be crucially important in the case they undergo refractive surgery. The data about diseases, medications, surgeries and allergies should be collected. Some of these may affect the postoperative period of the patients [1].

Systemic contraindications	
Absolute	Relative
Active or uncontrolled autoimmune diseases	Diabetes mellitus
	Autoimmune diseases
	Systemic immunodeficiency
	Drugs: isotretinoin, amiodarone, sumatriptan, levonorgestrel, colchicine
Pregnancy and breast feeding	

**Electronic supplementary material** The online version of this chapter (doi:[10.1007/978-3-319-41496-6\\_6](https://doi.org/10.1007/978-3-319-41496-6_6)) contains supplementary material, which is available to authorized users.

F. Llovet, MD, PhD (✉)

Department of Refractive and Cataract Surgery, Clínica Baviera, Madrid, Spain  
e-mail: [fllovet@clinicabaviera.com](mailto:fllovet@clinicabaviera.com)

J. Ortega-Usoabiaga, MD, PhD

Department of Refractive and Cataract Surgery, Clínica Baviera, Bilbao, Spain

A. Llovet, MD

Ophthalmology, Centro de Oftalmología Barraquer, Barcelona, Spain



## ***Diabetes Mellitus (DM)***

As much as 4–8% of the population in the western societies is affected by diabetes. Many of them are looking forward to refractive surgery, so we have to take into account that this disease may be associated with several eye disorders, such as refractive instability, vitreous-retinal complications, cataracts, corneal structural changes and prolonged wound healing response. Not only should we discard diabetic retinopathy but also we must think about its possible appearance in the future.

The corneal epithelium can be affected in some diabetic patients. Therefore, a careful study of the epithelium is mandatory if LASIK surgery is planned.

We consider that LASIK and surface ablation is safe when the diabetes is well controlled and stable (including HbA1C < 6%), and no ocular complications are present [2].

## ***Connective Tissue and Autoimmune Diseases***

Corneal refractive surgery in patients with underlying autoimmune diseases has been highly controversial. Since the beginning of PRK and LASIK, the US FDA has considered that this wide and heterogeneous group of people should not be operated on. The possible greater inflammatory response could cause corneal scarring, haze and is correlated with an increased risk of corneal melting.

However, this recommendation has never been based on clinical studies but isolated case reports after systemic lupus erythematosus [3, 4] or rheumatoid arthritis [5].

In 2006, three independent papers arrived at the same conclusion: laser refractive surgery may be done safely and effectively if the systemic disease is controlled and stable. Patients with different diseases, such as systemic lupus erythematosus, rheumatoid arthritis, spondyloarthropathy, psoriasis, Crohn's disease, ulcerative colitis, juvenile rheumatoid arthritis, fibromyalgia, scleroderma, dermatomyositis, relapsing polychondritis, Reiter's syndrome, Graves' disease, Behçet's disease and other vasculitis were studied [6–8].

A later meta-analysis of every reported cases before 2008 found that the risk of developing a late-onset severe epithelial complication in the first 2 years was lower than 2.5% and, although mild to moderate epithelial complications may appear, they occur as frequently as in the general standard LASIK population [1].

We strongly recommend to study the eye surface, tear film and the lacrymal function very carefully in these patients before performing LASIK or surface ablation.

We consider that patients with autoimmune disorders are just relatively contraindicated when considering LASIK or surface ablation, depending on the non existence of systemic and eye activity.

### ***Skin Queloids***

Patients with skin queloids were initially included in the list of contraindications by the US FDA. However, they were removed later on. Isolated case reports and short series of cases of LASIK and surface ablations in these patients have been described and a standard postoperative course is expected [1].

### ***Infectious Diseases***

In case of controlled patients with human immunodeficiency virus (HIV) or hepatitis (HBV, HCV), the general guidelines on precautions and management of these patients should be followed [1].

### ***Psychiatric Disorders***

Patients with compensated psychiatric disorders (schizophrenia, obsessive-compulsive disorder and bipolar disorder) achieve excellent results after surgery, with no remarkable ocular complications. They may be operated on if they are stable and controlled. Their psychiatrist should be aware of the operation.

Their medication can affect the result of LASIK and surface ablation. Haloperidol and tricyclic and tetracyclic antidepressants may alter the lacrymal film. Antipsychotics and lithium have been related with instable refraction [9].

However the psychological state of the patient can affect the subjective happiness with the medical and refractive outcome. Very meticulous preoperative patient evaluation, a thorough estimation of the patient's realistic expectations and a close follow up is recommended for patients with an anamnesis of psychiatric disorder.

### ***Neuro-ophthalmic Disorders***

The neurological diseases that may affect the visual function are not an absolute contraindication for corneal refractive surgery. In fact, in some patients with severe deterioration due to a neurodegenerative process LASIK and surface ablation may improve their quality of life, by not using glasses and contact lenses.

There have been reported cases of post-LASIK optic neuropathies when the time of suction has been extremely long or due to a long postoperative steroid treatment.

Some stability of the neurological disorder is recommended. Preoperatively, visual field and OCT of the optic nerve and macula should be obtained, and compared with postoperative ones. The status of the visual system must be explained and the differentiation between refractive correction and neuro-ophthalmic disorder must clearly be outlined.

Patients with severe alteration of the visual field or very low corrected visual acuities should not be operated on. In case of confluent optic nerve drusen surface ablation is preferred in order to avoid the suction of the microkeratome [10, 11].

## *Drugs*

1. **Immunosuppression caused by drugs.** Although these drugs have not been proved that they increase the risk of corneal infection or other anatomic complications in some controlled studies, the chronic use of corticosteroids must be taken into account (cataracts, ocular hypertension). Some other drugs may affect the surgical process:

- (a) **Isotretionin.** It may induce dry skin and dry eye. Therefore, a careful study of the eye surface and lachrymal function should be performed. If necessary, the operation should be postponed for 6 months after having quit the medication.
- (b) **Sumatriptan.** Although it had been related with a higher incidence of epithelial defects after LASIK, a study by Hardten did not confirm these findings. As the substitutive hormone therapy could be worse for the epithelium, nowadays we do not recommend to stop sumatriptan [12].

## *Pregnancy and Breastfeeding*

During pregnancy and breastfeeding refractive surgery is contraindicated due to the possible corneal and refractive changes. Another reason is the possibility that a severe complication may occur and potentially dangerous drugs for the fetus are necessary [13].

Refractive surgery is usually recommended 3 months after having finished breastfeeding [1].

## *Summary*

Although LVC is a localized surgical procedure general anamnesis and consideration of systemic disease is warranted.

## Refractive Corneal Surgery in Eye Pathologies

### *Ocular Adnexa*

Every candidate to refractive surgery should have their ocular adnexae studied: eyelid function, eyelid position, and lacrimal function.

Some common lid diseases, such as chalazion and blepharoptosis, may affect the ocular refraction. The floppy eyelid syndrome can cause severe ocular surface problems which can be worsened after refractive surgery. It is recommended to treat these diseases before undergoing refractive surgery [14–16].

### *Herpes Simplex Keratitis*

Corneal laser refractive surgery in patients with past herpes simplex keratitis is highly controversial, due to the risk of reactivation of the keratitis [17, 18]. On the one hand, it has been proven that herpes simplex virus can be reactivated by the effect of the excimer laser; on the other hand prophylactic treatment (400 mg of oral acyclovir every 12 h) reduces the risk of reactivation. Three studies did not find any reactivations after LASIK when oral prophylaxis had been used.

The patient must be asked about the history of his keratitis. LASIK can be indicated if no keratitis has appeared in the last year, corneal sensitivity is normal and no history of stromal keratitis or uveitis is present, as these patients have an increased risk of reactivation and it can be more dangerous for the patient. Corneal topography and pachymetry must be normal, and the patient must be informed about the possibility of reactivation of the virus [19].

The prophylaxis should be oral, because the topical treatment does not prevent from reactivations of the virus. The exact drug, dose and timing to be used in LASIK surgery is yet to be established. The beginning of the treatment is recommended 1 week before surgery as no reactivations have been published respecting this protocol. One case of herpes reactivation occurred when starting systemic antiviral therapy only on the day of the surgery. The treatment should be continued as long as long as topical steroids are being used – ideally 3 months after surgery in a prophylactic regimen (3 × 400 mg Aciclovir after 3 weeks of 3 × 800 mg Aciclovir).

The drug may be valacyclovir (500 mg every 12 h) or acyclovir (800 mg every 8 h), from 1 week before LASIK until 2 weeks after surgery [14, 20–23].

### *Corneal Dystrophies*

Patients with a reduced adherence of the corneal epithelium, such as patients with Cogan's dystrophy, may present recurrent corneal erosions after LASIK [24]. As photo-refractive keratectomy (PTK) has been successfully used to treat recurrent

corneal erosions, surface ablation is preferred when applying excimer laser in these patients. PTK strengthens the union of cells and adherent complexes, allowing for a smooth surface to appear and a new epithelium to adhere. Although new erosions may occur after PTK, these are usually rare and not severe [25].

The experience in patients with the other anterior dystrophies, such as Lisch's dystrophy and Meesman's dystrophy, is controversial.

Stromal dystrophies associated with a mutation of the TGF beta gen (Reis-Bückler, Thiel-Behnke, lattice and granular) may be asymptomatic and difficult to diagnose in some cases. However any surgery can aggravate the disease. LASIK and PRK increase the deposits of transforming growth factor beta-induced gene product (TGFBIp) and reduce postoperative visual acuity.

As after corneal transplantation the deposits may appear again, in some stromal dystrophies PTK may postpone keratoplasty by ablating corneal deposits.

Patients with anterior corneal dystrophies may undergo PTK/PRK when the location of the opacities is anterior [26, 27].

Laser refractive surgery is safe in patients with isolated mild corneal guttate without any clinical findings such as stromal edema or endothel cell count below 2000 cells/mm<sup>2</sup> or any symptoms (Halos/blurred vision). When Fuchs' dystrophy is diagnosed, a careful study of the corneal endothelium and pachymetry must be performed in order to avoid refractive surgery if the risk of corneal decompensation and oedema is high [28].

LASIK in patients with posterior polymorphous dystrophy has been proven to be safe in selected cases [29].

## ***Glaucoma***

Most of the people who undergo corneal refractive surgery are young myopes. There is a risk of underdiagnose glaucoma in the future [30–32]. Pascal tonometer and ORA are useful to measure IOP in patients that have undergone PRK and LASIK [33, 34]. Standard non contact or applanation Goldmann tonometry should take into account the thinned corneal thickness and use correction tables for the calculated IOP.

Glaucoma suspects may be operated on the same way as any other patient when there is no evidence of optic nerve damage. Some recommendations to be followed in these patients are regular IOP measurements, preoperative visual field testing, optic nerve photographs, optic disc and nerve fiber layer study (OCT, HRT, GDx), and gonioscopy.

When glaucoma is moderate, the IOP is well controlled and the visual field is stable, refractive surgery is relatively contraindicated. The editors of this book advice against refractive surgery in the case of visual field scotomas. As the optic nerve is already damaged, surface ablation is a better option than LASIK, in order to avoid the increased pressure induced by the suction ring. IOP must be monitored regularly (2–3 weeks during steroid treatment) after surface ablation because of the effect that steroids may have. One third of the population is steroid-sensitive, and

people with glaucoma have a higher risk to develop a steroid-induced glaucoma. As topical dexamethasone and prednisolone seem to be more dangerous, Fluorometholone and Rimexolone are preferred [35].

If a filtering surgery has been performed LASIK surgery is contraindicated. Surface ablation could be a choice when the glaucoma is stable and moderate.

## *Uveitis*

Corneal refractive surgery is not recommended when the patient has an anterior recurrent uveitis (more than once a year), chronic anterior uveitis and autoimmune uveitis.

Patients with unilateral idiopathic anterior uveitis may undergo LASIK when the uveitis appears less than once a year and they are asymptomatic. Topical steroids should be applied preoperatively (four times a day during the week before LASIK) and every 2–4 h after surgery during 2 weeks. Then the steroid must be lowered the following month [14].

## *Strabismus*

The decompensation of a previous strabismus and the appearance of diplopia may be a severe complication after corneal refractive surgery. Therefore, patients with strabismus must be carefully studied [36].

The main causes of diplopia after corneal surgery are [37–39]:

- (a) Previous diplopia. The patient may have a prism in their glasses.
- (b) Decompensation of a previous strabismus.
- (c) Overcorrection of a myopic patient with endophoria.
- (d) Aniseikonia.
- (e) Alteration of the central mechanism of fusion.

Monovision may cause diplopia in patients with problems in their binocularity when they are forced to use the dominant eye in near distance.

The risk of decompensation after refractive surgery is low when the strabismus is stable since childhood, the spectacle refraction is actual and tolerated, diplopia has never appeared and diplopia is not present in the study of the patient.

The risk is moderate in high hyperopes with accommodative esotropia, patients with hyperopia and exotropia that are undercorrected in their glasses, patients with overcorrected myopia and compensated intermittent exotropia and patients with instable binocularity.

The risk is high in patients with high and not corrected anisometropia, patients with not corrected unilateral aphakia and patients with intermittent and instable deviation that undergo monovision [14].

It is mandatory to study the ocular motility with contact lenses and the refraction that is intended to correct. This may assess the risk of postoperative diplopia.

## ***Retinal Lesions***

The retina must be carefully studied before corneal refractive surgery and after the operation. Retinal tears may be an accidental finding before or after LASIK as well as if the patient had not undergone refractive surgery. In many patients, retinal lesions are found preoperatively and some must be treated [40].

Although some cases of retinal detachment after LASIK have been reported, long series have shown that there is no relationship between LASIK and retinal problems, such as retinal tears, retinal detachment, neovascular membranes and macular holes. [14, 41–45].

LASIK may be performed in eyes that have been operated with scleral buckling for retinal detachment if the retina is carefully studied preoperatively [46].

The incidence of vitreous detachment in myopes before and after LASIK was analyzed in a small series using OCT and was not increased [47].

## **References**

### ***Refractive Corneal Surgery in Systemic Diseases***

1. Llovet-Osuna F, Ortega-Usobiaga J. Cirugía refractiva. Protocolos. Madrid: Sociedad Española de Oftalmología; 2014.
2. Fraunfelder FW, Rich LF. Laser-assisted in situ keratomileusis complications in diabetes mellitus. *Cornea*. 2002;21:246–8.
3. Seiler T, Wollensak J. Complications of laser keratomileusis with the excimer laser (193 nm). *Klin Monatsbl Augenheilkd*. 1992;200:648–53.
4. Cua IY, Pepose JS. Late corneal scarring after photorefractive keratectomy concurrent with development of systemic lupus erythematosus. *J Refract Surg*. 2002;18:750–2.
5. Lahners WJ, Hardten DR, Lindstrom RL. Peripheral keratitis following laser in situ keratomileusis. *J Refract Surg*. 2003;19:671–5.
6. Cobo-Soriano R, Beltran J, Baviera J. LASIK outcomes in patients with underlying systemic contraindications. A preliminary study. *Ophthalmology*. 2006;113:1118–24.
7. Alió JL, Artola A, Belda JI, et al. LASIK in patients with rheumatic diseases. A pilot study. *Ophthalmology*. 2005;112:1948–54.
8. Smith RJ, Maloney RK. LASIK in patients with autoimmune diseases. *J Cataract Refract Surg*. 2006;32:1292–5.
9. Ortega-Usobiaga J, García-Sáenz MC, Artaloytia-Usobiaga JF, Llovet-Osuna F, Beltrán-Sanz J, Baviera-Sabater J. Myopic LASIK in psychiatric patients. *Cornea*. 2012;31:150–4.
10. Bilbao-Calabuig R, López-Valdés E, González-López F, Llovet-Osuna F. Delayed acute optic neuropathies following LASIK. *J Emmetropia*. 2011;2:245–7.

11. Shetty R, Babu RB, Suresh M, Samprathi AB, Shetty BK. Neuro-ophthalmic disorders presenting as a diagnostic surprise during pre-LASIK evaluation. *J Cataract Refract Surg.* 2007;33:1653–6.
12. Hardten DR, Hira NK, Lombardo AJ. Triptans and the incidence of epithelial defects during laser in situ keratomileusis. *J Refract Surg.* 2005;21:72–6.
13. O'Doherty MA, O'Doherty JV, O'Keefe M. Outcome of LASIK for myopia in women on hormone replacement therapy. *J Refract Surg.* 2006;22:350–3.

### ***Refractive Corneal Surgery in Eye Pathologies***

14. Llovet-Osuna F, Ortega-Usobiaga J. Cirugía refractiva. Protocolos. Madrid: Sociedad Española de Oftalmología; 2014.
15. Cosar CB, Rapuano CJ, Cohen EJ, Laibson PR. Chalazion as a cause of decreased vision after LASIK. *Cornea.* 2001;20:890–2.
16. Victoria AC, Chuck RS, Rosenberg J, Schwarcz RM. Timing of eyelid surgery in the setting of refractive surgery: preoperative and postoperative considerations. *Curr Opin Ophthalmol.* 2011;22:226–32.
17. Lu C-K, Chen K-H, Lee S-M. Herpes simplex keratitis following excimer laser application. *J Refract Surg.* 2006;22:509–11.
18. Jarade EF, Tabbara KF. Laser in situ keratomileusis in eyes with inactive herpetic keratitis. *Am J Ophthalmol.* 2001;132:779–80.
19. Herpetic Eye Disease Study Group. Predictors of recurrent herpes simplex virus keratitis. *Cornea.* 2001;20:123–8.
20. Asbell PA. Valacyclovir for the prevention of recurrent herpes simplex virus eye disease after excimer laser photorefractive keratectomy. *Trans Am Ophthalmol Soc.* 2000;98:285–303.
21. Dhaliwal DK, Romanowski EG, Yates KA, et al. Valacyclovir inhibition of recovery of ocular herpes simplex virus type 1 after experimental reactivation by laser in situ keratomileusis. *J Cataract Refract Surg.* 2001;27:1288–93.
22. De Rojas SV, Díez-Feijóo E, Javaloy J, Sánchez SM. Prophylactic perioperative antiviral therapy for LASIK in patients with inactive herpetic keratitis. *J Refract Surg.* 2006;22:3–5.
23. De Rojas V, Rodríguez R, Cobo R, Beltrán J, Llovet F, Baviera J. LASIK in patients with a history of ocular herpes. *J Cataract Refract Surg.* 2007;33:1855–9.
24. Germundsson J, Fagerholm P, Lagali N. Clinical outcome and recurrence of epithelial basement membrane dystrophy after phototherapeutic keratectomy. A cross-sectional study, 2011. *Ophthalmology.* 2011;3:515–22.
25. Dogru M, Katakami C, Miyashita M. Ocular surface changes after excimer laser phototherapeutic keratectomy. *Ophthalmology.* 2000;107:1142–52.
26. Droutsas D, Tsioulis G, Kotsira J, et al. Phototherapeutic keratectomy in macular corneal dystrophy with recurrent erosions. *J Refract Surg.* 1996;12:S293–4.
27. Wagoner M, Badr I. Phototherapeutic keratectomy for macular corneal dystrophy. *J Refract Surg.* 1999;15:481–4.
28. Vroman DT. Endothelial decompensation after laser in situ keratomileusis. *J Cataract Refract Surg.* 2002;28:2045–9.
29. Moshirfar M, Barsam CA, Tanner MC. Laser in situ keratomileusis in patients with posterior polymorphous dystrophy. *Cornea.* 2005;24:230–2.
30. Benítez del Castillo J, Belda JI. Glaucoma y Cirugía Refractiva. Madrid: Sociedad Española de Oftalmología; 2008.
31. Osman E. Laser refractive surgery in glaucoma patients. *Saudi J Ophthalmol.* 2011;25:169–73.
32. Shrivastava A, Madu A, Schultz J. Refractive surgery and the glaucoma patient. *Curr Opin Ophthalmol.* 2011;22:215–21.



33. Tsai AS, Loon SC. Intraocular pressure assessment after laser in situ keratomileusis: a review. *Clin Exp Ophthalmol.* 2012;40:295–304.
34. Chihara E. Assessment of true intraocular pressure: the gap between theory and practical data. *Surv Ophthalmol.* 2008;53:203–18.
35. Kersey JP, Broadway DC. Corticosteroid-induced glaucoma. A review of the literature. *Eye.* 2006;20:407–16.
36. Kowal L, Battu R, Kushner B. Refractive surgery and strabismus. *Clin Exp Ophthalmol.* 2005;33:90–5.
37. Godts D, Tassignon MJ, Gobin L. Binocular vision impairment after refractive surgery. *J Cataract Refract Surg.* 2004;30:10.
38. Gómez de Liaño-Sánchez R, Borrego-Hernando R, Franco-Iglesias G, Gómez de Liaño-Sánchez P, Arias-Puente A. Strabismus and diplopia after refractive surgery. *Arch Soc Esp Ophthalmol.* 2012;87:363–7.
39. Kushner BJ, Kowal L. Diplopia after refractive surgery: occurrence and prevention. *Arch Ophthalmol.* 2003;121:315–21.
40. Chan CK, Arevalo JF, Akbatur HH, Sengün A, Yoon YH, Lee GJ, et al. Characteristics of sixty myopic eyes with pre-LASIK retinal examination and post-LASIK retinal lesions. *Retina.* 2004;24:706–13.
41. Arévalo JF. Posterior segment complications after LASIK. *Curr Opin Ophthalmol.* 2008;19:177–84.
42. Arévalo JF. Retinal complications after LASIK. *Curr Opin Ophthalmol.* 2004;15:184–91.
43. Ruiz-Moreno JM, Alió JL. Incidence of retinal disease following refractive surgery in 9,239 eyes. *J Refract Surg.* 2003;19:534–47.
44. Arévalo JF, Mendoza AJ, Vélez-Vázquez W, Rodríguez FJ, Rodríguez A, Rosales-Meneses JL, et al. Full-thickness macular hole after LASIK for the correction of myopia. *Ophthalmology.* 2005;112:1207–12.
45. Arévalo JF, Lasave AF, Torres F, Suárez E. Rhegmatogenous retinal detachment after LASIK for myopia of up to –10 diopters: 10 years of follow-up. *Graefe's Arch Clin Exp Ophthalmol.* 2012;250:963–70.
46. Belda JI, Ruíz-Moreno JM, Pérez-Santonja JJ, Alió JL. Laser in situ keratomileusis to correct myopia after scleral buckling for retinal detachment. *J Cataract Refract Surg.* 2003;29:1231–5.
47. Eddy M, Pantazis D, Steinberg J, Richard G, Katz T, Linke S. Posterior vitreous detachment post LASIK? [Posteriore Glaskörperabhebung nach LASIK?]. *Augenspiegel.* 2010;56(12):22–3.

**Part III**  
**Complications and Management in Laser**  
**Refractive Lamellar Surgery and Laser**  
**Refractive Surface Ablation**

# Chapter 7

## Microkeratome LASIK Intraoperative Complications

Toam R. Katz

### The Ideal Flap

The ideal lasik flap should fulfill the following anatomical qualities:

1. Large enough to cover the ablation zone and safety margins
2. Small enough not to involve limbal stem cells and vessels
3. Thick enough to allow proper lifting and repositioning without tearing or folding
4. Thin enough to save on stromal tissue and strength
5. Have constant thickness and continuous layers of epithelium, Bowmans' membrane and flap stroma.
6. Stable stromal tissue bridge (the hinge) to avoid movement or loss of flap

The classic lasik flap that fulfills these 6 qualities is round until the 4 mm wide superior or nasal hinge, about 9 mm in diameter and 100  $\mu\text{m}$  thick, and covers the ablation zone and safety margins. The flap is cut after the eye is fixated and stabilized with a suction ring. The cutting instrument, either a motor driven blade (microkeratom) or a femtosecond laser (FSL) engaged flattening disc is attached to the suction ring and the cutting procedure takes place over 3–15 s automatically. Only after disengaging the suction ring one can assess the quality of the freshly cut flap. An important difference in flap form between both methods is that FSL- flap has almost vertical peripheral border cut compared to the gradually deepening microkeratom peripheral cut, and that FSL-Flap used expansion of “plasma” CO<sub>2</sub> gas bubbles to disrupt the desired plane. Tissue bridges still connect the flap to the

---

T.R. Katz, MD, PhD  
Department of Ophthalmology, University Medical Center Hamburg Eppendorf,  
Martinistr. 52, 20246 Hamburg, Germany

CARE Vision Germany GmbH, Ruesterst. 1, 60325 Frankfurt/Main, Germany  
e-mail: [t.katz@uke.de](mailto:t.katz@uke.de)

stromal bed and should be separated manually. FSL flap complications are discussed in chapter Femtosecond Lasik complications in detail.

## **An Irregular Flap Is Caused by a Technical Failure or Human Error**

An irregular flap is any flap position and form that deviates from the six conditions to a clinically relevant extent. An irregular flap is caused by a technical failure of the suction and cutting mechanisms of by human error of choosing the correct cutting parameters. It may be caused by problems like loss of fixation between the eye and the suction ring due to vacuum loss or unwanted movement of the patient, mechanical stop of the microkeratom progression by motor failure or obstruction to the motor by tissue or eye speculum, blunt or damaged blade, misalignment of the flattening plate of the FSL- flap, trapping of air or foreign substances between the flattening plate and the cornea, expansion of gas bubbles perforating the FSL-flap to the epithelial surface, or any failure of the FSL causing uncompleted raster of the intended FSL-flap disruption. Existing corneal scars and opacities and previous corneal cuts such as after previous LASIK, radial keratotomy or after corneal inflammations and wounds might cause irregular cutting of the microkeratom flap but is contra indicated for a FSL- flap since the Femtolaser must pass a clear cornea to focus on the intended raster depth.

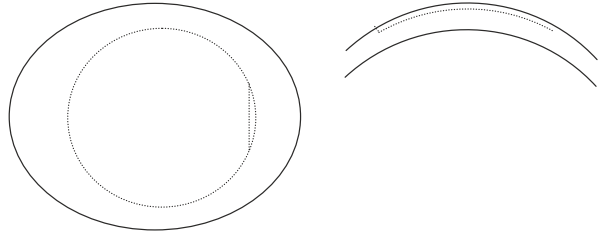
The different fixating rings of the microkeratome and FSL come in different sizes to fit a certain range of corneal diameters and steepness (keratometries). The microkeratom advances until is blocked by a mechanical preadjusted stopper to allow the formation of the hinge. The femtosecond laser is programmed similarly to a desired flap size, depth, form and hinge. A human error may cause a mistake in matching the correct ring to the underlying corneal shape, or a mistake in defining the FSL parameters for the specific cornea and may also lead to irregular flap.

## **Types of Flap Malformations**

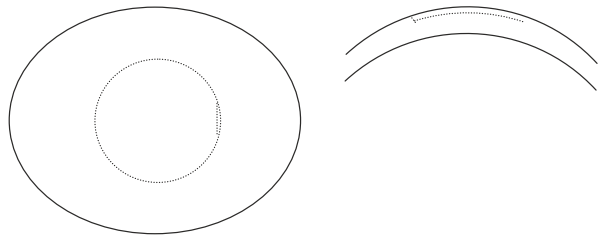
Several abnormalities in flap shape and position may be defined. An irregular flap may have a combination of these malformations (Diagrams [7.1](#), [7.2,7.3](#), [7.4](#), [7.5](#), [7.6](#), and [7.7](#)):

1. Small flap: The flap is smaller than 7 mm in diameter and does not cover the entire intended ablation zone.
2. Decentered flap: The flap is not co-centered on the center of the intended ablation zone. Typically a temporal decentration of the flap causes the hinge to enter the nasal intended ablation zone. In most eyes the pupil center lays nasally to the

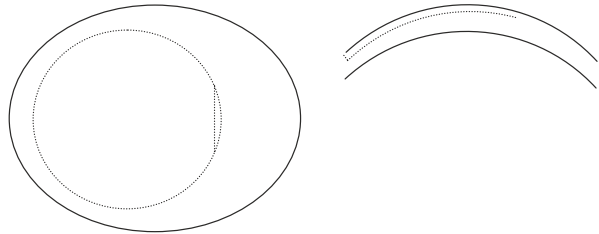
**Diagram 7.1** Regular Flap  
(nasal hinge)



**Diagram 7.2** Small Flap  
(nasal hinge)



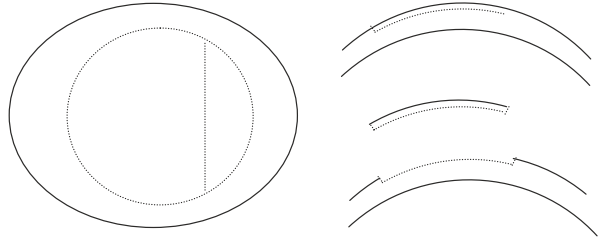
**Diagram 7.3** Decentered Flap  
(nasal hinge)



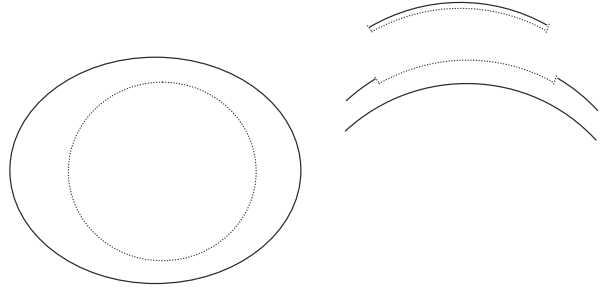
geometric center of the somewhat oval corneal limbus. The correct flap must be large enough to exclude its hinge from the ablation zone and allow some play-room for mild decentrations.

3. Incomplete (short) flap: The cutting of the flap stopped too early before reaching the intended hinge position. Lifting an incomplete flap will not expose enough stromal bed for the intended diameter of ablation. The incomplete flap could be fully separated from the underlying stroma, i.e. hinge less, defined as a free incomplete flap.
4. Free flap: The opposite of a short flap. The flap was completely cut as a full circle without a hinge and is not attached to the underlying cornea.
5. Torn flap: The flap was cut into two or more parts that are not connected or partly connected to each other. It may be caused when the vacuum ring loses its fixation

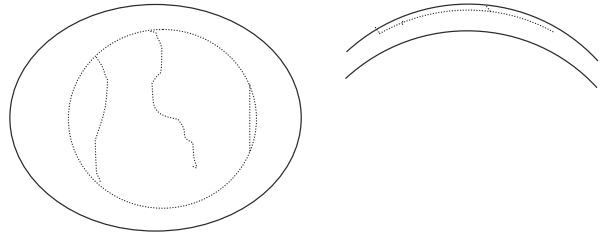
**Diagram 7.4** Incomplete Flap (nasal hinge) and incomplete free flap (no hinge)



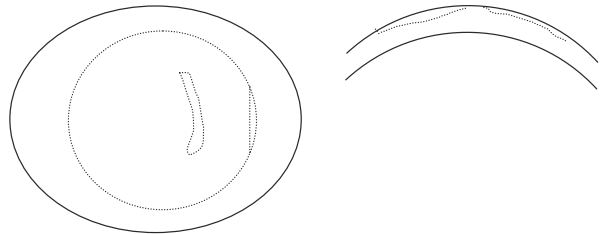
**Diagram 7.5** Free Flap (no hinge)



**Diagram 7.6** Torn Flap (nasal hinge)




**Diagram 7.7** Button hole Flap (nasal hinge)



to the eye while the cutting continues. All FSL and microkeratoms include a safety mechanism that is supposed to stop the cutting in case of vacuum loss. The FSL flap is more prone to flap tear than MK flap because the thinner flap should be bluntly dissected and pulled off from the lasered stromal bed [1]. Vacuum loss and free flaps are more common in flat corneas with less than 42 D of keratometry.

**Fig. 7.8** A typical scar caused by buttonhole of the flap



6. Button hole flap: The flap has a hole, typically elongated triangular or crescent shaped (Fig. 7.8) through the full flap thickness (full button hole) or through the stroma and Bowman's membrane sparing the overlying epithelium (imminent or occult button hole). It is caused when the cutting blade was not held in the intended constant depth under the superior corneal surface, for example by vacuum loss, or in FSL spontaneously when the expanding gas bubbles penetrate through a weak point in the overlying flap stroma (vertical gas breakthrough). Penetrating the Bowmanns' layer with or without epithelial perforation leads to haze, scarring, epithelial ingrowth and irregular astigmatism with loss of DCVA and visual quality. The risk for button hole is higher in pivoting MK and in corneas steeper than 46 D. in both MK and FSL button hole risk is higher in thinner than 100  $\mu\text{m}$  flaps. Preoperative scars or breaks in Bowmanns' membrane such as following previous radial keratotomy increase the risk for gas bubble induced flap perforation using the FSL. A button hole within the optical zone is much worse than a hole outside the ablation zone [2].
7. Opaque Bubble Layer (OBL): this FSL-specific complication occurs when the raster energy is too high producing excessive gas or when the venting pocket is not open enough. The  $\text{CO}_2$  gas accumulate in the stroma and dissects it in unwanted directions thus preventing a safe dissection of the FSL flap. Alternatively can these gas bubbles penetrate the flap causing a button hole or penetrate the stromal bed into the anterior chamber (cavitation bubbles). The cavitation bubbles obscure the tracking of the pupil or the iris reference points during the following Excimer ablation.

In a retrospective analysis of pivotal MKs Flaps (Hansatom, Moria M2) the incidence of button hole was 0.41 % and of imminent button hole 0.15 %. In 10/15 eyes the planned flap thickness was 180 or 200  $\mu\text{m}$ .

In a retrospective case series of FSL vs. MK created flaps [3] the incidence of decentered flaps (0.1 % vs. 0.6 % respectively), suction loss causing incomplete flaps (1.1 % vs. 0.9 % respectively), free flap (both 0.4 %) and button hole (0.3 % vs 0.8 % respectively) did not differ significantly between FSL and MK.

Not all MKs are the same. They differ in their movement pattern (speed, pivotal or linear), in their planned flap thickness, suction apparatus and rings sizes. A learning

curve for complication free flap creation is unique for every MK. Testing seven different Mks by the same surgeon produced different complications (Table 7.1: complications of different microkeratomes). A thin flap was defined as clinically too thin looking flap compared to the targeted 100  $\mu\text{m}$  thickness but without a button hole. One should be aware of the relative small number of flaps produced and the short experience with each model other than the M2. Interestingly, the linear Moria SBK MK in the learning curve did not produce severe flap malformation like button hole but did produce more free flaps compared to the often used pivotal M2 MK of the same manufacturer.

Using a linear manually driven MK (Moria LSK one) in 315,256 Lasiks by 84 surgeons in 19 centers in Spain button hole occurred in 137 eyes (0.043 %) [4].

Per data from a chain of refractive surgery centers in Germany using a linear MK with planned 90  $\mu\text{m}$  flap thickness (Moria SBK) in consecutive 49,467 Lasik procedures performed between 2009 and 2015 the incidence of mild and clinically insignificant complications was 1490 (3.0 %) from which 198 (0.4 %) had epithelial erosions or detachment and 1292 eyes (2.61 %) had limbal hemorrhage. The incidence of irregular flaps which indicate abortion of the ablation was 82 eyes (0.17 %) from which 18 eyes (0.04 %) had a wide hinge close to the nasal ablation zone, 30 eyes (0.06 %) had incomplete flap, and 22 (0.04 %) had free incomplete flap. A button hole occurred in 12 eyes (0.02 %).

Another 97 eyes (0.2 %) had a full size free flap which allowed Excimer ablation in 95 eyes. (Hamburger refractive Data Base, not published data).

Such complications are also reported with FSL. FSL flap may be incomplete due to loss of suction. Suction loss appears in 4.4 % of FSL (Visumax) and in 0.2–0.8 % with Intralase FSL.

## How to Avoid Flap Malformations?

Since flap malformations are caused by a mechanical failure or human error of the surgeon it may be minimized by a thorough standard pre check of your data and instruments. The following tips may be helpful:

1. Avoid LASIK in high risk corneas and patients: corneas smaller than 11 mm, flatter than 38 D or steeper than 50 D are high risk for vacuum loss and flap malformations. Uncooperative patients, very deep set eyes or narrow lid opening are prone to vacuum loss.
2. Avoid FSL flaps in pre-operated or scarred corneas, or after radial keratotomy
3. Use the correct vacuum ring/docking size for the corneal keratometry and hinge size according to the manufacturers' instructions. Do not exceed the FSL raster energy above the minimum needed for flap dissection.
4. Use color marking on the mid peripheral cornea that will guide you by repositioning the flap.
5. Test your microkeratom and FSL before surgery: correct vacuum test, barrier free vacuum tubes, clean vacuum rings and FSL interface, undamaged microkeratom blade and correct setting of ring and hinge size belong to the routine surgical protocol.



**Table 7.1** Complications of different microkeratomes

	Button hole	Incomplete flap	Free flap	Eccentric flap	Thin flap	Macrostromia
Moria OUP SBK	0/157	0/157	2/157 1.3 %	2/157 1.3 %	3/157 1.9 %	3/157 1.9 %
Wavelight rondo	0/91	0/91	0/91	1/91 1.1 %	1/91 1.1 %	0/91
Gebauer SL	0/32	0/32	1/32 3.1 %	2/32 6.3 %	0/32	7/32 21.9 %
Schwind pendular	3/422 0.7 %	2/422 0.5 %	0/422	0/422	9/422 2.1 %	7/422 1.7 %
Moria M2	15/6513 0.2 %	6/6513 0.1 %	4/6513 0.1 %	5/6513 0.1 %	9/6513 0.1 %	37/6513 0.6 %

6. Assure clean surface for fixation ring and docking application: the surgical field must be free from obstruction of the lid opener, eye lashes, lid glands excretions and loose epithelium.
7. Test your vacuum after fixation and before cutting with the following clinical signs:
  - (a) The eye may be pulled with the vacuum ring without losing vacuum.
  - (b) The vacuum negative pressure is constant and in manufacturers' range.
  - (c) The eye pressure is high by palpation.
  - (d) The patients reports loss of vision during suction.
  - (e) The pupil does not react to light.
8. Warn the patient before cutting start to stay calm
9. Follow the cutting carefully through the operating microscope for abnormalities.

## Complication Management: Intra Operative Treatment of Flap Malformations

The first step of treating flap malformation is to diagnose its existence. There is a clear difference between FSL -induced and microkeratom- induced malformations: FSL flap irregularities are more difficult to identify but easier to manage than microkeratom flap irregularities. As mentioned earlier, the FSL does not separate the flap from the underlying stromal bed completely. The freshly prepared flap is connected with tissue bridges to its roots. At this stage, a button hole, a flap tear or a missing hinge is difficult to visualize within the bubble layer of the FSL. Such complications are often first discovered when the surgeon attempts to break the tissue bridges and lift the flap up. If the malformation was discovered by careful evaluation before the FSL Flap was lifted, the management of this complication is very simple: **the FSL-flap should not be lifted and the Excimer ablation should be aborted.** The FSL-flap tissue is stabilized by the tissue bridges and left to heal under local therapy.

One advantage of the FSL is that a re-cut using the same suction ring and same depth may be repeated immediately. The multiple raster passes do not cause an irregular stromal bed or intersection of the cutting planes and may be consecutively attempted. If the suction fails again or the overlying epithelium loses its integrity the procedure should be aborted. A few weeks later a re-cut or a surface ablation technique may be attempted [1].

In the event of opaque bubble layer it is advised to postpone the surgery for >30 min, after which the gas bubbles should absorb spontaneously and a clear cornea and pupil view allow flap dissection and Excimer ablation as planned.

A microkeratom-flap malformation may also be diagnosed before the flap was lifted. One can easily identify the size and position of the flap and hinge. A free flap is easy to identify as the stromal bed is bare and the flap hides somewhere on the microkeratom (Figs. 7.9 and 7.10). Very experienced surgeons may see a button hole without lifting the flap. The disadvantage here is that the malformed flap is fully separated from the stromal bed and is pulled and squeezed by the forward and backward movements of the microkeratom, hence losing its original orientation. After lifting a seemingly regular flap and before starting ablation one must scrutinize the stromal bed. Evidence of shiny islands on the stroma indicate Bowman's membrane perforation and an imminent button hole. A FSL malformed flap that was already dissected and lifted has similar disadvantages.

Managing a malformed flap has four simple rules:

- (a) Reposition the flap in its original anatomical form and position
- (b) Avoid excessive manipulation, rinsing and moving the damaged tissue
- (c) Stabilize the flap by allowing to dry in position and protect with a therapeutic contact lens
- (d) Abort the Excimer ablation to a later time

A single exception to these rules is the free flap. If the free flap is except for the lack of hinge of regular size and position, and is properly marked, the ablation may take place as originally planned, and the free flap may be repositioned and stabilized with drying and applying a therapeutic contact lens. (Figs. 7.11, 7.12, 7.13 and 7.14). When the surgeon does not trust the stability of the free flap, a corneal suture may be used as an artificial hinge.

## Complications of Flap Malformations

If the irregular flap was not properly adapted or was not recognized as irregular and erroneously followed by Excimer ablation, it will end with very irregular surface, scarring of the interface where the Bowman layer was ablated (Haze), high risk for epithelial ingrowth (EIG) in the interface and flap stroma melting. The overlying epithelium will gradually mask some of the surface irregularities but the end result of wrong management of irregular flap is commonly stromal haze and flap melting causing irregular astigmatism and low DCVA [3] and low visual quality (photophobia).

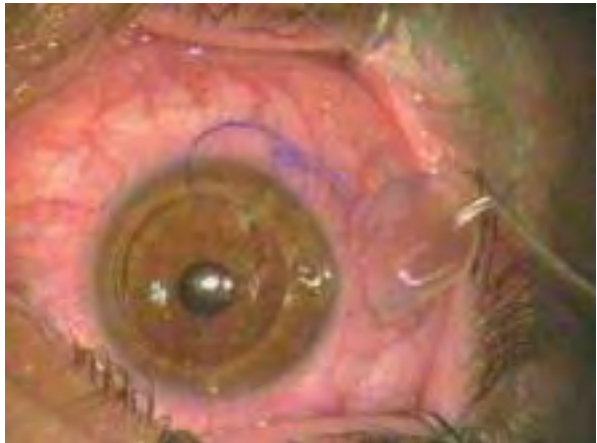**Fig. 7.9** A careful examination reveals the free flap edge in the microkeratome head



**Fig. 7.10** The free flap should be carefully detached from the microkeratome head...



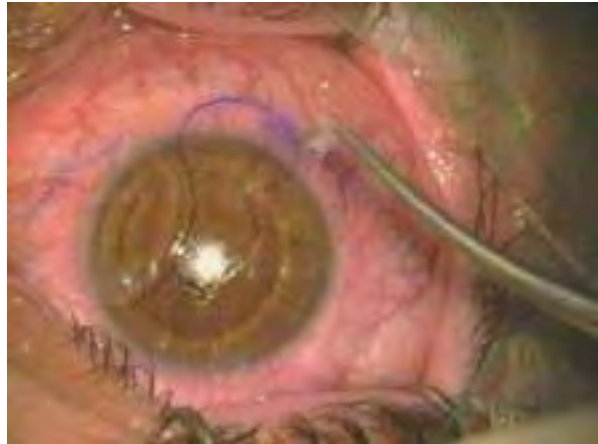**Fig. 7.11** ...and repositioned on stromal bed according to precut markings



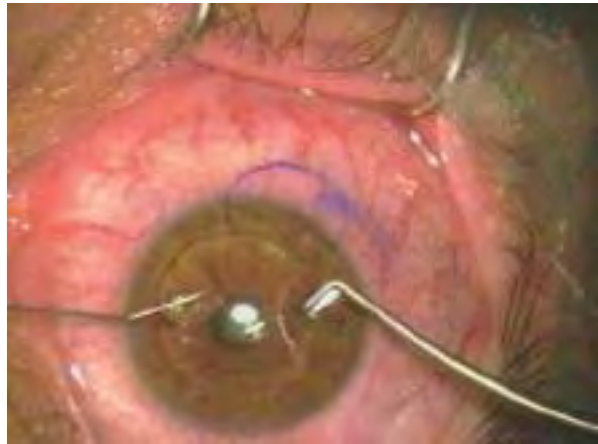**Fig. 7.12** A free flap found on a manually driven 130µm microkeratome



**Fig. 7.13** The free flap is repositioned after excimer ablation



**Fig. 7.14** The free flap is repositioned and stabilized during interface washing



## Late Management of Flap Malformations

Obviously all patients should have received a detailed explanation about possible flap complications, among others, before the first procedure and give their informed consent. After a flap complication has happened many patients will look for a re-treatment not involving a keratectomy or refuse any surgical procedure at all. The surgeon must find ways to reach the mind and heart of the skeptic sometime even non cooperative patient at this stage. The successful management of flap complication may take multiple examinations and surgical steps over several months and is cumbersome for the patient as well as for the surgeon. It is of utmost important to gain the trust of the worried patient and keep him or her in the follow up plan.

Do not hesitate to consult colleagues who are cooperative and may have more experience or technical means such as **topography based ablation** to help you in this difficult time.

After several weeks of healing, in the presence of stable refraction and the absence of EIG, the surgeon should assess the irregularity of the cornea and the difference between UDVA and DCVA before attempting another treatment. As a rule of thumb the cutting plane of irregular flap is per definition contraindicated for Excimer ablation. The surgeon should consider creating a new deeper cut with MK or FSL if the corneal thickness allows, or use a surface ablation. Removing the epithelium before surface ablation should be done very gently to avoid reopening the irregular flap interface.

In case of incomplete free flap or button hole one may avoid mechanical alcohol assisted scraping of the epithelium but rather use the Excimer laser in PTK mode to remove the epithelium and possible Bowmann scarring, and continue with the refractive PRK (“no touch technique”). MMC 0.02% should be applicated for 30–45 s to avoid additional haze in the presence of already activated keratocytes. A very irregular keratometry with low DCVA post irregular flap should be tested with a hard contact lens and over refraction. If spectacle corrected DCVA is much lower than hard contact lens corrected DCVA a regular PRK will not yield the desired result, but rather a topography assisted ablation to reduce the corneal irregularity. Following an improvement of spectacle corrected DCVA a PRK is often needed a few months later as a next step.

The post operative management of the resultant irregular astigmatism is described later in chapter “photo-therapeutic and topography based ablations”.

## End Results of an Irregular Flap

Fortunately most corneas treated according to the correct schema end up with a clear looking cornea, minimal ammetropia and acceptable DCVA. This may take though several months or even years. These eyes should be examined periodically to exclude late Haze and EIG.

In a retrospective comparison of DCVA after MK or FSL flap complications reached 80% of the complicated eyes in both MK and FSL who were retreated a DCVA of 0 LogMAR or better and 100% a DCVA of 0.3 LogMAR or better.

In the large retrospective analysis [4] of the 315,219 LASIK eyes from Spain the 137 eyes with button hole 88 eyes were retreated with re-cutting a deeper flap, and 35 with surface ablation. As common in such cases 14 eyes did not show up for re-treatment after the button hole. The end visual results were very good with LogMAR UDVA in the myopic eyes treated with re-cutting or PRK of  $0.07 \pm 0.11$  and  $0.13 \pm 0.23$  respectively, and DCVA of  $0.03 \pm 0.05$  and  $0.05 \pm 0.09$  respectively. Re-treatments for hyperopic button hole yielded a bit lower UDVA and DCVA. The author mentions that PRK produced a bit worse results than Re-Cutting. This may be because worse scarring and deformation through Button hole should be treated with PRK.

In summery irregular flaps may be caused by technical failure, mismatch between the FSL or MK and the eye, preexisting corneal pathology or poor patient collaboration. When identified correctly intraoperatively they may be successfully managed intraoperatively and by additional procedures with good final efficacy and safety. Every refractive surgeon should be able to identify such complications in time to avoid collateral damage.

## Epithelial Erosions

Epithelial erosions due to flap creation may be caused by the pressure of the aplanation of FSL plate, by the friction of the moving microkeratom over the cornea, by scratching the cornea with lid opener, marking tool, or any surgical tool, or while repositioning an edematous flap. The following conditions are prone to epithelial defects during LASIK and a surface ablation should be considered:

1. Epithelial basal membrane dystrophy or recurrent erosions syndrom
2. Dry eyes
3. After excessive application of Conjucaine eye drops
4. By non cooperative patient
5. By deep set eyes or narrow lid opening

Epithelial erosion during the keratectomy is more common than other intraoperative keratectomy related complications but luckily is easy to solve and rarely cause a permanent damage. Mechanical microkeratoms produce more epithelial erosions than FSL (while FSL produces more DLK) because of the mechanical friction of the moving plate compressing the cornea. Most erosions are seen close to the hinge. Bigger erosions and erosions that involve the central flap have more risk of haze, scarring and DLK within the optical zone. In a retrospective analysis 2.6% of 839 eyes treated with a microkeratome (Hansatom, superior hinge) and 0.6% of 902 eyes treated with FSL (Intralase FS60) had epithelial erosions ( $p=0.0006$ ) [3]. It was suggested that pivotal microkeratoms produce more shear forces than linearly

moving MK and cause more erosions. Our experience with pivotal (Moria M2) and linear (Mosia SBK) MKs support this impression.

In order to reduce the risk of epithelial erosions it is advisable to rinse the eye with BSS just prior to engaging of the FSL docking or the Microkeratom fixation ring, and to reposition the flap gently using a sponge or a blunt instrument.

If an epithelial erosion does occur one have to make sure that the flap Bowmann and stroma are intact and not to confuse a central epithelial erosion with a misdiagnosed button hole. The epithelial flap may be repositioned and allowed to dry. A therapeutic contact lens should cover the erosion. If Bowman's layer is not broken the regular post Lasik therapy may be used with additional lubricants.

## Consequences of Epithelial Erosions

Normally the epithelial erosion heals without permanent effect of the results of the lasik. It may however cause several problems:

1. The loose epithelial tissue may cause during FSL or microkeratom flap cutting an irregular flap.
2. An epithelial erosion in the flap center has a thickness of about half of the flap thickness and may cause flap stria, DLK and stromal haze.
3. In dry eyes and basal membrane dystrophy eyes the erosion may evolve to a persistent epithelial erosion or to a recurrent erosion syndrome.
4. During the short postoperative healing the erosion causes pain, light sensitivity and decreased vision.

In summery epithelial erosions during LASIK are a minor complication that normally heal spontaneously within days. It must be followed for at least 1 week to exclude the rare secondary complications.

## References

1. dosSantos M et al. Femtosecond laser-assisted LASIK flap complications. *J Refract Surg.* 2016;32(1):52–9.
2. Harissi-Dagher M et al. Laser in situ keratomileusis buttonhole: classification and management algorithm. *J Cataract Refract Surg.* 2008;34:1892–9.
3. Moshirfar M et al. Laser in situ keratomileusis flap complications using mechanical microkeratome versus femtosecond laser: retrospective comparison. *J Cataract Refract Surg.* 2010;36:1925–33.
4. Llovet-Osuna F et al. Buttonholes in 315,259 LASIK procedures. *J Emmetropia.* 2013;4:145–51.

# Chapter 8

## FemtoLASIK Intraoperative Complications

Theo Seiler

### Keratotomies

Refraktive keratotomies performed either with blades or with the femtosecond-laser are performed in the cornea for two purposes: (1) surface-parallel keratotomies for lamellar keratoplasty, LASIK or SMILE and (2) surface-perpendicular keratotomies to alter the mechanical stress pattern within the corneal stroma.


Compared to the blade the femtosecond-laser has advantages and disadvantages. A clear advantage of the femtosecond-laser incision is its geometrical precision of the cut which is the order of micrometers. Another advantage is that the cuts are not necessarily ending at the surface of the cornea but leaving an intact corneal surface without entrance ports for germs. A general disadvantage is the cut quality with smoother edges of surface-perpendicular cuts when using blades or diamond knives. In surface-parallel cuts there is not much difference between the cut quality of femtosecond-laser and blade keratotomies because of the dissection mechanism of the two instruments. With the femtosecond-lasers the optical brake-down itself occupies only a small volume of tissue (typical micrometer), however, the following cavitation bubble expands hundreds of micrometers and dissects mechanically a much larger area. Since we consider the corneal stroma as a lamellar structure the dissection due to cavitation gas happens along the lamellar borders because there is less resistance. This dissection modus creates a minimal surface roughness which is greater compared to that of microkeratome cuts. The size of the cavitation bubbles is closely related to the energy of each laser pulse as seen in Fig. 8.1 where surface-parallel keratotomies during a SMILE-procedure are displayed for three different laser systems. The pig corneas were fixated in glutaraldehyde immediately after the femtosecond-procedure and, therefore, the gases of the cavitation bubbles (water

---

T. Seiler, MD, PhD  
Institut für Refraktive und Ophthalmologische Chirurgie, IROC, Zurich, Switzerland  
e-mail: [theo@seiler.tv](mailto:theo@seiler.tv)



**Fig. 8.1** Gas formation after fs-keratotomies for SMILE of -5D (Courtesy Dipl. Ing, Chr. Wüllner). The pulse energies were 800 nJ, 150 nJ, and 50 nJ



vapor and  $\text{CO}_2$ ) did not have time to dissolve or escape. For pulse energies in the order of microjoules these cavitation bubbles may become huge which does not support the precision and homogeneity of the cut. With the application of several tens of nanojoules these cavitation effects are significantly reduced.

Currently we have two different optical approaches in femtosecond-laser surgery of the cornea (1) femtosecond-laser systems with a small aperture and a large focus length/working distance and (2) systems with a big aperture and consecutively a small focus length/working distance. Femtosecond-lasers with a small aperture need pulse energies up to several microjoules and the repetitions rates vary from 30 to several hundred kHz. Laser systems from Intralase, Zeiss, Wavelight and Bausch & Lomb belong to this group. Lasers of the second group, high aperture but small focus length can work with pulse energies of less than 100 nanojoules because the volume of the focus is much smaller which needs less energy for optical breakthrough. On the other hand, these femtosecond-laser systems work with much higher repetition rates compensating for the smaller efficiency per pulse due to smaller cavitation bubbles. Currently this technique is used only in the systems of Ziemer.

Radial keratotomy (RK) for myopia was probably the broadest application of surface- perpendicular keratotomies in the history of ophthalmology. Starting from the early experience of Sato in Japan the radial keratotomy technic was refined by Russian surgeons (e.g. Fiodorow) and was clinically widely used in the UDSSR but

also in some other countries of East Europe. Although the Russian colleagues used radial keratotomies in millions of patients, long term follow-up of a prospective study was never presented. This privilege was reserved to American colleagues when by the end of 70tees RK swapped over to the USA. The academic ophthalmology reacted by means of a prospective study (PERK-Study, Prospective Evaluation of Radial Keratotomy) where hundreds of patients were followed up to 10 years after radial keratotomy [1]. In this study two aspects were highlighted: although a myopia correction was achieved in nearly every case the predictability of radial keratotomy was insufficient and, even more important, the flattening effect of RK was not stable. Up to 50% of the study population suffered from so called “progressive hyperopia” and developed even years after radial keratotomy a constantly increasing flattening effect. Obviously the weakening of the biomechanical strength of the cornea was at least in half of the cases irreversible. After publication of this study by the end of the 80tees radial keratotomy was worldwide considered obsolete and the technique was widely replaced by excimer-laser ablation of the cornea.

Two reasons were made responsible for the lack of precision and predictability of radial keratotomy: first, the geometrical precision of the keratotomies was insufficient because the applied manual indentation-pressure of the RK-blade plays an important role for the depth of the cut and second, the action of those keratotomies depends strongly on the preexisting tension pattern inside the corneal stroma. Where else the first reason could be minimized by better knives with micrometer-screws and preoperative ultrasound pachymetry, the second argument remains still today unknown. Only during the last 2 years an in-vivo-detection of mechanical moduli of the cornea was available by means of Brillouin-spectroscopy. Similar arguments are used in the discussion of predictability of astigmatic keratotomies (limbus parallel relaxing incisions) which are also plagued with poor predictability.

## **Relaxing Keratotomies Using the Femtosecond-Laser and Its Complications**

The relaxing keratotomy consists of deep limbus-parallel incisions and intends a significant reduction of the surface parallel stress in the meridian perpendicular to the cut. This can be seen postoperatively by a discrete gaping of the tissue. Due to this gaping the length of the meridian increases and, therefore, the curvature decreases: a flattening effect in the meridian perpendicular to the keratotomy. Again the predictability of this technique is limited because of the limited precision of the geometry of the cuts and the unknown tension pattern inside the corneal stroma. When using the femtosecond-laser for relaxing incisions the first error of this technique, the lacking precision, can be overcome, because the geometrical parameters length, localization and depth of the cut are much better compared to cuts with a knife. Therefore, we were hoping that relaxation incisions with the

femtosecond-lasers were more predictable compared to the astigmatic keratotomies with a diamond knife and that is why nearly all femtosecond-laser systems on the market, also those for cataract surgery, have the option of limbus parallel relaxing incisions.

In modern femtosecond-laser systems the maps of a Scheimpflug- or OCT-tomography can be imported and the software finds the two steep hemi-meridians. These meridians are not necessarily opposite to each other and, therefore, the two arcuate incisions may be set in a non-symmetric manner. Regarding the geometrical parameters depth and length of the incisions, the results of the femtosecond-laser operation are excellent and are significantly better compared to manual incisions. A new advantage of femtosecond-laser incisions is the “offset” where the incision does not reach to the surface of the epithelium and, therefore, the anterior surface is not penetrated. Using this offset we have to plan whether the keratotomy ends within the epithelium (offset < 40  $\mu\text{m}$ ) or ends below Bowman’s membrane (offset > 60  $\mu\text{m}$ ). Because Bowman’s membrane is considered one of the biomechanically strongest parts of the cornea a non-incision of Bowman’s leads to a smaller optical effect. On the other hand, if the epithelium remains closed there is no entrance port for infections. Since the advent of femtosecond relaxing incisions several new nomograms have been established which resemble the old (manual) nomograms very much. In Table 8.1, one of the clinically validated nomograms is presented, the nomogram of Julian Stevens [2] for two symmetrical keratotomies. In addition to the here presented nomogram the Moorfields-group uses some small modifications regarding the age of the patient and the position of the steepest meridians. Although these modifications may increase the predictability of the outcome the precision clinically achieved is rather limited.

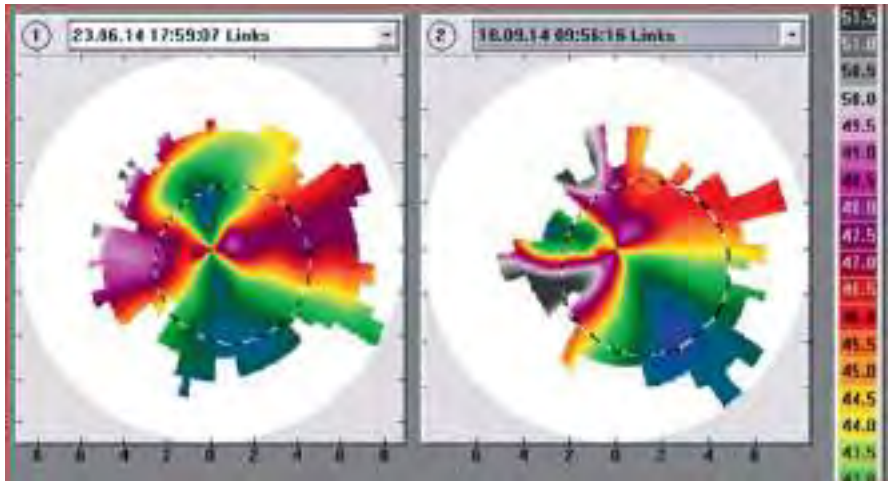
This nomogram is valid only for virgin corneas which mean corneas without earlier operations or trauma. Astigmatic keratotomies are also used for congenital astigmatism up to 3 diopters but the most frequent application is for astigmatism after cataract operations.

In contrast, high astigmatism after keratoplasty is a totally different scenario where astigmatism-changes up to ten diopters can be induced by simply one incision. In Fig. 8.2 such a case is depicted and with only one incision of 30° length around 10:00 a change in astigmatism of more than seven diopters was achieved, by the way, more than attempted.

In addition, this one keratotomy induced irregular astigmatism. In such cases a significant overcorrection gaping incisions need to be readapted by one single

**Table 8.1** Symmetric intrastromal arcuate keratotomies between 20 and 80% local depth and a diameter of 8.0 mm

Astigmatism/D	Arc length/degree
Up to 1.0	25 bis 30
1.0 to 1.5	40 bis 50
1.5 to 2.0	60
2.0 to 2.5	70
2.5 to 3.0	80 bis 90



**Fig. 8.2** Corneal topography pre- and postoperative after one relaxing keratotomy (30°, centered on the 160°-meridian, state after DALK). One month after AK we saw a gaping incision and a significant over correction

suture. Such cases lead us to the position that keratotomies after keratoplasty may be considered as kind of “on stage-surgery” and we start today with a very short cut of only 2 mm inside the graft making this cut longer if necessary. This elongation has to be done manually with a diamond knife. A re-deepening of the cut cannot be recommended because the depth of the femtosecond-laser cut is much more predictable compared to any manual incisions. This “on stage-surgery” is necessary because we have no information about the stress pattern in the transplant and across the graft-host interface. The first results of Brillouin-spectroscopy are very promising in giving us a rough estimation of the biomechanical stress pattern in the cornea. Since this is an in-vivo measurement it would have a huge impact on the application of keratotomies. Currently we are granted with an ultra-precise instrument to perform keratotomies, however, the action power of these ultra-precise and predictable keratotomies is poor because of the lacking knowledge about the stress situation inside the cornea.

Besides significant over- and under-corrections also other complications of femtosecond-keratotomies are reported. In the literature anecdotally cases with infections of the cornea and even endophthalmitis have been presented. This is the reason why we treat eyes after femtosecond-laser keratotomy during the first night after surgery with a bandage contact lens that is loaded with antibiotics (ofloxacin without preservative). Usually next day the epithelium is healed and additional antibiotic treatment is not necessary. Another complication is the perforation of the keratotomy which leads to a gas bubble in the anterior chamber and is, therefore, easily detected. The epithelium is usually not incised because of the offset and, therefore, no additional treatment is necessary. However, at the site of perforation at the level of the Descemet’s membrane scarring may occur leading to irregular

astigmatism. Since approximately 4 years we attempt a local keratotomy depth of 80% (total thickness at the OCT) and since then we have not seen any perforations.

The cavitation gas inside the keratotomy cannot escape and forms a gas bubble which allows to detect potential tissue bridges. Normally this gas bubble is crescent shaped (Fig. 8.3) but in case of tissue bridges indentations can be detected and the surgeon can easily separate those tissue bridges by means of a spatula.

## Preparation of the FSL-LASIK Flap and Its Complications

In the early of the femtosecond era, approximately until 2005, we had many discussions at the scientific conventions whether there is a medical indication of the femtosecond-laser to create LASIK-flaps. In essence, many of us did not see a medical indication for that expensive tool, however, marketing strategies (“no blades – laser only”) created motivations in patients. In addition, this tool was as expensive as 400,000 Euro and because at that time the LASIK-market showed worldwide regression additional investment was critical. The real argument changing the game was the precision of flap-thickness. The generation of LASIK flaps by means of a microkeratome led to a standard deviation of up to 30  $\mu\text{m}$  [3] which was much higher compared to the standard deviation of a femtosecond-laser flap which was in the order of the error of measurement which means at plus or minus 5–7  $\mu\text{m}$  [4]. With those standard deviations a 95% confidence interval (two standard deviations around attempted 130 microns) ranged from 70  $\mu\text{m}$  to 190  $\mu\text{m}$  using a microkeratome but only from 115 to 145  $\mu\text{m}$  using the femtosecond-laser. It is obvious that buttonholes or other cutting errors may occur statistically in up to 2.5% of the cases using a microkeratome. On the other side of the range if the flap is too thick in high corrections the risk of iatrogenic keratectasia increases because the residual stroma



**Fig. 8.3** Intraoperative video picture of intrastromal keratotomies (30° long, 80  $\mu\text{m}$  offset). The inferior keratotomy shows the contraction of the gas bubble

is not thick enough to bear the intraocular pressure after full ablation. Based on the much smaller variance of the femtosecond-laser flap much thinner flaps could be attempted for example the 90  $\mu\text{m}$  flaps (so called sub-Bowman's LASIK), however, this technique was banned as soon as we learned that such flaps may create haze in the interface. Based on all these aspects the femtosecond-laser opened a new dimension of safety of LASIK and that's why the use of femtosecond-laser today is considered to be the "state of the art". The microkeratome manufacturers addressed this precision in the last years with new mechanical "sub Bowman" fully automated linear microkeratomes that produce homogenous flaps of 100  $\mu\text{m}$  thick and comparable standard deviation to that of femtosecond laser flaps.

But there are also femtosecond-laser associated complications of LASIK such as diffuse lamellar keratitis (DLK), cutting errors due to suction loss and the vertical gas break trough. Diffuse lamellar keratitis, in detail stages II and III, are rare conditions after a microkeratome LASIK, however, increase significantly when using the femtosecond-laser. Again, the prevalence of DLK after femtosecond-LASIK was clearly depended on the laser type. When using the femtosecond-laser of Ziemer (Z2) DLK II or III occurred in less than 1 % of the cases. Starting in 2008 we were using a high-energy femtosecond-laser (FS200, Wavelight, Erlangen) which increased the prevalence of DLK II+ to 10 % and more. The explanation for the phenomenon is obvious: the Ziemer femtosecond-laser works with pulse energy of only a few nanojoules per pulse whereas the FS200 works with more than 1 microjoule per pulse. This higher energy leads to more irritation of adjacent tissue due to the bigger cavitation bubbles and may also lead to distribution of the gas into the corneal stroma and may penetrate into the interlamellar space (von Recklinghausen called it the "Saftlückenraum" – juicy spaces). The consecutive transient opacification called opaque bubble layer (OBL) may lead to interruption of the operation because the eye tracker cannot find the pupil anymore. In order to avoid OBLs when using the high energy lasers intrastromal pockets (Intralase) or chimneys (Wavelight) were created in order to get the gas space to escape. Also the transient light sensitivity syndrome (TLS) belongs to this group of complications because due to high energy-induced roughness of the cut may lead to more scattering at the interface but also to stronger healing cascades. The light sensitivity syndrome occurred up to 10 % of the cases and patients needed sunglasses all day long for up to 3 months. All these side effects induced by high energy-pulses have been reduced significantly during the last years because even with high energy-lasers the pulse energy could be reduced to less than 1 microjoule per pulse. Also the use of topical steroids (e.g. loaded in a postoperative bandage contact lens) have reduced the incidence of DLK II+. Since using energies of less than one micron per pulse the transient light sensitivity syndrome has nearly disappeared from the spectrum of complications of LASIK but found resurrection in the current SMILE procedure.

Suction loss and consecutive cutting errors are rare complication because most femtosecond-laser systems have a control of the suction pressure. If the suction pressure is not reaching the target level, the cutting process has not even started. False positive suction of the conjunctiva has been reduced by means of columns and walls in front of the suction ports which avoids suction of the conjunctiva mimicking

suction of the sclera. Nevertheless, in one out of 500 cases we saw incomplete cuts due to suction loss and in such cases we are following the old rule: the operation has to be abandoned and may be repeated a few weeks later.

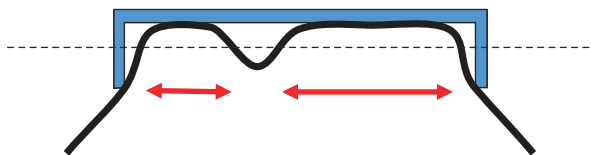
The last femtosecond-laser associated complication is the vertical gas breakthrough [5] when the cavitation gas located in the interface can break through the flap and reach the ablation area. Such a gas bubble force the corneal surface to separate from the ablation area and since the femto-laser itself continues the surface parallel cut a buttonhole may occur (Fig. 8.4).

We have no found published data about the prevalence of such vertical gas breakthroughs and in our practice it happened in less than one out of thousand cases. Reasons for a vertical gas breakthrough are small defects in Bowman's membrane (due to previous foreign body injuries) or just a too thin flap. If during the preoperative examination such a defect of Bowman's membrane is detected it is mandatory to measure the depth of defect by means of the OCT and the attempted flap-thickness should be approximately 40  $\mu\text{m}$  thicker than the depth of the defect. Alternatively a mechanical microkeratome may be used where such a complication is unknown. Once a vertical gas breakthrough has occurred we need to follow the same strategy as in a suction loss case: abandon surgery and repeat a later date. In such reoperations we are always using a mechanical microkeratome or even a PRK.

In summary, femto-LASIK is not just another more expensive type of LASIK but increases the safety of LASIK significantly by minimizing iatrogenic keratectasia due to too thick flaps or cutting errors due to too thin flaps. The new femtosecond-laser associated complications are very rare or can be avoided by means of perioperative medication.

## Keratotomies for Intrastromal Lenticules and Its Complications

To achieve an intrastromal lenticule resection (SMILE) two femtosecond-laser keratotomies are mandatory because a concave-convex lenticule is cut from the middle stroma. The SMILE-technique, proposed by Lubatschowsky in the 90ties, is an intriguing approach and is considered to be surgery of the future in refractive surgery by most of the specialists in the field (including myself). On the other hand the scientifically reliable information about SMILE is rather limited. One of the



**Fig. 8.4** A button-hole may occur if cavitation gas penetrates from the interface into the ablation area and separates cornea from ablation window

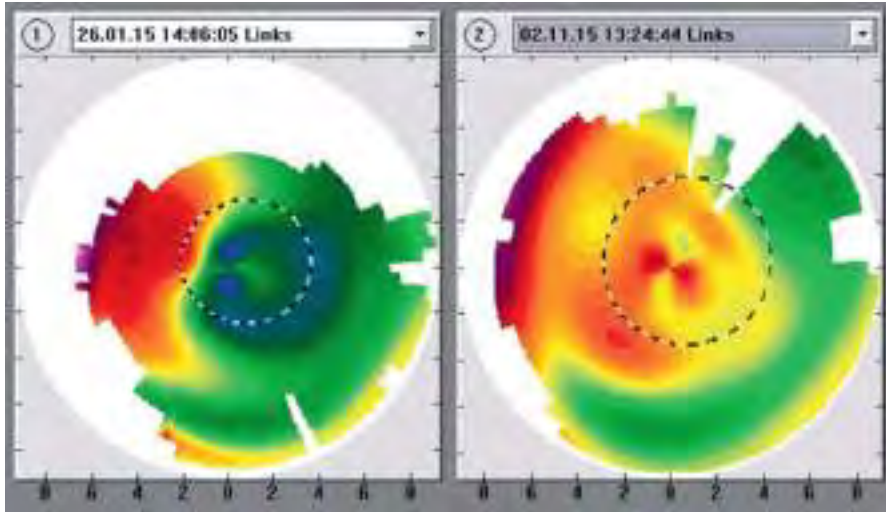
pioneers of SMILE, Dan Reinstein, has reviewed the current situation in 2015 and he concluded “that the potential advantages of the procedure related to improve mechanical stability, postoperative inflammation, and dry eye syndromes have not been fully established” [6]. A newer publication could show that the dry eye problem is significantly less frequent or at least not that intense compared to the situation after LASIK. The refractive success rates after SMILE reported in the literature not are yet as good compared to LASIK but most probably this is due to not yet fully adjusted algorithms which may be achieved during the next years.

The visual rehabilitation after SMILE is clearly not as fast as it is after LASIK and the so called “wow” effect is a rare event after SMILE. Lately we are also seeing patients presenting the transient light sensitivity syndrome. The slow visual rehabilitation as well as the increased photosensitivity during the first 3 months after SMILE is probably explained due to an increased scattering inside the cornea especially at the posterior cut. A Turkish group compared the scattering of the cornea after LASIK and SMILE based on confocal microscopy and found significantly higher scattering after SMILE [7]. At this point the question arises why deeper cuts have a rougher surface compared to relatively smooth surface when using more superficial keratomies like in LASIK. The provider of the SMILE laser (Zeiss) claims that the problem is already minimized by using a curved interface, however, the current interfaces have a curvature-radius of 22 mm which is still deforming the cornea when attached and for geometrical reasons an undulation of the posterior surface must occur. This undulation can be easily seen using an intraoperative OCT. Since the femtosecond-laser keratotomy, however, is a straight forward curved cut and the cornea experience a waviness in the deeper stroma we should not be surprised that wavy and rough surfaces are created which easily explains the phenomena of late rehabilitation and photosensitivity. This problem may be solved in future laser systems using laser patient interface the curvature rate is less than 10 mm which, however, creates new technical difficulties. The z-scan becomes more important when using stronger curved interfaces but the z-scan is also the slowest element in the scanning process. In other words, such a curved interface will automatically lead to a much longer procedure. Also the quality of the cut decreases towards the periphery of the cornea. New systems that are currently under construction that will avoid these problems and we hope that finally get a SMILE-procedure which is as good as the current LASIK.

During the last year we also saw the first SMILE-specific complications, for example a partial resection of the lenticule. In such cases highly irregular astigmatism with a significant visual loss is the consequence (Fig. 8.5). The optimal management of this complication is not yet known and we have used topography-guided PRK to regularize the cornea which has of course the disadvantage of alteration of the biomechanics of the cornea. In another case we could remove the residual lenticule portion with a reversed Sinskey-hook. We have also seen first cases with decentered SMILEs and also such cases need topography-guided PRK.

Although many of us believe that SMILE is the technique of the future, the current approach of SMILE shows clearly that more development of better technical system is necessary to provide a refractive procedure that is as good as femto-





**Fig. 8.5** Cutting error during SMILE. Left: corneal topography 6 months after SMILE; right: 3 months after topography-guided PRK. VA improved from 0.3 to 0.8

LASIK in 2016. The SMILE state of the art is widely described by Drs Hjortdal and Ivarsen later in this book.

## References

1. Waring 3rd GO, Lynn MJ, McDonnell PJ. Results of the prospective evaluation of radial keratotomy (PERK) study 10 years after surgery. *Arch Ophthalmol.* 1994;112:1298–308.
2. Day AC, Lau NM, Stevens JD. Nonpenetrating femtosecond laser intrastromal astigmatic keratotomy in eyes having cataract surgery. *J Cataract Refract Surg.* 2016;42:102–9.
3. Genth U, Mrochen M, Wälti R, Salaheldine MM, Seiler T. Optical low coherence reflectometry for noncontact measurements of flap thickness during laser in situ keratomileusis. *Ophthalmology.* 2002;109:973–8.
4. Yu CQ, Manche EE. A comparison of LASIK flap thickness and morphology between the Intralase 60- and 150-kHz femtosecond lasers. *J Refract Surg.* 2014;30:827–30.
5. Santos AM, Torricelli AA, Marino GK, Garcia R, Netto MV, Bechara SJ, Wilson SE. Femtosecond laser-assisted LASIK flap complications. *J Refract Surg.* 2016;32:52–9.
6. Moshirfar M, McCaughey MV, Reinstein DZ, Shah R, Santiago-Caban L, Fenzl CR. Small-incision lenticule extraction. *J Cataract Refract Surg.* 2015;41:652–65.
7. Agca A, Ozgurhan EB, Yildirim Y, Cankaya KI, Guleryuz NB, Alkin Z, Ozkaya A, Demirok A, Yilmaz OF. Corneal backscatter analysis by in vivo confocal microscopy: fellow eye comparison of small incision lenticule extraction and femtosecond laser-assisted LASIK. *J Ophthalmol.* 2014;2014:265012.

# Chapter 9

## Early (< 3 Months) and Late (> 3 Months) Complications of LASIK

**Stephan J. Linke, Fernando Llovet, Julio Ortega-USobiaga,  
Andrea Llovet, Julio Baviera, Mercedes Martínez-del-Pozo,  
Gonzalo Muñoz, Cesar Albarrán, and Toam R. Katz**

### Early Postoperative Complications (< 3 Months)

Stephan J. Linke

This chapter focuses on early postoperative LASIK complications such as sterile inflammation (e.g. diffuse lamellar keratitis, DLK), infectious keratitis, epithelial or flap folds, epithelial ingrowth (EIG) and dry eye. By definition early postoperative

---

S.J. Linke, MD, PhD (✉)

Department of Ophthalmology, University Medical Center Hamburg Eppendorf,  
Martinistr. 52, 20246 Hamburg, Germany

zentrumsehstärke, Martinistr. 64, 20251 Hamburg, Germany

CareVision GmbH, Martinistr. 52, 20246 Hamburg, Germany

e-mail: [slinke@uke.de](mailto:slinke@uke.de)

F. Llovet, MD, PhD (✉) • M. Martínez-del-Pozo, MD

Department of Refractive and Cataract Surgery, Clínica Baviera, Madrid, Spain

e-mail: [fllovet@clinicabaviera.com](mailto:fllovet@clinicabaviera.com)

J. Ortega-USobiaga, MD, PhD

Department of Refractive and Cataract Surgery, Clínica Baviera, Bilbao, Spain

A. Llovet, MD

Ophthalmology, Centro de Oftalmología Barraquer, Barcelona, Spain

J. Baviera, MD

Department of Refractive and Cataract Surgery, Care-Vision, Frankfurt, Germany

G. Muñoz, MD, PhD • C. Albarrán, OD

Department of Refractive and Cataract Surgery, Clínica Baviera, Castellón, Spain

T.R. Katz, MD, PhD

Department of Ophthalmology, University Medical Center Hamburg Eppendorf,  
Hamburg, Germany

CARE Vision Germany GmbH, Frankfurt/Main, Germany

e-mail: [t.katz@uke.de](mailto:t.katz@uke.de)

© Springer International Publishing Switzerland 2016

S.J. Linke, T. Katz (eds.), *Complications in Corneal Laser Surgery*,

DOI 10.1007/978-3-319-41496-6\_9

**Table 9.1** Overview on early postoperative LASIK complications

Complication	Incidence	Time of presentation	Recommendation
DLK	1–2 %	1st day post operatively	Prevent progression from stage 1 to >2 (steroid treatment)
Infectious keratitis	0.03 %	Early onset <7 days Late onset >3 weeks	Flap lift, culture and irrigation
Striae	0.5 %	1st day post operatively (<3 weeks)	Early flap lift and iron
Epithelial ingrowth	<0.2 %	>3 weeks	Removal of EIG only if symptomatic or secondary flap melt
Dry eye	10–20 %	Any time pre- to post-op period	Recognize risk factors

complication is manifestation within 3 months after the procedure. These early postoperative complications can occur after uneventful surgery and differ significantly in their clinical impact on the postoperative outcome and are therefore introduced separately.

A number of postoperative complications can be avoided or minimized by careful intraoperative management. Focused attention should be paid to infectious keratitis which must be clearly separated from non infectious (diffuse lamellar) keratitis. Especially infectious keratitis can result in severe visual loss if not adequately addressed. The possible complications are listed in the order of their usual time line and summarized in Table 9.1.

## Non Infectious: Diffuse Lamellar Keratitis (DLK)

### *Incidence and Symptoms*

Diffuse lamellar keratitis (DLK) is a rare, multifactorial but unspecific immunological reaction with infiltration of white blood cells between the flap and the stromal cornea following surgical trauma [1, 2]. Exogeneous factors can strongly influence the occurrence of DLK. Sterilization detergents, bacterial toxins on sterilized instruments, handglove powder and remnants from the microkeratome can result in series of DLK [2].

The incidence of DLK shortly after LASIK in the absence of epidemic conditions varies widely and has been reported to be between 0.13 and 18.9 % [2].

Our own analysis included 14,123 treatments performed in CareVision refractive clinics and were retrieved from the Hamburg Refractive Database between 4/2006 and 4/2008. Diffuse lamellar keratitis was diagnosed according to the electronic filing system in 2.28 % [3]. Internal patient factors seem to influence the risk of DLK: anterior basement membrane dystrophy, dry eye, ocular surface diseases (chronic blepharitis) [4], atopy [5] and smoking are correlated with a higher DLK incidence and should therefore be controlled or avoided.

**Table 9.2** Staging of diffuse lamellar keratitis (DLK)

Grade	Clinical characteristics	Incidence	Management	Outcome
DLK 1	Faint incomplete interface infiltration—mainly arising from the periphery. “Sands of Sahara” = SOS appearance, i.e. leucocyte infiltration	1–2 %	Local steroidal eye drops hourly, follow up next day to monitor progression (then flap lift and wash DLK 2)	Complete resolution when immediate intensive treatment
DLK 2	Complete and homogenous interface infiltration	0.1–0.3 %	Flap lift and wash, local steroidal eye drops	Reduced efficacy of laser treatment
DLK 3	Similar to DLK 2, but additional cellular aggregates and irregular topography	Rare, only progression from grade 2	Immediate flap lift and wash, local + systemic steroid treatment	Reduced efficacy of laser treatment and irregular topography
DLK 4	Acute DLK similar to DLK 3, progression from interface to stromal tissue with consecutive stromal melt and “mud cracks”	Very rare, only progression from grade 2 and grade 3	Immediate flap lift and wash for acute DLK, local + systemic steroid treatment. No flap lift for delayed DLK with scarring	Scarring and reduced visual outcome, irregular topography

Increased light sensitivity, tearing, blurred or reduced vision are the leading clinical symptoms of DLK.

There are four clinical stages of DLK as described by Linebarger et al. [6]. The staging and recommended individual therapy is summarized in Table 9.2.

Late onset DLK (>3 months after LASIK) is a very rare and only sporadically reported condition mainly after contusio bulbi. The ophthalmologist should be aware that inflammatory diseases and associated ocular inflammation can trigger an episode of late onset DLK [7].

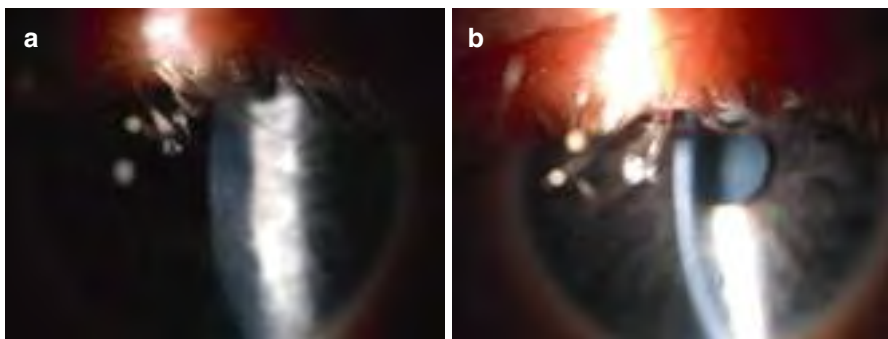
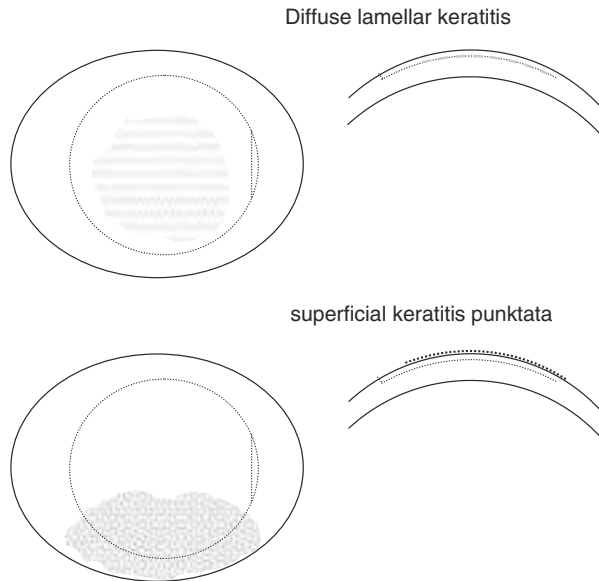
## Management

Due to the advent of thin flap LASIK (90–110  $\mu\text{m}$  flap thickness) and rapid flap adaptation the differentiation between early stage DLK and epithelial irregularity (mainly superficial punctate keratitis–DLK) can be challenging [1]. The original name of DLK “Sands of Sahara” precisely describes the clinical picture of wave-like lines of white, granular inflammatory cells (leucocytes) and deposits within the lamellar interface—often more prominent in the periphery. However SPK induced epithelial irregularity is mainly localized in the inferior third of the cornea due to incomplete eyelid closure during night, whereas DLK is often homogeneously distributed in the central cornea, but originating from peripheral interface. Slit-lamp differentiation between interface located, sand dune like DLK and superficial SPK is mandatory [8]. One can clinically differentiate between SPK and

DLK by staining with fluorescein which stains SPK but not DLK and by their localization relative to the flap border. DLK is always limited to the flap interface and will not mark the cornea outside the flap. SPK does not respect the flap border and often extends between the inferior flap border and the inferior limbus. Figure 9.1 illustrates the difference between DLK and SPK.

Subjective symptoms such as foreign body sensation are even more pronounced in SPK compared to early stage DLK. Interface debris may occasionally mimik DLK, but debris alone will typically remain stable over time and resolve within weeks to months. Figure 9.2 shows typical slit-lamp findings of DLK.

**Fig. 9.1** Schematic drawing of typical DLK and SPK findings in post LASIK patients



**Fig. 9.2** (a, b) Diffuse lamellar Keratitis (DLK) grade 1–2 in both eyes presenting on first operative day

Conservative management of DLK with local steroid treatment is only recommended for grade 1 DLK. Main symptoms of DLK grade >2 are light sensitivity and slightly reduced visual acuity. For grade 2 and more advanced stages the flap should be lifted immediately and irrigated with balanced salt solution (BSS) in combination with intensified local steroid treatment to prevent progression to DLK grade 3. Advanced DLK (grade >3) can result in stromal melting due to extensive cytokine release and consecutive stromal scarring or reduced visual acuity related to irregular corneal topography. I advise to apply a systemic cortisone therapy (1 mg/kg) in severe (grade 3+4) cases of DLK for 10 days. Residual refractive errors can arise from stromal DLK induced modulation of the wound healing cascade [9]. Refractive retreatment for residual refractive errors or irregular topography after DLK should be delayed to >6 months after initial surgery due to temporary structural changes of the corneal stroma during the wound healing response. For DLK grade 4 a necessary retreatment should be postponed for >12 months because of ongoing stromal wound healing reaction. I do recommend to perform a retreatment as a PRK procedure on the flap, since interface scarring and DLK reactivation will complicate a relift procedure.

### *Prophylaxis*

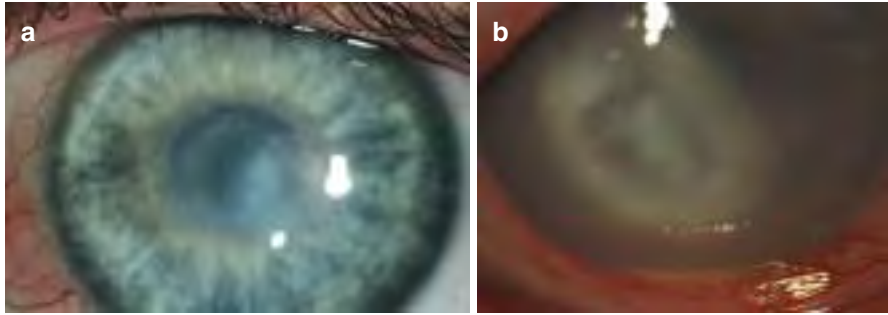
Intraoperative erosio corneae and smoking are correlated with a higher incidence of DLK [2]. Both debris and micropannus induced hemorrhage can trigger DLK and should be intraoperatively minimized. For micropannus related prolonged and aggressive bleeding I recommend the application of a limbal sponge and intraoperative ophthalmic eye drops.

The appearance of DLK can not always be prevented however the progression from early (grade I) to advanced stages must be avoided. A key factor in managing DLK is differentiating superficial punctate keratitis (SPK) from DLK and immediate treatment of DLK with local steroids.

## **Infectious Keratitis**

### *Incidence and Symptoms*

Infectious keratitis must be differentiated from non infectious sterile DLK. According to Price et al. [10] the risk of laser refractive surgery is comparable to contact lens wear regarding safety and side effects. Due to the fortunately low incidence of post-LASIK keratitis, large-scale studies are necessary to obtain valid statistical data. The real incidence of post LASIK keratitis (uni- and bilateral) is difficult to estimate and was calculated with 1:2919 (0.035 %) in a survey by the American Society for Cataract and Refractive Surgery (ASCRS) covering 338 550 surgeries [11, 12]. These data were retrieved from independent surgical centers and 56 surgeons using



**Fig. 9.3** (a, b) Several cases of early onset infectious keratitis

different protocols. Only <66 % of the questionnaires were returned for analysis. This might result in a bias of the reported post LASIK incidence. The majority of keratitis (65.5 %) was classified as early postoperative keratitis. Our own analysis included 14,123 treatments performed in CareVision refractive clinics and data being retrieved from the Hamburg Refractive Database between 4/2006 and 4/2008. Infectious keratitis was diagnosed according to the electronic filing system in 0.087 % [3]. Llovet et al. provide the largest dataset applying one treatment protocol [13] (N=204,586) and calculate the risk of post LASIK keratitis to 1:2841 treatments (= 0.035 %). The same group reported a decrease of incidence of infectious keratitis to 0.011 % when moxifloxacin was added to tobramycin alone in the postoperative period [14]. However the possible increase of antibiotic resistance must be considered. The risk of bilateral infection could until now only be approximated by calculating it from the risk of unilateral infection. Llovet et al. found 9 patients (18 eyes) with bilateral post-LASIK keratitis (0.0084 %) [13].

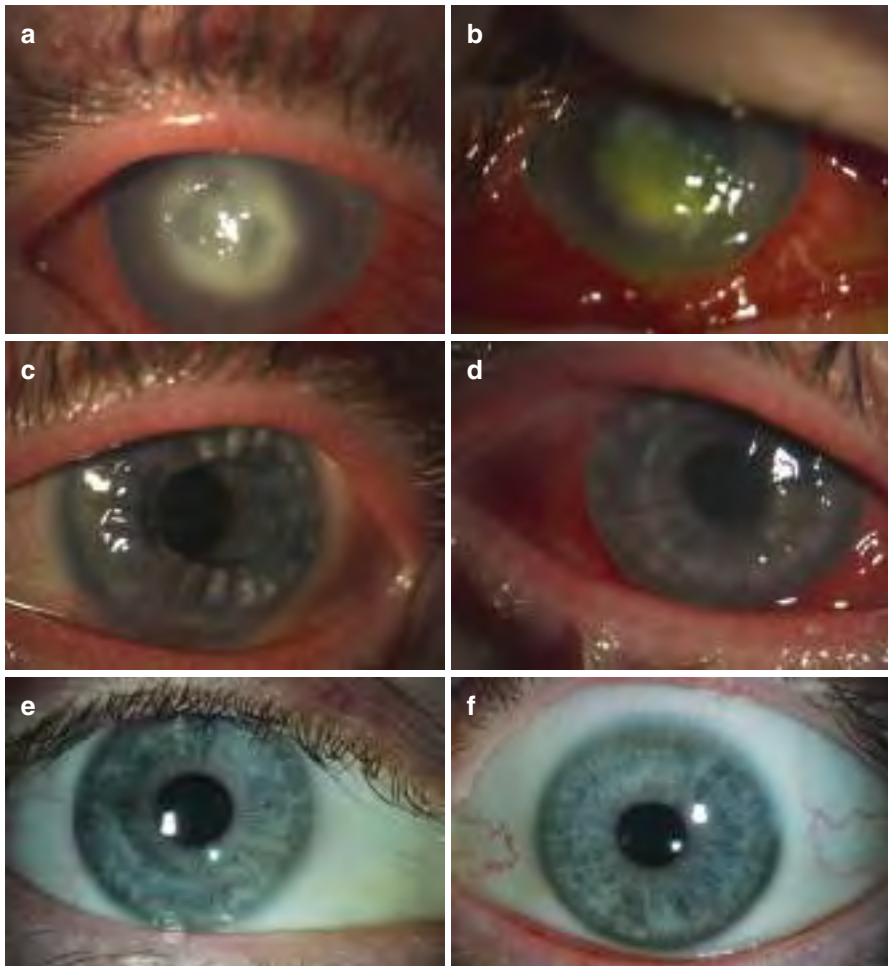Infectious early onset postoperative keratitis rarely manifests before the 2nd postoperative day, whereas DLK mainly manifests on first postoperative day. Due to its nature DLK presents in numerous cases bilaterally, whereas early onset infectious keratitis manifests mainly unilaterally on day 3–4 post surgery with pain, red eye and reduced visual acuity (Fig. 9.3).

Infectious keratitis is a rare but severe complication. Gram-positive bacteria and atypical mycobacteria are the most common causes for microbial post-LASIK keratitis. There is an increasing literature of post-LASIK case reports caused by rare or atypical species [3, 15]. Severe cases of keratitis are more often correlated with a prolonged onset of infection and caused by atypical species.

## ***Management***

Pivotal is timely diagnosis and stage related treatment of keratitis. Early and consequent flap lift, taking of culture specimen and irrigation of the flap interface is essential in preventing permanent visual loss. This approach of early surgical intervention for infectious keratitis is based on my own experience as well as the good visual outcome of the study by Llovet et al. [13]. Therapy for early acute keratitis (<7d post

surgery) consists of irrigation of the flap interface with vancomycin (50 mg/ml) followed by intensive topical therapy with Fluoroquinolon+Cephalosporin. This approach is in line with the ASCRS (“white paper”) recommendation [11]. For sub-acute keratitis the recommended treatment regime is interface irrigation with Amikacin (35 mg/ml) and then intensive topical therapy with Fluoroquinolon+Aminoglykosid. Severe cases are associated with subacute onset and atypical species. We reported a very rare bilateral manifestation 8 weeks after LASIK [15]. The infiltrative keratitis progressed despite immediate flap lift, irrigation and intensive antibiotic therapy. *Achromobacter xylosoxidans* was isolated from culture. Corneal transplants were performed in both eyes due to progressive corneal melting, anterior chamber infiltration and imminent sclera infiltration. Both eyes recovered and 8 years after transplant visual acuity remains stable with a clear corneal graft (Fig. 9.4).



**Fig. 9.4** Atypical post LASIK keratitis presenting bilaterally 8 weeks after LASIK surgery (a, b) and 3–4 weeks (c, d) and 8 years after keratoplasty a chad bilaterally (e, f)



Corneal cross linking is a new option to treat progressive post LASIK keratitis [16, 17]. Although having observed good results in contact lens induced severe keratitis the author can not provide data for CXL for post LASIK keratitis.

## ***Prophylaxis***

Main risk factors for infectious post LASIK keratitis are pre-existing blepharitis, dry eye disease (DED) and reduced compliance. All of these are relative contraindications to LASIK. However reduced compliance is not unequivocally to diagnose before surgery. Treatment of pre-existing blepharitis and dry eye syndrome should be initiated and controlled before laser treatment. Modern techniques such as measurement of tear film osmolarity (TearLab) can objectively quantify the success of treatment and are helpful tools in a modern refractive setting. Careful cleaning of the lidmargin in combination with topical conservative free local antibiotic eye drops and 2 weeks systemic doxycycline cycle may help to improve the lid margin and blepharconjunctivitic state before surgery.

## **Striae**

### ***Incidence and Symptoms***

Flap striae must be divided into asymptomatic microstriae and symptomatic macrostriae. Improper repositioning and flap alignment, eye rubbing and trauma can result in macrostriae. Macrostriae most often appear within 24 h after surgery and can result in irregular astigmatism, reduced visual acuity and disturbing optical quality if untreated [18, 19].

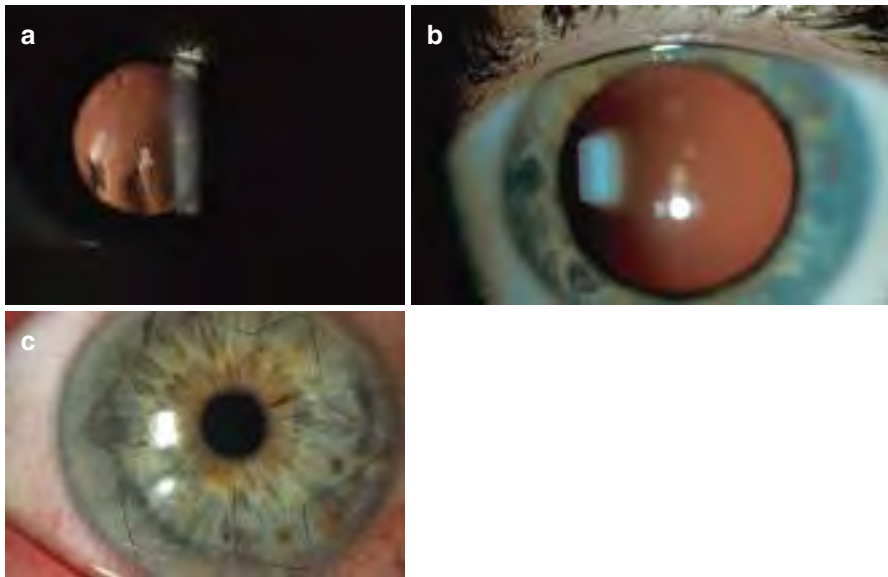
### ***Management***

Because of rapid and great improvement after refractive surgery patients tend to ignore warning symptoms of early macrostriae. But awaiting further improvement by conservative treatment will reduce treatment success of macrostriae. Early macrostriae should be treated immediately by flap lift, intensive irrigation, ironing and contact lens (CL) insertion and resolve mainly without residual visual disturbance. Late postoperative folds (either late incidence or not diagnosed before) can be handled with surgical intervention, however the results are inferior to early postoperative repositioning of macrostriae. Early striae diagnosed at the slit lamp are best controlled and ironed in the theater with the procedure including flap lift, wash and re-adaptation. The surgeon should spend enough time with the speculum inserted to guarantee stable flap alignment and prevent squeezing. A contact lens should then be

inserted to continuously stabilize the flap position after removal of the speculum. The striae will not resolve immediately after ironing—in some cases resolution may take several hours. So during the repositioning procedure maximum attention should be paid to achieving a symmetrical flap border interface in the peripheral stromal bed and perfect flap alignment regardless of persisting striae at that time point.

Ironing of late flap striae should depend on subjective symptoms. UDVA, CDVA, corneal topo/- tomography and slitlamp examination are to be considered, however subjective symptoms are main reasons for surgical intervention. A happy patient with late folds should only be referred to ironing if he is symptomatic and reports reduced visual acuity and/or night vision problems or increased sensitivity to light. In case of a late flap relift (>3 months) ironing only will probably not be successful alone and a combination of abrasio corneae, hydration and swelling of the flap and suturing is advisable. Since the epithelium is a strong modulator it should be removed before the flap is then hydrated with BSS or hypotonic solution to better regain its striae free state. The hydrated flap is then stretched with two dry triangular shaped sponges perpendicular to the striae. In a next step the flap is repositioned, the interface washed and most important the flap borders are very carefully adapted. At this point striae will not have resolved and the decision to suture should depend on the preoperative intensity of visual disturbance of the patient. Retroillumination clearly reveals the striae (Fig. 9.5a, b). Both single running (Fig. 9.5c) and interrupted sutures are effective. The suturing technique should depend on the area of lifted flap and surgeons preference (see video in springerlink).

Ultima ratio for persisting striae can be a topography guided excimer laser ablation.



**Fig. 9.5** Retroillumination revealing macrostriae (a, b) and single running sutures (c) after striae treatment

## ***Prophylaxis***

Careful intraoperative marking of the flap prior to flap microkeratome cutting and thorough flap inspection at the end of surgery will minimize the risk of early flap striae. To my experience main emphasis should focus on a circular minimal gap between flap and peripheral cornea, removal of BSS from the interface with a triangulum sponge and controlled removal of the speculum. These actions will reduce the incidence of early postoperative folds. Patients with a strong tendency for squeezing or epithelial erosions after flap repositioning should receive a therapeutic contact lens (CL) to reduce foreign body sensation and stabilize the flap in the immediate postoperative period.

## **Epithelial Ingrowth (EIG)**

### ***Incidence and Symptoms***

Epithelial ingrowth (EIG) is the result of either intraoperatively surgically displaced epithelium or of a dysbalance between irregularities at the flap border and epithelial adhesion strength. The incidence of EIG after primary microkeratome LASIK treatment is low (<0.2%) and higher after retreatment (2.3%) [20]. Main factors predisposing for EIG are retreatment (flap lift) after LASIK and unknown epithelial basement membrane dystrophy. Longer manipulation time in a flap lift procedure after LASIK increases the probability of residual epithelial cells in the interface. To my experience prolonged manipulation of the flap increases the risk for EIG more significantly than the type of flap preparation (Microkeratome versus Femtolaser). The theoretical advantage of femtolaser flap preparation with side cut and sophisticated interface profile does not result in reduced EIG rate but can result in a more sophisticated flap lift procedure and thereby increase the risk for EIG after reLASIK.

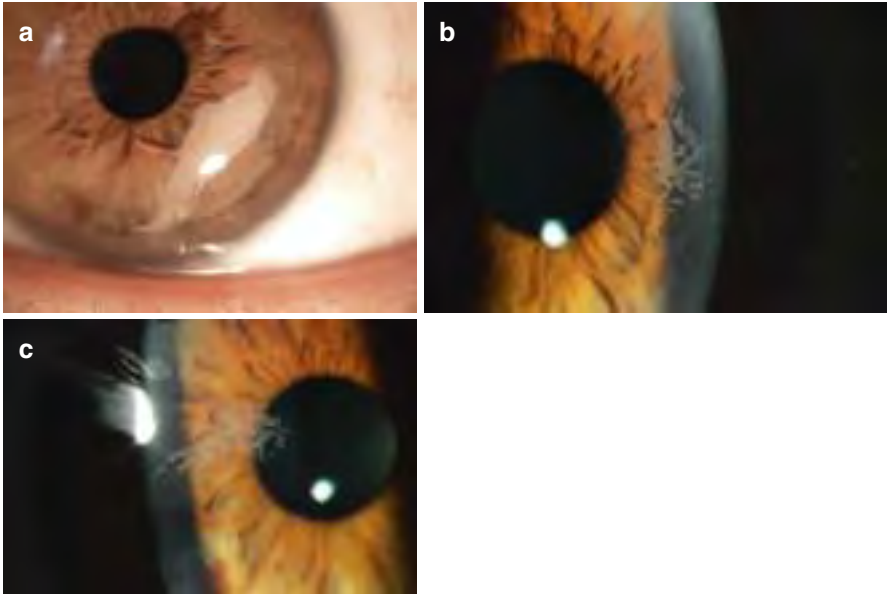
### ***Management***

There are two morphological patterns of EIG and the differentiation between homogeneous milky (Fig. 9.6a) and droplet like EIG is important (Fig. 9.6b, c).

Asymptomatic, peripheral and stable EIG can be observed without surgical intervention. Spontaneous resolution for milky EIG is possible.

Surgical intervention is advisable if the patient reports visual symptoms, change of refraction, significant foreign body sensation, pain or if irregular topography and significant flap melt is noted.

I do not recommend to lift the flap completely but only the area of involvement. Thereby epithelial invasion into previously unaffected interface areas can be prevented. On the other hand the flap must be lifted as far as needed to safely remove all epithelial islands from the interface. The stromal bed and flap must carefully be cleaned from



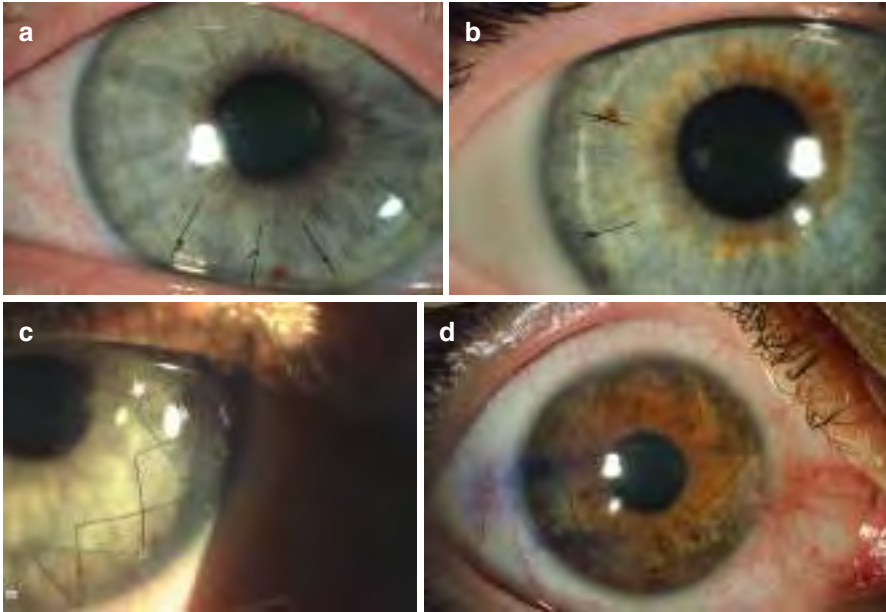
**Fig. 9.6** Homogeneous milky (a) and droplet like EIG (b, c)

epithelium with a dry triangular sponge and hockey knife. If needed 20% alcohol for 30 seconds can assist to remove the epithelium. I use it regularly for an epithelial recurrence after primary EIG removal. Enough time should be scheduled for EIG removal. After repositioning of the flap very careful inspection is mandatory and should finally be confirmed by slit lamp examination. This step is more helpful than intensive irrigation of the interface since washing itself can result in migration of new epithelial cells to the interface. A therapeutic contact lens should be inserted at the end of the procedure to guarantee good and stable flap adaptation in the early postoperative period and reduce pain. Corneal single interrupted (Fig. 9.7a, b) or double running sutures (Fig. 9.7c) are placed in recurrent EIG to better seal the interface and prevent recurrence of ingrowth. After lifting the complete flap a circumferential running suture is preferred as shown in Fig. 9.7d. Sutures should be removed after ~3 weeks.

### *Prophylaxis*

Due to the fact that flap lift is the main risk factor for EIG—every enhancement procedure should be handled with care [21]. Concentrated lifting of the flap, removal of loose epithelial islands and prolonged inspection and cleaning of the interface reduces the risk of EIG. The insertion of a CL after retreatment is controversially discussed [21]. The authors only insert a CL if significant epithelial detachment or pronounced squeezing is noted after flap repositioning.

Advanced age [20], a history of smoking and tear film hyperosmolarity seem to be positively correlated with a higher EIG incidence. The authors do not recommend



**Fig. 9.7** Single interrupted (a, b), localized double running (c) or circular running sutures (d) to align the flap after EIG removal

extensive irrigation of the flap interface since this procedure itself can result in washing in epithelial cells and tear film debris into the interface.

In cases of suspected BMD it is advisable to perform an enhancement procedure as a PRK on the flap after alcohol assisted epithelial removal. However due to the nature of BMD the reliability of refraction is reduced limiting the efficacy of the enhancement procedure.

## Dry Eyes

### *Incidence and Symptoms*

Dry eye disease (DED), or keratoconjunctivitis sicca, is a common eye problem that involves irritation and blurry vision and can affect quality of life [22]. Foreign body sensation, unstable vision and dry eye feeling are among the most often stated symptoms. The incidence of dry eye syndrome in a normal population is reported to be up to 30% [23, 24]. A recent study showed that 43% of asymptomatic patients had clinical signs of dry eyes [25]. Age, female gender, smoking and dermatological alterations of the periorbital region are correlated with a higher incidence of dry eye syndrome [26]. Untreated and progressive dry eye syndrome (DES) can result in dry eye disease (DED) with permanent discomfort and visual disturbance. Contact lens, especially extended contact lens wear can mimik clinical symptoms similar to dry eye syndrome.

## ***Management and Prophylaxis***

Tear film stability and clinical presentation of dry eye disease (DED) is a multifactorial equilibrium [27]. Therefore management of dry eye syndrome and prophylaxis are not separated in this chapter. The vicious circle of progressive dry eye disease can be triggered by external (surgery) and internal (immunological state/general health condition/endocrinological alteration/age) factors. Careful preoperative assessment of the tear film/lid margin and concomitant systemic conditions (rosacea/neurodermitis/diabetes/rheumatoid arthritis/thyroid disease) must reveal the risk of dysbalance. The impact of individual factors must be reviewed and weighted. Traditional tests for determining dry eye disease severity include the ocular surface disease index (OSDI), corneal staining with fluorescein, conjunctival staining with lissamine, tear film breakup time (TFBUT) and Schirmer's test [25]. However the correlation between traditional testing and clinical symptoms is not always convincing [28]. In addition analysis of tear osmolarity has gained popularity within the last years and helps to further classify the clinical state [29]. Tear film osmolarity may play a role in establishing objective metrics for the grading of dry eye severity [28]. Mild to moderate, but stable and controlled dry eye syndrome is a relative contraindication to performing LASIK surgery. Clinical dry eye syndrome and hyperosmolar state should preoperatively be improved with a stage related therapy and LASIK treatment postponed until a stabilized equilibrium is reached. The patient must be informed about the prolonged period of intensive eye care that is expected in preoperative existing mild dry eye syndrome. It is a challenging task to estimate the influence of increasing contact lens intolerance due to long term contact lens wear and immanent dry eye syndrome on the current state of presentation. A contact lens free intervall of ideally 4–6 weeks can help to clarify between both entities. Moderate to severe dry eye is an absolute contraindication to refractive laser surgery.

## **Late Postoperative (>3 Months) Complications**

Fernando Llovet, Julio Ortega-Usobiaga, Andrea Llovet, Julio Baviera, Mercedes Martínez-del-Pozo, Gonzalo Muñoz, and Cesar Albarrán

### ***Late LASIK Postoperative Complications***

#### **Persistent Dry Eye**

##### Causes of Persistent Dry Eye

Dry eye is the most frequent of the diseases of the ocular surface and it may be a complication after corneal refractive surgery. Dry eye is the cause of discontent because of poor visual acuity, reduced visual quality and pain [30, 31].

On the one hand, many of the patients that undergo LASIK or surface ablation used to wear contact lenses, and the use of contact lenses can originate a dry eye, due to increased tear evaporation, corneal hypoesthesia and Meibomian glands dysfunction. In fact an important reason to undergo refractive surgery is the contact lens intolerance secondary to dry eye.

On the other hand, corneal nerves get damaged in corneal surgery, more after LASIK than after surface ablation, causing hypoesthesia and dry eye. This neurotrophic component of the dry eye after LASIK has led to the term LASIK-induced neurotrophic epitheliopathy (LINE). It has also been described that the suction ring can reduce the number of goblet cells, leading to dry eye [32].

An increasing group of elderly people is undergoing LASIK and surface ablation as a bioptics approach after refractive lensectomy and multifocal intraocular lens implantation. These patients are prone to have dry eye, which is more frequent in menopausal women.

In some cases, blinking frequency is reduced or there are abnormalities on the eyelids.

### Exploring the Patient with Persistent Dry Eye

All patients undergoing corneal refractive surgery should have their eye surface explored preoperatively, and this should be done again if a persistent dry eye appears [33].

- (a) Clinical history. The patient must be asked about contact lens. Some underlying diseases, such as diabetes mellitus and autoimmune diseases may aggravate the problems of the eye surface. Dry eye symptoms may also worsen when some systemic medications (e.g. antihistaminics, antihypertensives, benzodiazepines, antidepressants) are used. Some questionnaires (e.g. OSDI=ocular surface disease index) may be interesting in order to evaluate the severity of the symptoms [34].
- (b) Silt lamp examination. The anterior pole must be examined to look for anterior blepharitis, Meibomian gland dysfunction and punctate epithelial erosions. The height of the meniscus tear and the tear break-up time must be measured.
- (c) Corneal sensitivity [35].
- (d) Schirmer test.
- (e) Other tests: tear clearance, tear osmolarity and quality of vision (OQAS, Optical Quality Analysis System).

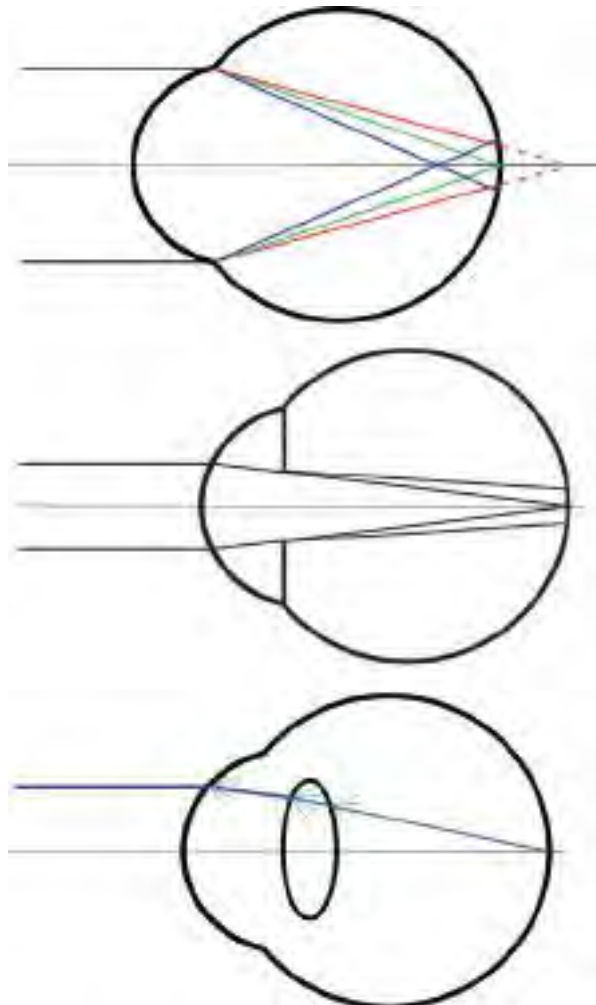
## ***Irregular High-Order Aberrations After Corneal Refractive Surgery***

### **Causes and Sources of Vision Blurring**

In the human eye perfect imaging never occurs since a variable amount of optical aberrations degrades its optical performance. Low-order aberrations (LOAs) are predominant, accounting for 90% of the overall wave aberration; defocus is the

dominant aberration, followed by astigmatism. High-order aberrations (HOAs) make a contribution of around 10% to the total normal eye's wave aberration [36].

Other factors that limit optical quality of the eye system are chromatic aberrations, diffraction and scatter. Chromatic aberrations are simply spherical refractive errors that depend on wavelength. Diffraction is any deviation of light rays from straight lines different from reflection or refraction. Diffraction is produced when light passes through the edge of the iris. It is theoretically possible to improve image quality by minimizing aberrations, but it is impossible to exceed the limits of image quality set by diffraction. Scatter in the ocular media is mainly due to diffusion and the loss of transparency in the cornea and the crystalline lens. Scattered light also reduces the performance of the eye in terms of imaging [36] (Fig. 9.8).




**Fig. 9.8** Sources of image degradation. Incident beam of white polychromatic light with several foci created by chromatic aberration (*up*); beam of light passing through the pupil is diffracted by the iris borders due to diffraction, creating halo (*middle*); scattering is produced in every refractive intraocular surface (*bottom*)

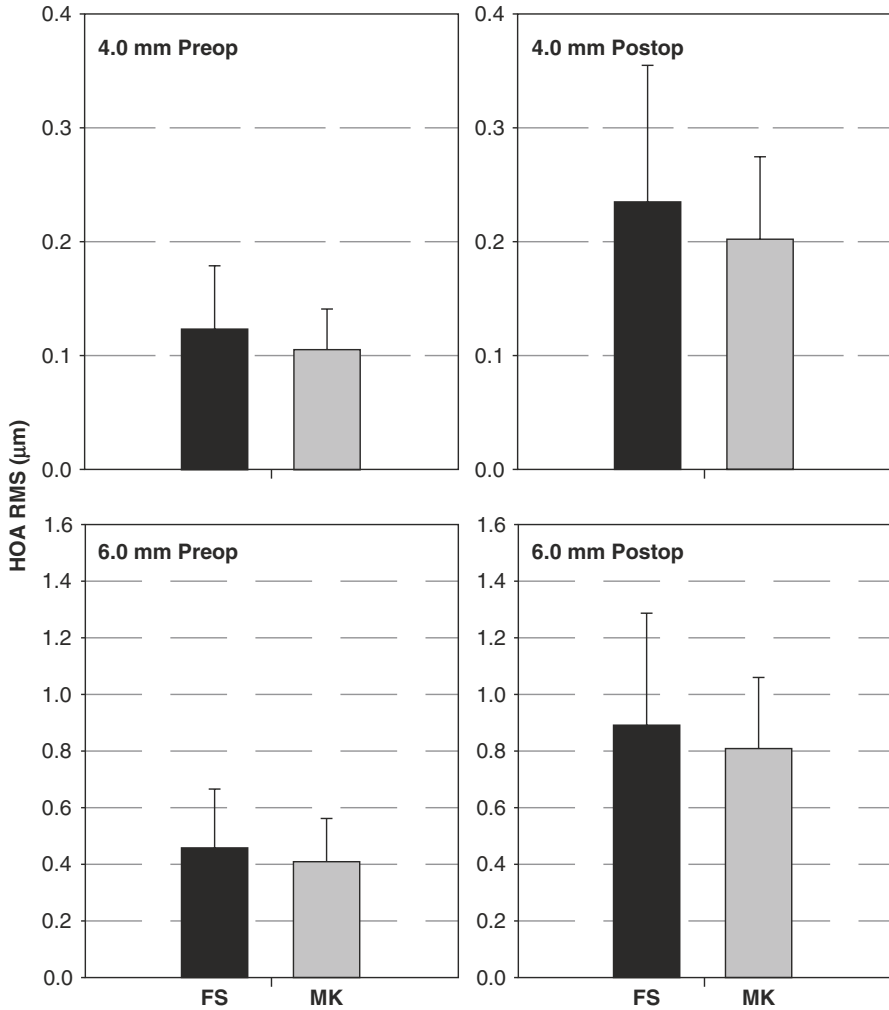


### High-Order Aberrations After Uncomplicated Excimer Refractive Corneal Surgery

All keratorefractive techniques -surface and lamellar- lead to postoperative HOAs increase, despite the use of customized or wavefront-guided ablation. Both photorefractive keratectomy (PRK) and laser in situ keratomileusis (LASIK) significantly increase total, coma-like and spherical-like wavefront aberrations (Fig. 9.9). The reported maximum postoperative increases in HOAs are higher in LASIK than in surface procedures, since the corneal flap making increases HOAs by itself. The increase in anterior HOAs after myopic LASIK is similar after mechanical microkeratome and femtosecond laser flap creation (Fig. 9.10) [37]. Central corneal flattening after myopic corrections affects the corneal natural asphericity, turning natural prolate corneal surface to oblate. Similarly, hyperopic corrections alter the corneal shape in a reverse



**Fig. 9.9** Myopic eye with decentered pupil (*top*) corrected using a LASIK ablation centered on the corneal apex (*middle*), resulting in an optical system with two refractive surfaces with parallel principal planes. When LASIK ablation is centered on the pupil, the result is an optical system with non-parallel principal planes inducing higher ocular aberrations (*bottom*)



**Fig. 9.10** Decentered post-LASIK myopic ablation before and after topography-guided PRK

way. Shape changes causing spherical, coma, and astigmatic aberrations are directly related to the pupil size and worsen as light levels decrease.

In uncomplicated eyes, the most frequent significant aberration is the spherical aberration (SA). This error is due to the difference of refractive power between the central and the peripheral corneal surface. In a non operated eye the spherical aberration of the cornea is partly compensated by the spherical aberration of the crystalline lens. After refractive corneal surgery though the corneal asphericity changes due to curvature relationship between the ablated and the non-ablated area. This phenomenon generates a halo, consisting of a concentric circle of blurred light around the focused point.

Postoperative increases in HOAs result in loss of low-contrast visual acuity, glare and scotopic visual acuity. The majority of complaints of patients with otherwise successful LASIK or PRK with normal high-contrast vision concern these issues. Accordingly, improving quality of vision in terms of contrast sensitivity, glare and halos through HOAs reduction is an important consideration. Changes in HOAs are the result of interactions of several factors: increases in pupil size, amount of correction, ablation profile, decentration, corneal asphericity, corneal irregularity, corneal haze and wound healing including prolonged dry eye symptoms are all known to be associated with an increase in HOAs after surgery. Treating higher refractive errors alter the shape more significantly than treatment of lower refractive errors, and larger pupils unmask more of this altered contour. Small optical zones, large pupils, and high myopic corrections are directly related to increases in SA.

### **High-Order Aberrations After Complicated Photorefractive Corneal Surgery**

Corneal surface irregularities, decentered ablations, or small treatment zones are possible complications of excimer laser refractive surgery. Irregular and increased HOAs correlate with clinical complaints: double vision with total and horizontal coma, glare with spherical and total aberrations, and starburst and halos with SA.

#### **Decentration**

Decentration of ablation occurs when the effect of surgery results in an asymmetric alteration of the eye's optical system, increasing HOAs, especially horizontal or vertical coma, and irregular astigmatism (Fig. 9.10). Accurate centration of the optical zone is a crucial factor; however, the human eye is not a coaxially centered optical system, and locating the ideal center for the ablation is not always an exact process. Even subclinical decentrations can cause increases in coma-like and spherical-like HOAs, as well as LOAs such as tilt, defocus, and cylinder [38].

The aberrations more affected by decentration are coma, tilt and astigmatism. The factor of change can be as high as 46 for vertical coma, 33 for tilt, and 18 for SA [39]. Decentration has a more significant influence on coma-inducing effects and the aberrations affected are determined by the direction of decentration. When the decentration is predominantly in the vertical direction, the steepest increase is in vertical coma; and conversely when decentration is in the horizontal direction, horizontal coma is mostly affected. Strong relationships are found between the degree of decentration and the induced coma, tilt, and secondary astigmatism [40].

There is some debate concerning the corneal location at which the ablation should be centered to minimize HOAs. Centration can be done at the center of the pupil while the patient fixates on a target coaxial with the excimer laser beam. However, the pupil center is unstable as a centration reference because it shifts with changes in pupil size, and it is not possible to locate the point of intersection between the visual axis and the corneal surface under the surgical microscope because every patient has a different angle kappa or lambda. The corneal vertex only provides an

approximation of the visual axis, although it is on average closer to the visual axis than the center of the entrance pupil. Centration on corneal vertex is better in comparison with pupil-center treatments in terms of induced coma and SA after wavefront guided LASIK, with no differences in photopic visual acuity [41].

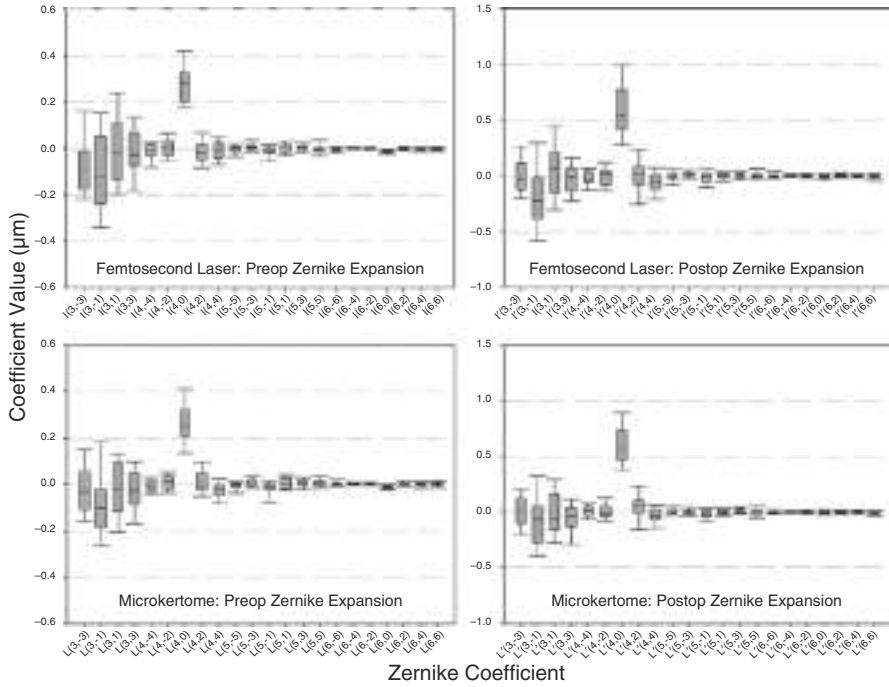
Centration is much more crucial than cyclotorsion errors [42]. Second-order astigmatism is the largest residual aberration induced by cyclotorsional misalignment, whereas coma is the largest residual aberration induced by centration error. Decentration increases wavefront aberrations in modes of order lower than itself; the greater the amount of original aberrations in any order, the greater the decentration-induced wavefront error in the next lower order. Hence, because 4th-order SA is the largest HOA induced by decentration, decentration also induces relatively large amounts of 3rd-order coma.

Zernike terms in the center of the Zernike pyramid have a greater impact on high-contrast and low-contrast visual quality than those near the edge [43]. Decentration produces aberrations in Zernike terms in the center of the Zernike tree, whereas cyclotorsional misalignment produces aberrations in Zernike terms in the edge. This finding explains the greater visual impact induced by centration error in comparison with cyclotorsional misalignment.

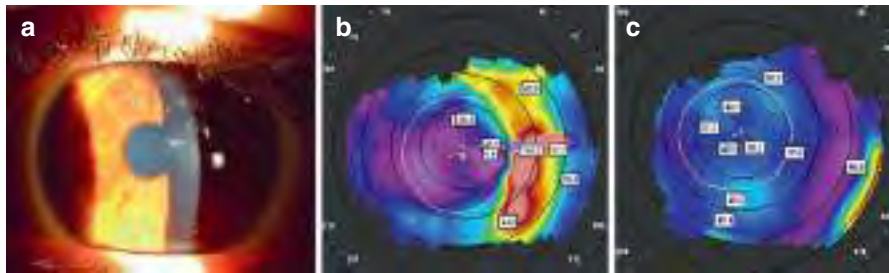
## Corneal Irregularity

Significant corneal irregularity can result after complicated LASIK, including buttonholed flaps (Fig. 9.11), small, incomplete or decentered flaps with small optical zones (Fig. 9.12), thin irregular flaps with opacities (Fig. 9.13), micro or macrostriae, and epithelial ingrowth (Figs. 9.14a, b). Corneal irregularity after PRK is generally related to severe scarring and haze (Fig. 9.14c). This results in irregular astigmatism, which appears when the principal meridians of the cornea are not 90° apart, without a progressive transition from one meridian to another. Irregular astigmatism cannot be corrected with glasses, since the refraction in different meridians conforms to a non-geometric plane, and the refractive rays have no planes of symmetry. The irregular and highly aberrated cornea causes visual distortion with glare, halos, monocular diplopia, and loss of vision.

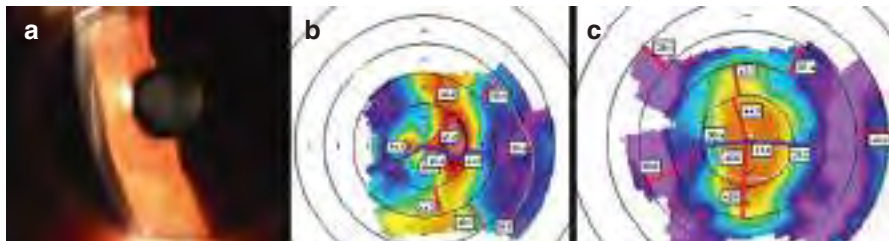
Irregular astigmatism is best evaluated by means of anterior corneal aberrometry, which consists on a mathematical transformation of the anterior corneal topography data. Corneal wavefront analysis is not interfered by accommodation or intraocular aberrations and offers precise information about the corneal problem. Corneal aberrometry is also independent of pupil size and can be analyzed by different mathematical approaches, commonly the Zernike polynomials and Fourier analysis. In the normal eye, more than 90% of the eye aberrations are derived from the cornea, but this proportion is larger when corneal irregularity is present. The measurement of the HOAs from the third to the eighth order of the Zernike decomposition, offers global data about the irregularity which is essential to plan a treatment. Corneal wavefront analysis can be obtained almost in any case of corneal irregularity, even in highly aberrated corneas. Macro-irregular patterns can be analyzed and treated based on this information, and to some extent, the micro-irregular component.



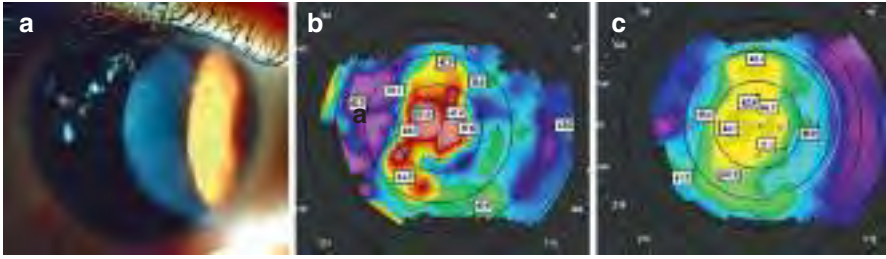
**Fig. 9.11** Buttonholed flap (a) with irregular astigmatism before (b) and after (c) enhancement using topography-guided surface excimer laser ablation



**Fig. 9.12** A too central flap hinge after LASIK (a) causing irregular astigmatism and increased HOAs before (b) and after topography-guided PRK retreatment (c)



**Fig. 9.13** Thin irregular flap and corneal scarring after LASIK (a) with topography before (b) and after (c) topography-guided PRK



**Fig. 9.14** Other causes of increased and irregular HOAs are macrostriae (a), and epithelial ingrowth (b) after LASIK, and haze after PRK (c)

### HOA in Ectasia

Keratoectasia, discussed later in chapter 12 in detail, is a serious complication of refractive laser surgery consisting of a progressive corneal thinning, anterior and posterior corneal steepening, irregular astigmatism, increase in all ocular aberrations and visual loss. Large amounts of anterior corneal HOAs and internal astigmatism are present. The eyes with corneal ectasia show significant higher coma and SA. The amount of HOAs can be used for the early diagnosis and to monitor the progression of this complication.

Eyes with keratoectasia show significantly higher anterior keratometric readings and more negative central asphericity than normal post-LASIK eyes, together with higher spherical-like and coma-like HOAs [44]. In addition to high corneal astigmatism, eyes with keratoectasia show high internal astigmatism from changes coming from the posterior corneal surface. Corneal primary SA and coma correlate significantly with vision: the more negative the spherical aberration and the higher the level of primary coma, the worse the corrected and unaided vision.

### Treatment of Irregular High-Order Aberrations

The diagnostic capability of the wavefront system in predicting visual symptoms and complaints of patients with HOAs is of utmost importance. Treatment of eyes with high and irregular HOAs after corneal refractive surgery can be guided by topography, by aberrometry or by a combination of both [45–49]. The macroirregular components can be rightly treated by topography-guided treatments. Corneal wavefront derived from corneal topography, converting the elevation data in terms of Zernike and Seidel polynomials to quantify the corneal wavefront aberrometry can also be used.

Topography-driven treatments give a reasonably effective surgical tool for the management of eyes with increased HOAs by combining videokeratography and subsequent topography-based, ablation-customized. However, despite clinical improvement in many cases, there is considerable undercorrection especially in highly irregular corneas. The main drawbacks of this technology are the missing direct link between the corneal topography and the laser treatment, as well as the

questionable ability of the clinically used topographic systems to provide accurate captures of highly irregular corneas. The actual technique of topography driven treatments is described in the chapter “topography based ablation” in this book.

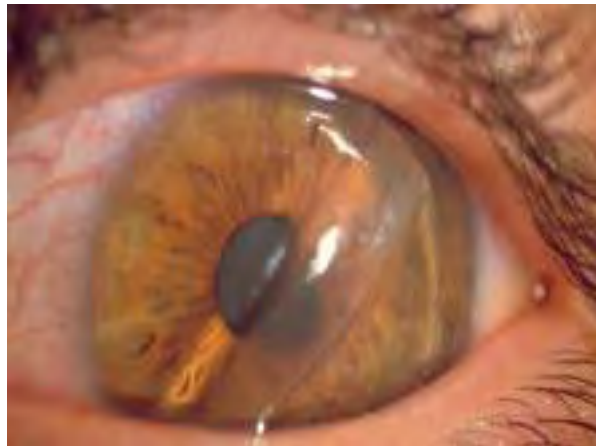Wavefront analyzers also have limitations in measuring highly aberrated eyes. Furthermore, any customized photorefractive correction based on wavefront-guided data requires much deeper tissue excision. Despite the theoretical advantage of the wavefront-guided treatments over the topography guided corrections, in our experience topography-guided approach is still the preferred surgical modality for the management of highly aberrated eyes with irregular astigmatism and decentered ablations patterns (Figs. 9.11, 9.12 and 9.13).

The software usually enables the surgeon to take an active part in the decision-making process: the surgeon can choose the optical zone, transition zones, and the exclusion of specific aberrations. Using this surgeon’s corneal topography or wavefront-guided methods, total higher-order aberrations can be reduced significantly, increasing vision and improving patients’ complaints. Corneal topography or wavefront-guided methods are especially valuable in the correction of hyperopic and myopic decentrations, and to enlarge the optical zone in symptomatic patients with night vision problems related to optical zone treatment.

## *Late Lasik Postoperative Complications*

### **Traumatic Flap Dislocation**

The traumatic flap dislocation may be a postoperative complication in patients that have undergone LASIK. This causes flap folds and anatomical distortion of the corneal surface (Fig. 9.15). Traumatic dislocations can be seen years after LASIK.



**Fig. 9.15** Traumatic flap dislocation post operatively

The diagnosis is based on the observation on slit lamp of the flap displacement with striae on it. The visual acuity is usually impaired, more when the flap is more displaced. Fluorescein examination and retroillumination with pupil dilation helps diagnosing slight striae and folds (Figs. 9.16 and 9.17).

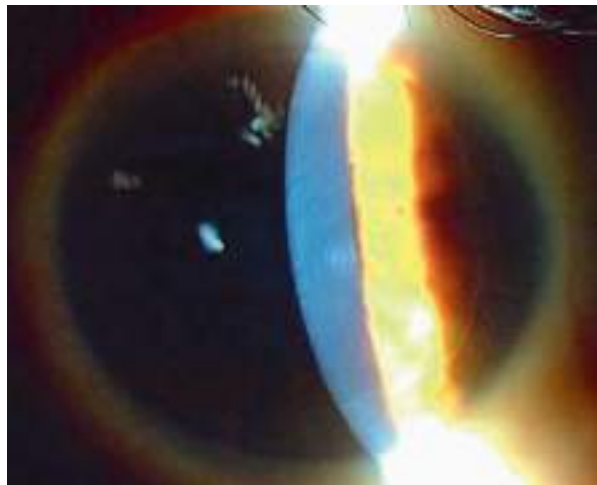
Depending on the severity of the dislocation we can find epithelium, hing crests, hinge folds, epithelium-Bowman's striae and deep epithelium-Bowman-stromal striae.

The dislocated flap must be urgently treated. Depending on the severity and findings the flap must be replaced using a slit lamp or surgically. Very slight dislocations, with superficial striae, could be solved easily with a slit lamp [50].

**Fig. 9.16** Flap macrostria seen with retro illumination



**Fig. 9.17** Traumatic flap slippage causing macro stria





However, in most cases, the corneal flap must be repositioned at the operating theatre. If a DLK or an infection is suspected, it is mandatory that the treatment is surgical.

## Surgical Treatment

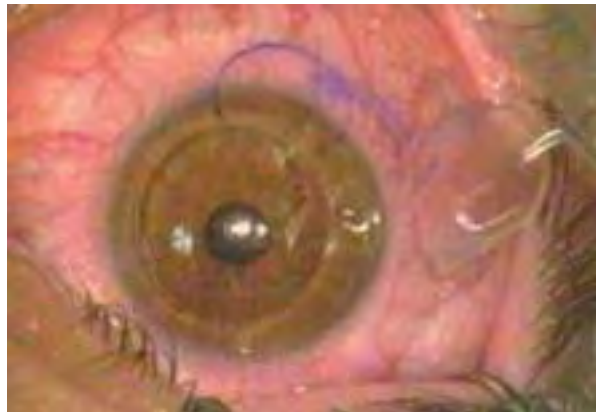Firstly, the flap must be repositioned, with the edge of the flap perfectly aligned with the margins of the rest of the cornea. Differently than intra-operatively free flap (Fig. 9.18) the surgeon repositioning the traumatically dislocated flap is not assisted by pre-cut marking and the bare stroma is usually covered with new epithelium, hence masking the stromal cut border. Then the flap is hydrated by using saline or a hypotonic solution. Finally, as described by Muñoz et al., the flap is stretched with microsponges or tweezers, and the edges are dried carefully [51, 52].

If folds persist after the initial treatment, the epithelium must be removed to ease the corneal stretching.

There are some other techniques described to solve the problem of the persistent folds and striae:

- (a) Rolling pin technique (Llovet). A syringe full of saline is used as if it were a rolling pin, moving it perpendicularly to the folds, in order to stretch the flap [50].
- (b) Hyperthermic technique (Donnenfeld). A hot spatula rubs the flap [53].
- (c) Sandwich technique (Hernández-Matamoros). Round edged tweezers are used [54].
- (d) Sutures. In some severe cases the flap must be stabilized by suturing the flap with nylon (10/0) [55].
- (e) Photorefractive keratectomy (PTK). The flap is stretched and the excimer laser is applied during 20 s, using mytomicin C at the end [56].
- (f) Flap removal. This can be considered when there is a significant visual impairment and none of the above techniques has been successful.

**Fig. 9.18** Free cap in lasik: requires careful handling and exact repositioning



After any of the stretching techniques a bandage contact lens is placed to prevent epithelial ingrowth and a new flap dislocation. Topical steroids, antibiotics and artificial tears are prescribed. If necessary cycloplegic is added.

When an epithelial ingrowth is found, it must be removed before any the flap is stretched.

A difficult case may appear if a complete dislocation of a previous free cap occurs. As there is no marks and the flap is round, it is very difficult to correctly replace the flap. We must replace the flap the way we think is best and measure the refraction. If a severe mixed astigmatism is present, then the flap may be incorrectly replaced. The following steps should be performed [57]:

- (a) Calculate the astigmatism with a positive lens: e.g.  $+2.00 - 4.00 \times 150^\circ$  should be expressed as  $-2.00 + 4.00 \times 60^\circ$ .
- (b) Take away  $45^\circ$  from the axis and multiply by 2: e.g.  $60 - 45 = 15^\circ$ .
  - If the result is positive the flap must be rotated clockwise. In the example, we must rotate  $15^\circ$  clockwise.
  - If the result is negative the flap must be rotated counter clockwise
- (c) The vertical axis ( $90^\circ$ ) and the desired axis are marked using a slit lamp before rotating at the operating theatre.

### ***Therapeutic Flap Amputation***

Toam R. Katz

The regular smooth surface of a healthy flap is the first and most important refractive surface of the eye. On the contrary, an irregular flap surface or flap and interface loss of clarity cause a serious degradation of the visual acuity and visual quality of the eye. Such pathologies in shape or clarity of the cornea can not be corrected by refractive aids and may be treated by surgically removing the opacity, for example by cleaning a dense white epithelial ingrowth from the flap interface, or reshaping the anterior corneal irregularity by topography based ablation, as discussed elsewhere in this book. The healthy flap is not only the best refractive surface for the cornea post LASIK, but it also protects the deeper stroma and includes the Epithelium with its smoothening capability and the Bowmann layer with its haze preventing capacity. Therefore the refractive surgeon should make any effort to correct pathology in corneal shape or clarity while preserving the corneal flap tissue.

Very rarely the flap is damaged to such an extent that its complete removal (amputation) may provide a smoother and clearer underlying surface without a flap than with a pathologic one [58, 59].

Theoretically a healthy flap is refractive neutral having constant thickness and symmetric shape, so by removing a healthy flap the cornea should maintain its previous keratometry and refraction. In real life the flap does have its own curvature and its own refraction caused by hinge, cutting pattern and its interaction with the underlying stroma. Comparing the post operative refraction of intended sphere myopic lasik using 2 different MKs revealed a mean surgical induced astigmatism of 0.35 D probably related to the presence of the flap itself [60]. Removing or losing such a healthy flap will therefore create a new refraction. A pathologic flap with scars, melting or flap substance loss, on the other hand, produces such a highly irregular astigmatism that prevails a useful DCVA and causes severe visual symptoms. When the surgeon feels that the eye would be better off without that flap he or she may indicate the flap amputation. This is a non reversible step and should be used only when all methods to preserve the flap with useful vision fail.

*Indication for flap amputation are:*

1. *Very irregular astigmatism with low corrected Visus resistant to conservative treatment and to topography based ablation*
2. *Loss of significant flap tissue in the optical zone*
3. *Massive flap stromal melting by keratitis or by untreated central epithelial ingrowth*
4. *Very scarred flap with flap opacity in the optical zone*
5. *Unsuccessfull DCVA with a hard contact lens or a non tolerated hard contact lens*

The purpose of flap removal is to let new epithelium cover the exposed stromal bed and create a regular surface, similarly to a cornea after PRK. This regular surface should heal and allow a stable refraction, and an acceptable corrected visus. Additional refractive surgeries are possible at a later stage.

*Flap amputation procedure*

1. *The flap may be lifted and the hinge excised. Make sure the flap bed covers the whole optical zone.*
2. *Residual epithelial tissue or scar tissue on the previous interface should be scraped away.*
3. *Mitomycin C (MMC) 0.02 % application for 30 s*
4. *Local antibiotics and cortisone eye drops*
5. *Therapeutic contact lens*

The final keratometry after flap amputation depends on the size and shape of the original flap and on the associated complications leading to the pathologic flap. A planar flap either by sub Bowmann microkeratom or by Femtolaser should leave a regular stromal surface. A pivoting older generation microkeratom produces a flap

that is thinner in center and may cause after its amputation an irregular stromal curvature. Older mikrokeratomats were reported to produce high order aberration by the flap cut itself [61, 62]. Removing such a flap will expose the existing cut induced HOAs and will not correct the irregular astigmatism. Development of stromal haze after amputation may reduce the visual acuity and quality dramatically and should be prevented by using MMC intraoperatively.

After non complicated flap amputation the cornea should be followed for several months until epithelial remodeling and smoothing effect reaches a steady state. Only then one should consider additional surgical refractive modalities.

Flap amputation cases are rare to encounter and rare to document since they normally seek advice by different experts. We do have two well documented referred cases in which we indicated and performed flap amputations:

**Case 1: Myope with Small Free Flap** A 32 years old male with low myopic astigmatism on his right eye ( $-1.25 - 0.75 \times 087^\circ = 1.0$ ) had a smaller than 7 mm free incomplete flap with a pericentral torn nasal hinge using a Schwind MK. Excimer laser was aborted and the incomplete free flap was correctly repositioned. Four and 10 months later the flap had persistent macrostria and scarred hinge and low DCVA (UCVA: 0.1, DCVA:  $-2.5 - 0.75 \times 055^\circ = 0.3$ ). Flap sutures to correct macrostria did not improve DCVA. After 4 more months the small scarred flap with macro stria and melted borders was amputated (Fig. 9.19). MMC 0.02% was applied for 30 s. Eight months post amputation a regular astigmatism could be well corrected with UCVA of 0.3 and DCVA:  $(+3.00 - 2.00 \times 031^\circ = 0.9)$  and average keratometry of 40.8 D. The stroma was clear with minimal thickness of 485  $\mu\text{m}$ . The next planned treatment is PRK with MMC. The topographies before and after the amputation show an improvement of the regularity corresponding to the improved DCVA after amputation (Fig. 9.20).



**Fig. 9.19** Amputated small flap

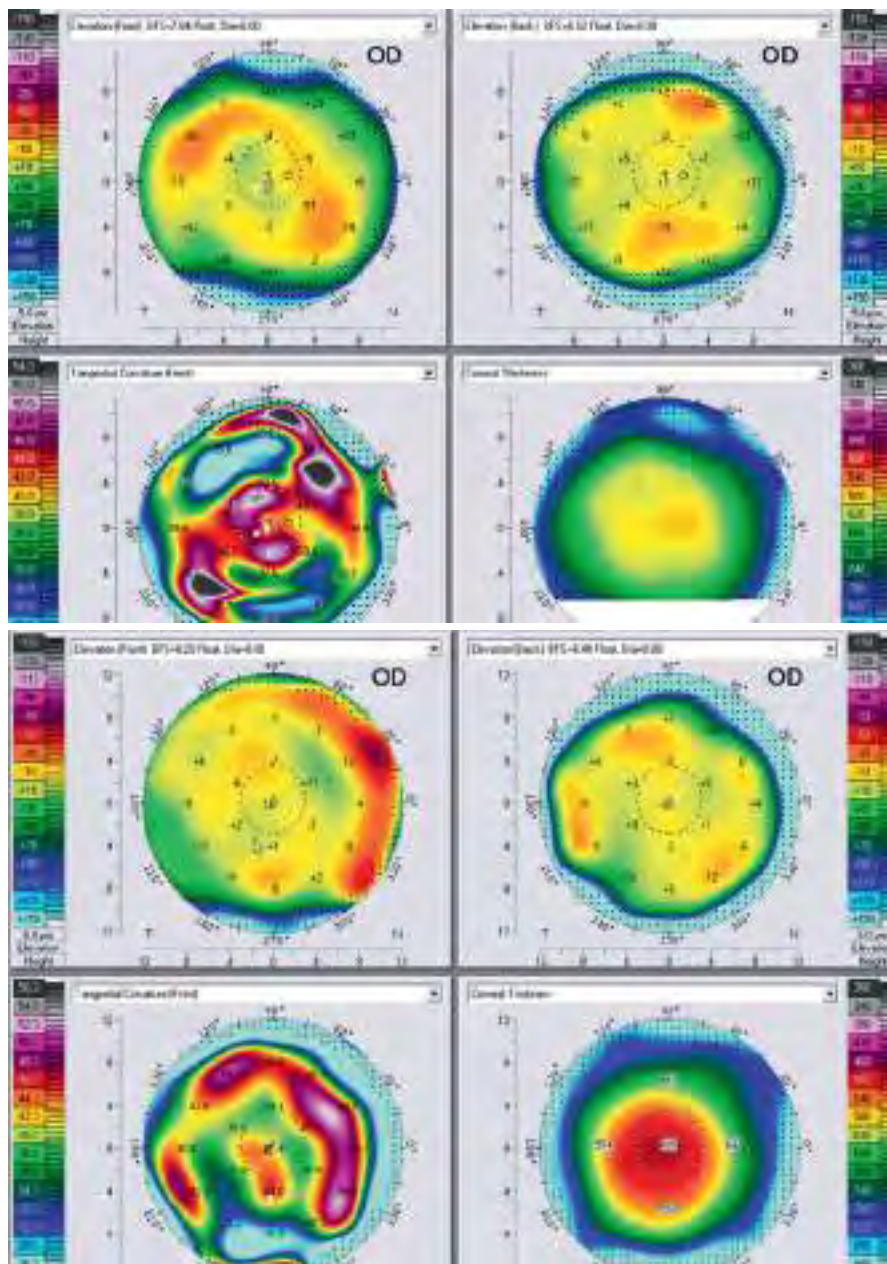


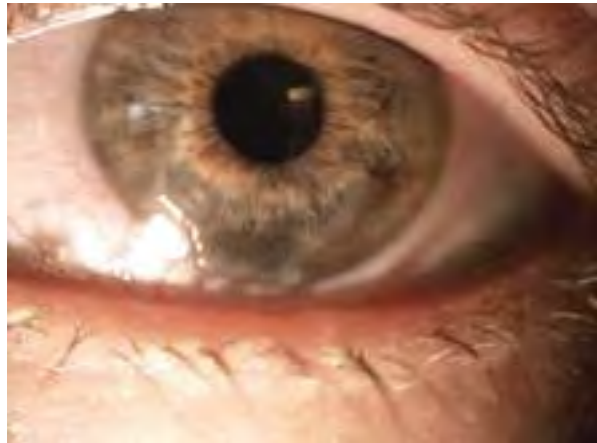Fig. 9.20 Post free small flap. Pre amputation, Post amputation

**Case 2:** A 46 years old woman with low myopic astigmatism on the left eye ( $-1.25 - 1.00 \times 003^\circ = 1.20$ ) had a free flap using the Moria SBK MK. The free flap was  $81 \mu\text{m}$  thick of full size and regular shape and Excimer ablation was performed. The free flap was repositioned and secured with a contact lens. After 4 months the patient

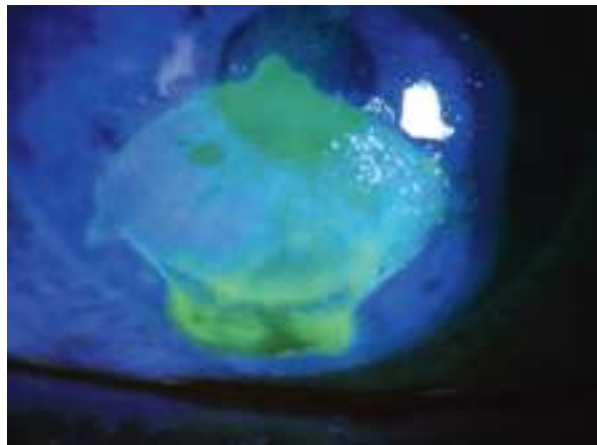
showed up with a scarred rolled flap decentered inferiorly. The central cornea was covered with epithel without flap covering it. Surprisingly with good UCVA of 0.65 and very good DCVA ( $+2.00 - 1.25 \times 095^\circ = 1.1$ ). Seeking for a retreatment the scarred rolled flap had to be amputated with application of MMC. Surprisingly the ablated stromal bed reepithelialised without any scarring and the UDVA after 4 months was 1.2. No further treatment is indicated. The topographies before and after the amputation show an improvement of the regularity corresponding to the improved UCVA after amputation (Figs. 9.21, 9.22, 9.23, 9.24, 9.25 and 9.26).

In summery an irregular flap with underlying healthy stroma can induce a persistent irregular astigmatism and low DCVA. Sometimes the radical solution of removing the whole flap may resolve the problem elegantly. With very few reports in the literature this procedure should be regarded as experimental.

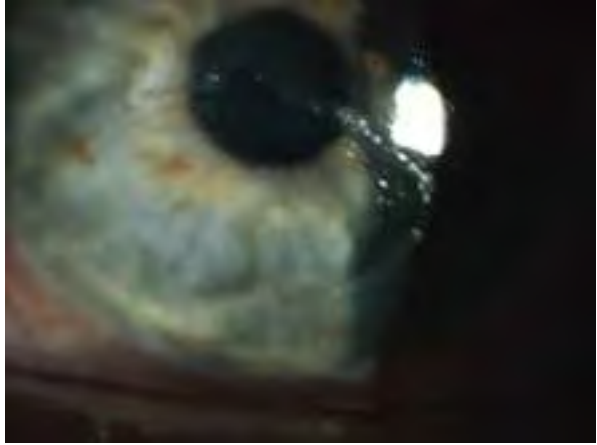**Fig. 9.21** Rolled flap before amputation



**Fig. 9.22** Fluorescein staining immediately after amputating the scarred rolled flap



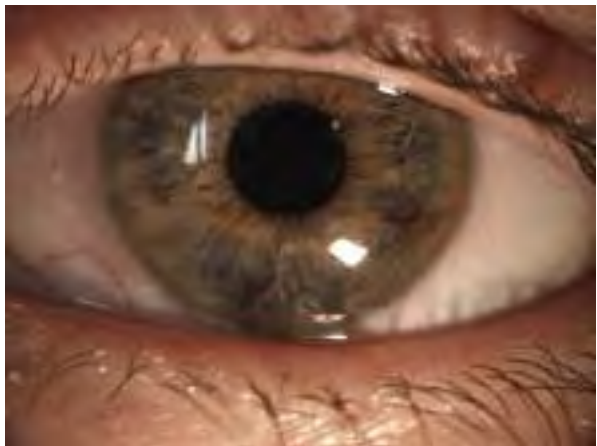
**Fig. 9.23** Immediately after amputation



**Fig. 9.24** The amputated flap



**Fig. 9.25** 1 week post amputation



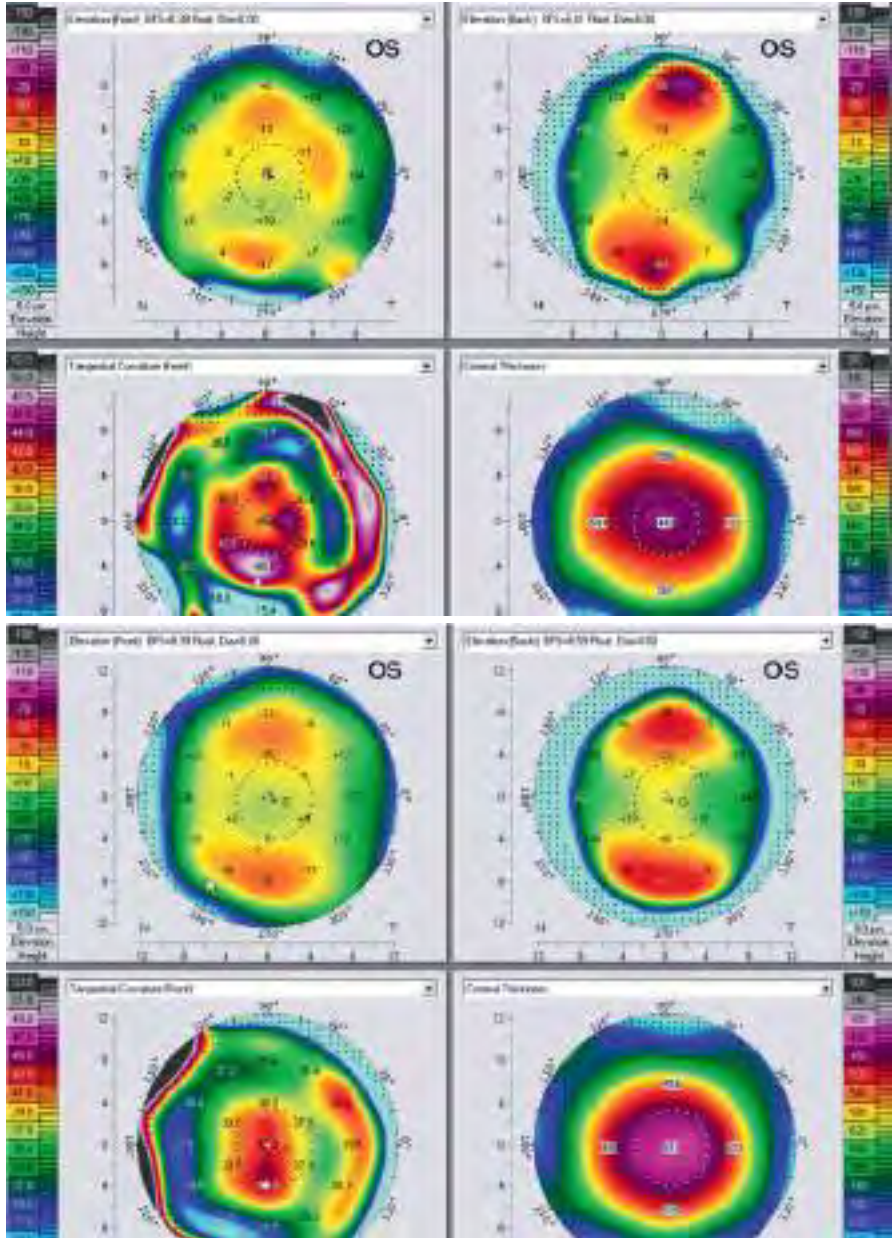


Fig. 9.26 Downwards decentered rolled flap after free flap and excimer. After amputation



## References

### *Early post LASIK Complications*

1. Randleman JB, Shah RD. LASIK interface complications: etiology, management, and outcomes. *J Refract Surg.* 2012;28(8):575–86.
2. Gritz DC. LASIK interface keratitis: epidemiology, diagnosis and care. *Curr Opin Ophthalmol.* 2011;22(4):251–5.
3. Linke SJ, Richard G, Katz T. Infectious keratitis after LASIK—update and survey of the literature. *Klin Monbl Augenheilkd.* 2011;228(6):531–6.
4. Ambrosio Jr R, Periman LM, Netto MV, Wilson SE. Bilateral marginal sterile infiltrates and diffuse lamellar keratitis after laser in situ keratomileusis. *J Refract Surg.* 2003;19(2):154–8.
5. Boorstein SM, Henk HJ, Elnor VM. Atopy: a patient-specific risk factor for diffuse lamellar keratitis. *Ophthalmology.* 2003;110(1):131–7.
6. Linebarger EJ, Hardten DR, Lindstrom RL. Diffuse lamellar keratitis: diagnosis and management. *J Cataract Refract Surg.* 2000;26(7):1072–7.
7. Diaz-Valle D, Arriola-Villalobos P, Sanchez JM, Santos Bueso E, de la Casa JM, Sardina RC. Late-onset severe diffuse lamellar keratitis associated with uveitis after LASIK in a patient with ankylosing spondylitis. *J Refract Surg.* 2009;25(7):623–5.
8. Buhren J, Cichocki M, Baumeister M, Kohnen T. Diffuse lamellar keratitis after laser in situ keratomileusis. Clinical and confocal microscopy findings. *Ophthalmologe.* 2002;99(3):176–80.
9. Spadea L, Giammaria D, Trabucco P. Corneal wound healing after laser vision correction. *Br J Ophthalmol.* 2016;100(1):28–33.
10. Price MO, Price DA, Bucci Jr BSFA, Durrie DS, Bond WI, Price Jr FW. Three-year longitudinal survey comparing visual satisfaction with LASIK and contact lenses. *Ophthalmol.* 2016;123(8):1659–66.
11. Donnenfeld ED, Kim T, Holland EJ, Azar DT, Palmon FR, Rubenstein JB, et al. ASCRS white paper: management of infectious keratitis following laser in situ keratomileusis. *J Cataract Refract Surg.* 2005;31(10):2008–11.
12. Solomon R, Donnenfeld ED, Azar DT, Holland EJ, Palmon FR, Pflugfelder SC, et al. Infectious keratitis after laser in situ keratomileusis: results of an ASCRS survey. *J Cataract Refract Surg.* 2003;29(10):2001–6.
13. Llovet F, de Rojas V, Interlandi E, Martin C, Cobo-Soriano R, Ortega-USobiaga J, et al. Infectious keratitis in 204 586 LASIK procedures. *Ophthalmology.* 2010;117(2):232–8, e1–4.
14. Ortega-USobiaga J, Llovet-Osuna F, Djodeyre MR, Llovet-Rausell A, Beltran J, Baviera J. Incidence of corneal infections after laser in situ keratomileusis and surface ablation when moxifloxacin and tobramycin are used as postoperative treatment. *J Cataract Refract Surg.* 2015;41(6):1210–6.
15. Linke SJ, Skevas C, Richard G, Katz T. Bilateral achromobacter xylosoxidans keratitis after laser in situ keratomileusis. *J Cataract Refract Surg.* 2010;36(6):1045–7.
16. Kymionis GD, Kankariya VP, Kontadakis GA. Combined treatment with flap amputation, phototherapeutic keratectomy, and collagen crosslinking in severe intractable post-LASIK atypical mycobacterial infection with corneal melt. *J Cataract Refract Surg.* 2012;38(4):713–5.
17. Price MO, Price Jr FW. Corneal cross-linking in the treatment of corneal ulcers. *Curr Opin Ophthalmol.* 2016;27(3):250–5.
18. Probst LE, Machat J. Removal of flap striae following laser in situ keratomileusis. *J Cataract Refract Surg.* 1998;24(2):153–5.
19. Jackson DW, Hamill MB, Koch DD. Laser in situ keratomileusis flap suturing to treat recalcitrant flap striae. *J Cataract Refract Surg.* 2003;29(2):264–9.
20. Caster AI, Friess DW, Schwendeman FJ. Incidence of epithelial ingrowth in primary and retreatment laser in situ keratomileusis. *J Cataract Refract Surg.* 2010;36(1):97–101.

21. Chan CC, Boxer Wachler BS. Comparison of the effects of LASIK retreatment techniques on epithelial ingrowth rates. *Ophthalmology*. 2007;114(4):640–2.
22. Miljanovic B, Dana R, Sullivan DA, Schaumberg DA. Impact of dry eye syndrome on vision-related quality of life. *Am J Ophthalmol*. 2007;143(3):409–15.
23. The epidemiology of dry eye disease: report of the Epidemiology Subcommittee of the International Dry Eye WorkShop. *Ocul Surf*. 2007;5(2):93–107.
24. Moss SE, Klein R, Klein BE. Prevalence of and risk factors for dry eye syndrome. *Arch Ophthalmol*. 2000;118(9):1264–8.
25. Sullivan BD, Crews LA, Messmer EM, Foulks GN, Nichols KK, Baenninger P, et al. Correlations between commonly used objective signs and symptoms for the diagnosis of dry eye disease: clinical implications. *Acta Ophthalmol*. 2014;92(2):161–6.
26. Yoon SY, Bae SH, Shin YJ, Park SG, Hwang SH, Hyon JY, et al. Low serum 25-hydroxyvitamin D levels Are associated with Dry Eye syndrome. *PLoS One*. 2016;11(1):e0147847.
27. Management and therapy of dry eye disease: report of the Management and Therapy Subcommittee of the International Dry Eye WorkShop. *Ocul Surf*. 2007;5(2):163–78.
28. Suzuki M, Massingale ML, Ye F, Godbold J, Elfassy T, Vallabhajosyula M, et al. Tear osmolarity as a biomarker for dry eye disease severity. *Invest Ophthalmol Vis Sci*. 2010;51(9):4557–61.
29. Pepose JS, Sullivan BD, Foulks GN, Lemp MA. The value of tear osmolarity as a metric in evaluating the response to dry eye therapy in the clinic and in clinical trials. *Am J Ophthalmol*. 2014;157(1):4–6. e1.

### ***Persistent Dry Eye***

30. Llovet-Osuna F, Ortega-Usobiaga J. Cirugía refractiva. Protocolos. Madrid: Sociedad Española de Oftalmología; 2014.
31. Rosenfeld SI. Evaluation and management of post-LASIK dry eye syndrome. *Int Ophthalmol Clin*. 2010;50:191–9.
32. Benítez del Castillo JM, del Río T, Iradier MT, Hernández JL, Castillo A, García-Sánchez J. Decrease in tear secretion and corneal sensitivity after LASIK. *Cornea*. 2001;20:30–2.
33. Vico E, Benítez del Castillo JM, Giménez R, Fernández C, García-Sánchez J. Validación del índice de función lagrimal para el diagnóstico de ojo seco. *Arch Soc Esp Ophthalmol*. 2004;79:265–72.
34. Donate J, Benítez del Castillo JM, Fernández C, García-Sánchez J. Validación de un cuestionario para diagnóstico del ojo seco. *Arch Soc Esp Ophthalmol*. 2002;77:493–500.
35. Benitez-del-Castillo JM, Acosta MC, Wassfi MA, Diaz-Valle D, Gegundez JA, Fernandez C, Garcia-Sanchez J. Relation between corneal innervation with confocal microscopy and corneal sensitivity non-contact esthesiometry in patients with dry eye. *Invest Ophthalmol Vis Sci*. 2007;48:173–81.

### ***Irregular High-Order Aberrations After Corneal Refractive Surgery***

36. Lombardo M, Lombardo G. Wave aberration of human eyes and new descriptors of image optical quality and visual performance. *J Cataract Refract Surg*. 2010;36:313–31.
37. Muñoz G, Albarrán-Diego C, Ferrer-Blasco T, García-Lázaro S, Cerviño-Expósito A. Long-term comparison of corneal aberration changes after laser in situ keratomileusis:

- Mechanical microkeratome versus femtosecond laser flap creation. *J Cataract Refract Surg.* 2010;36:1934–44.
38. Mrochen M, Kaemmerer M, Mierdel P, Seiler T. Increased higher-order optical aberrations after laser refractive surgery: a problem of subclinical decentration. *J Cataract Refract Surg.* 2001;27:362–9.
  39. Padmanabhan P, Mrochen M, Viswanathan D, Basuthkar S. Wavefront aberrations in eyes with decentered ablations. *J Cataract Refract Surg.* 2009;35:695–702.
  40. Lee S-B, Hwang B-S, Lee J. Effects of decentration of photorefractive keratectomy on the induction of higher order wavefront aberrations. *J Refract Surg.* 2010;26:731–43.
  41. Arbeláez MC, Vidal C, Arba-Mosquera S. Clinical outcomes of corneal vertex versus central pupil references with aberration-free ablation strategies and LASIK. *Invest Ophthalmol Vis Sci.* 2008;49:5287–94.
  42. Wang L, Koch DD. Residual higher-order aberrations caused by clinically measured cyclotorsional misalignment or decentration during wavefront-guided excimer laser corneal ablation. *J Cataract Refract Surg.* 2008;34:2057–62.
  43. Applegate RA, Ballentine C, Gross H, Sarver EJ, Sarver CA. Visual acuity as a function of Zernike mode and level of root mean square error. *Optom Vis Sci.* 2003;80:97–105.
  44. Piñero D, Alió JL, Barraquer RI, Uceda-Montañés A, Murta J. Clinical characterization of corneal ectasia after myopic laser in situ keratomileusis based on anterior corneal aberrations and internal astigmatism. *J Cataract Refract Surg.* 2011;37:1291–9.
  45. Lin DT, Holland SR, Rocha KM, Krueger RR. Method for optimizing topography-guided ablation of highly aberrated eyes with the Allegretto wave excimer laser. *J Refract Surg.* 2008;24:S439–45.
  46. Shaheen MS, El-Kateb M, Hafez TA, Piñero DP, Khalifa MA. Wavefront-guided laser treatment using a high-resolution aberrometer to measure irregular corneas: a pilot study. *J Refract Surg.* 2015;31:411–8.
  47. Camellin M, Arba-Mosquera S. Simultaneous aspheric wavefront-guided transepithelial photorefractive keratectomy and phototherapeutic keratectomy to correct aberrations and refractive errors after corneal surgery. *J Cataract Refract Surg.* 2010;36:1173–80.
  48. Kanellopoulos AJ, Binder PS. Management of corneal ectasia after LASIK with combined, same-day, topography-guided partial transepithelial PRK and collagen cross-linking: the Athens protocol. *J Refract Surg.* 2011;27:323–31.
  49. Sakla H, Altroudi W, Muñoz G, Albarrán-Diego C. Simultaneous topography-guided partial photorefractive keratectomy and corneal collagen cross-linking for keratoconus. *J Cataract Refract Surg.* 2014;40:1430–8.

### ***Late LASIK Postoperative Flap Complications***

50. Lichter H, Rusell GE, Waring III GO. Repositioning the Laser in situ keratomileusis flap at the slit lamp. *J Refract Surg.* 2004;20:166–9.
51. Muñoz G, Albarrán-Diego C, Sakla HF. Increased risk for flap dislocation with perioperative brimonidine use in femtosecond laser in situ keratomileusis. *J Cataract Refract Surg.* 2000;35:1338–42.
52. Muñoz G, Alió JL, Perez-Santonja JJ. Successful treatment of severe wrinkled corneal flap after laser in situ keratomileusis with deionized water. *Am J Ophthalmol.* 2000;29:91–2.
53. Donnenfeld ED, Perry HD, Doshi SJ. Hyperthermic treatment of post-LASIK corneal striae. *J Cataract Refract Surg.* 2004;30:620–5.
54. Hernández-Matamoros J, Iradier MT, Moreno E. Treating folds and striae after laser in situ keratomileusis. *J Cataract Refract Surg.* 2001;27:350–2.
55. Kuo IC, Jabbur NS, O'Brien TP. Photorefractive keratectomy for refractory laser in situ keratomileusis flap striae. *J Cataract Refract Surg.* 2008;34:330–3.

56. Jackson DW, Hamill MB, Koch DD. Laser in situ keratomileusis flap suturing to treat recalcitrant flap striae. *J Cataract Refract Surg.* 2003;29:264–9.
57. Baviera J. Dislocated flaps. How to solve free flaps with no marks or flap malposition. In: Alió JL, Azar DT, editors. *Management of complications in refractive surgery.* Berlin: Springer; 2008. p. 21–7.

### ***Therapeutic Flap Amputation***

58. Garcia-Gonzalez M, Gil-Cazorla R, Teus MA. Surgical flap amputation for central flap necrosis after laser in situ keratomileusis. *J Cataract Refract Surg.* 2009;35:2018–21. doi:[10.1016/j.jcrs.2009.05.045](https://doi.org/10.1016/j.jcrs.2009.05.045).
59. Kymionis GD, Kankariya VP, Kontadakis GA. Combined treatment with flap amputation, phototherapeutic keratectomy, and collagen crosslinking in severe intractable post-LASIK atypical mycobacterial infection with corneal melt. *J Cataract Refract Surg.* 2012;38:713–5. doi:[10.1016/j.jcrs.2012.01.009](https://doi.org/10.1016/j.jcrs.2012.01.009).
60. Katz T, Frings A, Richard G, Steinberg J, Druchkiv V, Linke SJ. Flap-induced astigmatism in eyes with sphere myopia correction: Superior hinge using a rotating microkeratome versus nasal hinge using a linear microkeratome. *J Cataract Refract Surg.* 2015;41:1160–7.
61. Rocha KM, Randleman JB, Stulting RD. Analysis of microkeratome thin flap architecture using Fourier-domain optical coherence tomography. *J Refract Surg.* 2011;27:759–63.
62. Stahl JE, Durrie DS, Schwendeman FJ, Boghossian AJ. Anterior segment OCT analysis of thin IntraLase femtosecond flaps. *J Refract Surg.* 2007;23:555–8.

# Chapter 10

## Complications and Management of SMILE

Anders Ivarsen and Jesper Hjortdal

### Introduction

As widely described in the previous chapters in this book, early 30 years ago, the excimer laser was introduced in the field of keratorefractive surgery, causing a revolution in the clinical approach to ocular refractive errors. Initially, excimer treatments were performed as surface ablation procedures; however, laser in situ keratomileusis (LASIK) with photoablation below a hinged corneal flap gradually became the preferred approach of most surgeons due to better postoperative comfort and a more stable postoperative refraction. Clinical outcome steadily improved over the years, with development of more sophisticated excimer lasers and the introduction of femtosecond lasers for cutting of the LASIK flap. Today LASIK is one of the most successful surgical procedures worldwide with a high precision and safety as well as an excellent patient satisfaction.

Despite the success of excimer laser keratorefractive surgery, potential disadvantages still exist. Thus, several factors influence the precision of the laser photoablation, including corneal hydration, room humidity, patient age, parallax error, and laser fluency [4, 45]. Furthermore, in surface ablation procedures postoperative wound healing may affect the long-term refractive outcome, with myopic regression and stromal haze formation as well-known complications of high myopic corrections [41]. In contrast, flap-related complications may occur after LASIK, including traumatic flap dislocation [16], dry eyes due to severed stromal nerves [30], and surgically induced keratectasia due to reduced biomechanical strength [11]. Although rare, these complications remain important challenges after excimer-based keratorefractive surgery. These issues are discussed deeply in designated chapters of this book.

---

A. Ivarsen MD, PhD (✉) • J. Hjortdal, MD, DMSci, PhD  
Department of Ophthalmology, Aarhus University Hospital, DK-8000, Aarhus C, Denmark  
e-mail: [ai@dadlnet.dk](mailto:ai@dadlnet.dk); [Jesper.hjortdal@dadlnet.dk](mailto:Jesper.hjortdal@dadlnet.dk)

## ***Refractive Lenticule Extraction***

Refractive lenticule extraction (ReLEx®) represents a new keratorefractive surgical approach that has evolved during the last few years. In ReLEx, a VisuMax® femtosecond laser (Carl Zeiss Meditec, Jena, Germany) is used to cut an intrastromal refractive lenticule that is subsequently removed from the cornea. The surgeon's access to the lenticule may be achieved via a LASIK-like flap (femtosecond lenticule extraction, FLEx) or through a peripheral, 2–4 mm wide tunnel (small incision lenticule extraction, SMILE) that causes minimal disturbance of the anterior stromal layers. Today, FLEx is primarily used as an introductory step for new ReLEx surgeons.

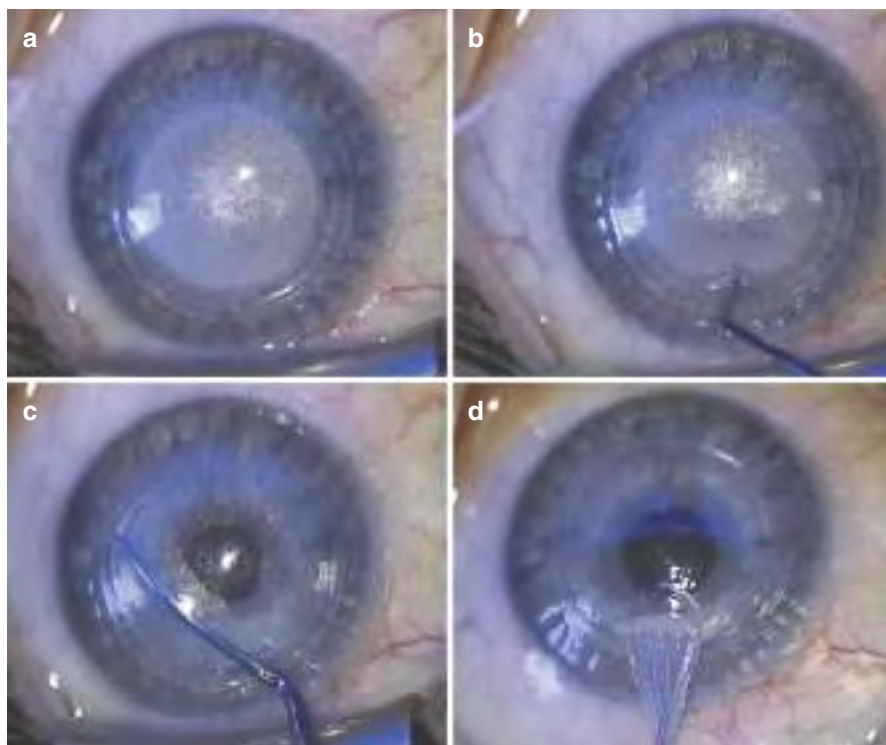
The current VisuMax femtosecond laser is a 500 kHz, 1043 nm solid-state Nd:Glass laser that generates pulses with an energy of approximately 150 nJ depending on the specific laser settings. Each laser pulse causes local photodisruption with creation of a small plasma bubble at the focal point. As individual cavitation bubbles fuse a cleavage plane is created within the stroma with minimal damage to the surrounding tissue. The Visumax uses a concave contact glass with a high numerical aperture to focus the laser within the corneal stroma. Individual pulses have a diameter of approximately 1  $\mu\text{m}$  and are usually placed at a distance of 3–5  $\mu\text{m}$  in a defined spiral pattern. A blinking fixation target facilitates alignment of the visual axis to the vertex of the contact glass, and suction at the limbus ensures stability of the globe during the laser procedure.

The posterior surface and the side of the refractive lenticule are cut first, followed by the anterior surface that is slightly enlarged in diameter to facilitate surgical manipulation. Finally, the access tunnel (or flap in FLEx) is fashioned. The entire laser treatment takes approximately 20 to 30 s depending on the exact laser settings. Following the laser procedure, the surgeon uses a blunt dissector or spatula to break any remaining tissue bridges and the lenticule is removed with a pair of forceps (Fig. 10.1). For further details on the surgical approach, please refer to [34, 36, 40].

Although SMILE is still a relatively new surgical procedure, studies from several centers have demonstrated a clinical outcome and patient satisfaction that is comparable to that of LASIK. A number of these studies have focused on patients with moderate to high myopia [14, 34–36, 40, 43, 44], but studies on correction for low myopia [23, 33, 52] or astigmatism [17, 19, 24, 54] have also demonstrated very good results. As in LASIK and in PRK the efficacy of SMILE for correcting lower myopia is better than in higher myopia.

RELEX is used today for correcting moderate and high myopia and myopic astigmatism. Currently the excising of a very thin lamelle as expected in very low myopic correction or retreatments and the excising a torus for correcting Hyperopia are in development and not commercially available. The efficacy, predictability and retreatment rate of myopic astigmatic SMILE correction is close to these of LASIK for the same corrections.

In a 1-year follow-up of 53 eyes with moderate myopia of 27 patients [35] 88 % had UDVA of logMAR 0 or better, 12 % of eyes lost 1 line of CDVA, while 31 % gained 1 line and 3 % gained 2 lines. The mean SE after 1 year was  $-0.19 \pm 0.19$ . no



**Fig. 10.1** (a) Appearance of the cornea immediately after the femtosecond laser cut. (b) Opening of the incision with a Sinsky hook. (c) Opening of the cleavage planes above and below the refractive lenticule with a blunt dissector. (d) Extraction of the lenticule through the small peripheral incision

serious complications were reported. In a recent retrospective study of 722 eyes with moderate and high myopia with astigmatism [13] 3 months post operatively a predictability of  $\pm 0.5$  D was achieved in 88% of eyes and 98% were within  $1 \pm 1$  D from emmetropia. 83% had UDVA of logMAR 0.1 or better. Loss of 2 lines or more of DCVA appeared in 1.6%. these and other studies demonstrate that the short time safety of SMILE is as good as in LASIK and PRK. Long term Safety with the 500 Hz SMILE platform is still not published but is expected to surpass the safety of LASIK due to assumed lower risk of ectasia.

In comparison with excimer laser procedures, ReLEx has several potential advantages. The approach allows parallax errors to be avoided, and in ReLEx the laser treatment is performed on the intact cornea and not on the exposed stroma as in LASIK or surface ablation procedures. Thus, the potential variability associated with changes in corneal hydration during excimer laser photoablation is circumvented, and ReLEx has in a number of studies been found to induce less higher order aberrations than LASIK [9, 12, 26], with better contrast sensitivity and potentially less visual deterioration under challenging lighting conditions.

SMILE causes only minimal trauma to the most anterior stromal layers and has been found to induce less inflammatory response than LASIK [10]. SMILE has also been demonstrated preserve stromal nerves to a higher degree than flap-based procedures [3, 15, 25, 29, 41, 42, 48] which appears reduce the risk of a post-operative dry eye [5, 15, 51]. Moreover, the biomechanical strength of the cornea has been suggested to be better after SMILE than after flap-based approaches [32, 39]; however, the biomechanical advantage has proven difficult to demonstrate with current clinical pneumatic force devices [1, 7, 22, 37, 38, 42, 44, 47, 50]. Still, SMILE in normal eyes is generally presumed to have a lower risk of iatrogenic keratectasia than flap-based procedures due to the layer of intact anterior stromal lamellae.

At present, the VisuMax laser allows myopic corrections from  $-0.50$  to  $-10$  diopters (D) in spherical equivalent refraction, with a cylinder of up to 5 D. Hyperopic treatments are not available, although clinical trials are ongoing. The VisuMax laser is CE (Conformité Européenne) marked and is currently under evaluation by the FDA (US Food and Drug Administration).

Since the first reports of ReLEx, the surgical approach has changed from FLEx to SMILE, the repetition rate of the VisuMax laser has been increased from 200 to 500 kHz, and the settings for laser spot size, energy, and distance have been optimized. All of these adjustments have influenced the clinical outcome after surgery, and should be taken into account when evaluating the procedure. However, most of these changes occurred before the platform became commercially available for SMILE surgery, why the present chapter focuses on publications reporting peri- or postoperative complications to SMILE with the current 500 kHz Visumax laser.

## Peri-operative Complications

Complications during SMILE surgery may be related to the laser procedure itself or to the subsequent dissection and removal of the refractive stromal lenticule. In general, peri-operative complications are relatively infrequent (Table 10.1) and have only been systematically evaluated in few publications [18, 31].

### *Suction Loss*

The Visumax uses low-pressure suction to steady the eye during the laser procedure. Safety-wise, a low-pressure system may be preferable to minimize intraocular stress. Furthermore, it allows the patient to visualize the green fixation light during the first part of the laser procedure. However, the combination of low suction and a relatively long laser treatment time of 20 s or more increases the risk of suction-loss while the refractive lenticule is being cut. Suction loss may occur at any time during the laser procedure, and the exact timing may influence the subsequent course of action taken by the surgeon. In cases where the posterior cut has been completed, suction may usually be re-established and the treatment continued. However, in



**Table 10.1** Perioperative complications

Epithelial defect at the incision	2.5–11 % (Vestergaard 2012, Sekundo 2011, Ivarsen, Ramirez-Miranda, Sekundo 2014)
Minor tear at the incision edge	2.1–6.1 % (Sekundo 2011, Ivarsen)
Suction loss	0.8–4.4 % (Ivarsen, Sekundo, Sekundo 2014, Wong, Ramirez-Miranda 2015)
Opaque bubble layer	?–4.4 % (Ramirez-Miranda 2015)
Black spots	?–3.8 % (Ramirez-Miranda 2015)
Lenticule extraction difficulties	2.2–3.8 % (Ivarsen, Sekundo 2014)
Central epithelial defect	0.3 % (Ivarsen 2014)
Cap perforation	0.3 % (Ivarsen 2014)
Large tear	0.1 % (Ivarsen 2014)

cases where the posterior cut is incomplete, the laser may not allow immediate retreatment since the re-established suction may cause minor lateral or anterior-posterior shifts that could affect the refractive properties of the posterior surface. Thus, conversion to LASIK or surface ablation has to be considered in cases with suction loss during cutting of the posterior surface, whereas immediate retreatment may be attempted in cases with suction loss at a later stage in the procedure.

The risk of suction loss during SMILE has been reported to be between 0.8 and 4.4 % [18, 31, 34, 35, 49]. In most of these studies only low numbers of patients have been examined, but in the largest study of 1574 eyes the overall risk of suction loss was only 0.8 % [18], suggesting that the surgeon learning curve may have an impact on the risk of suction loss. Fluid excess at the coupling interface may be a risk factor for suction loss as well, and patient anxiety appears also to be a contributing factor, since involuntary eye movements may easily break the relatively low suction. Thus mental preparation and perioperative reassurance of the patient is of paramount importance.

Only few publications have specifically evaluated the outcome after suction loss during SMILE [18, 49]. In one of these papers 7 out of 14 eyes were immediately re-treated with a successful outcome in 6 eyes but a complicated outcome and irregular astigmatism in one eye [18]. In the other paper, 6 of 8 SMILE treated eyes were immediately re-treated with success, although one eye was subsequently treated with surface ablation and application of Mitomycin C [49] to correct for a residual refractive error. Thus, although immediate re-treatment may be an option, the risk of complications should be carefully evaluated in each case, and conversion to LASIK or surface ablation considered.

### *Incomplete Cutting of the Refractive Lenticule*

There are no comprehensive reports on the frequency of incompletely cut lenticules, apart from cases associated with suction loss as described above. Thus, other causes appear to be rare and are only sporadically described in the literature; however, an

incomplete cut may occur at any timepoint in the laser-cutting procedure, including the access incision where opening with a diamond knife has been reported in a few papers [31, 34].

Formation of an opaque bubble layer (OBL) during the laser procedure is a known complication to the use of femtosecond lasers in the cornea. OBL represents spread of cavitation gas bubbles within the corneal stroma, and has been reported to affect cutting of LASIK flaps [20]. If the OBL spreads into untreated stroma in front of the laser pattern, it may give rise to incompletely cut areas and subsequent difficulties during dissection and extraction of the lenticule. The laser energy settings have major impact on the risk of OBL formation, and the appearance of a significant early OBL should lead to reduction of the laser energy. Although a single paper has reported significant OBL formation to affect cutting of the peripheral incision [31], the overall incidence of clinically important OBL appears to be very limited due to an overall lack of reports in the literature.

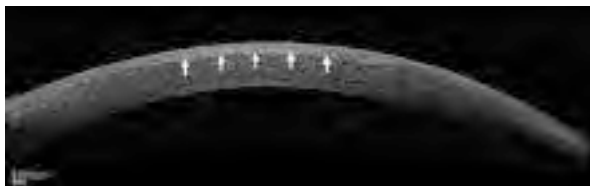Formation of black spots in the laser pattern due to air-bubbles or debris at the coupling-interface between the ocular surface and the contact glass has also been reported to give rise to difficult dissection of the refractive lenticule [31]. The authors observed black spots in 6 out of 160 eyes (3.8%) resulting in a more difficult lenticule dissection but without impact on the postoperative clinical outcome. However, to our knowledge, no other reports on black spots have been published, suggesting that the overall clinical importance may be limited. Meticulous wiping of the corneal surface prior to docking may reduce the incidence of black spots, and in cases with considerable air-bubbles or debris at the interface, re-docking with a new suction cup could be considered.

### ***Lenticule Extraction Difficulties***

In cases with an imperfect cut, dissection difficulties may lead to stromal irregularities at the interface or even to incomplete extraction of the refractive lenticule resulting in irregular astigmatism and potentially significant postoperative visual disturbances. Incomplete lenticule extraction may be demonstrated with anterior optical coherence tomography (Fig. 10.2), but has only been sporadically reported in the literature [6, 35], why the incidence remains unknown. However, several studies have reported occasional difficulties during lenticule extraction [18, 31, 34, 35]. In a large cohort, an incidence of 34 out of 1574 eyes (2.2%) was observed [18]. In 33 of these eyes the lenticule was eventually removed intact, whereas the procedure was abandoned in one eye and the patient was treated with surface ablation. Overall, difficult lenticule extraction was associated with an increased risk of slow visual recovery, taking months after surgery.

An attempt to treat very low degrees of myopia may, in theory, also increase the risk of difficulties during lenticule extraction, since a very thin lenticule may easily

**Fig. 10.2** Anterior optical coherence tomography demonstrating a lenticule remnant (*arrows*) at the stromal interface



tear. However, uncomplicated treatment of low myopia has been reported [23, 33, 52] in larger series, and it remains unknown whether the potentially increased risk of incomplete lenticule extraction is mostly theoretical.

### *Cap Perforation or Tear*

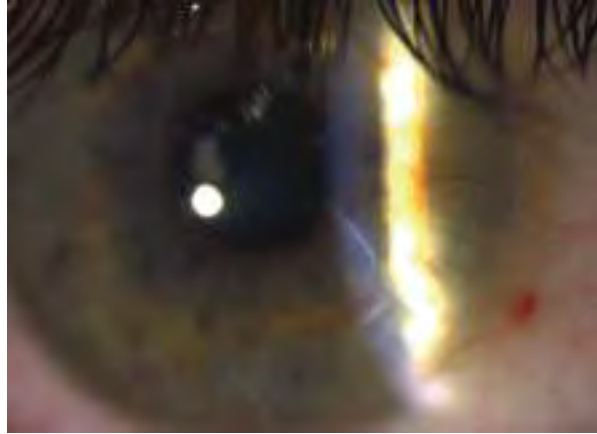In SMILE, the refractive lenticule is removed through a narrow, peripheral incision usually only 2–3 mm's in length. Due to the narrow access, manipulation during dissection or lenticule extraction may lead to small tears at the edges of the incision. An incidence of 2.1–6.1 % has been reported for these minor tears [18, 34] that were found to be without any impact on the postoperative clinical outcome. In rare cases with excessive manipulation or uncontrolled ocular movements, large tears in the cap may occur [18, 31]. In a series of 1574 eyes, the incidence of such tears was less than 0.1 % (1 eye), and in the specific case the tear was treated with a bandage contact lens and ended up having no impact on the long-term visual outcome [18].

Perforation of the cap is another rare complication that may occur in the periphery usually opposite the incision (Fig. 10.3). In the retrospective study of 1574 eyes, 4 instances of cap perforation were observed (0.25 %) that were all successfully treated with a bandage contact lens without any long-term postoperative consequences [18].

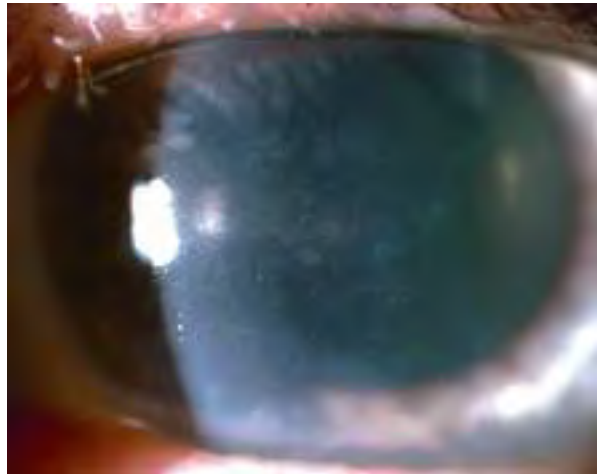
### *Epithelial Defects*

Minor epithelial defects at the incision are relatively common and have been reported in 2.5–11.3 % of treated eyes [18, 31, 34, 35, 40]. Most of these minor peripheral abrasions are healed already on day one, and have not been associated with any negative impact on the post-operative outcome. In contrast, large central epithelial defects are rare with an incidence of only 0.3 % [18]; however, these defects have been associated with post-operative interface inflammation and occasional clinically significant haze formation with transiently reduced post-operative visual acuity (Fig. 10.4).

**Fig. 10.3** Peripheral perforation of the cap 1 day after SMILE surgery



**Fig. 10.4** Diffuse haze at the stromal interface after SMILE



## Postoperative Complications

Complications after SMILE surgery in the postoperative period are primarily related to changes at the corneal surface or stromal interface, changes in the corneal refractive properties, or to postoperative infection. Overall, postoperative complications are relatively frequent (Table 10.2), although complications with significant impact on the postoperative visual outcome are rare.

### *Surface or Interface Related Complications*

Surface related changes are only rarely reported after SMILE. In one paper surface dryness was observed in 4.8% of eyes (n=75) on the first postoperative day, with resolution in all but 4 eyes during the first 3 months (Ivarsen). Severe dryness after

**Table 10.2** Postoperative complications

Microdistortions at Bowman's membrane	60 % (Luo)
Trace haze	4.0–19 % (Ivarsen, Kamiya, Sekundo 2014)
Transient surface dryness	4.8 % (Ivarsen)
Stromal microstriae	4.0–10 % (Sekundo 2011, Kamiya)
Late recovery of visual acuity	1.5 %
Epithelial islands near the incision	0.6–2.0 % (Sekundo 2011, Sekundo 2014, Ivarsen)
Fibre or debris at the interface	0.4 % (Ivarsen)
Monocular ghost images	0.4 % (Ivarsen)
Interface inflammation	0.3–1.6 % (Zhao 2015, Ivarsen 2014)
Keratitis	0.3 % (Ivarsen)

SMILE has not been reported and several papers have demonstrated that SMILE has little impact on stromal nerves and corneal sensation with less post-operative dryness than flap-based procedures [5, 10, 15, 51].

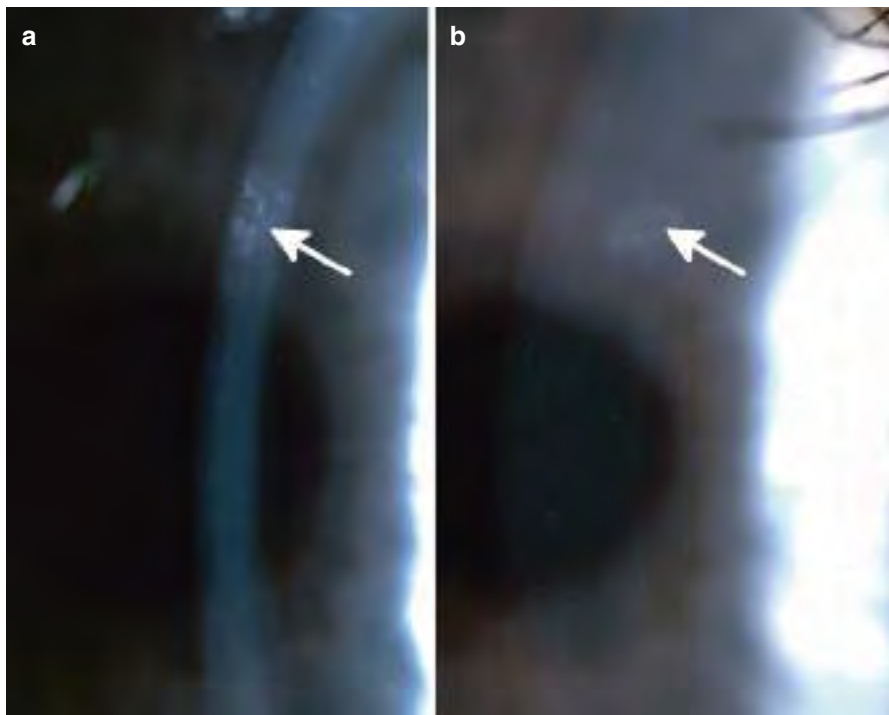
Clinically insignificant stromal microstriae have been observed in 4.0–10 % of eyes after SMILE [21, 22, 34]. Likewise, microdistortions have been demonstrated at Bowman's membrane using optical coherence tomography, and have been reported with an increasing frequency with higher myopic corrections [27, 53]. Although being reported in up to 60 % of eyes after 1 month, Bowman's microdistortions have not been found to be of clinical significance.

Development of interface haze has been reported in as many as 4–19 % of eyes after SMILE [18, 21, 22, 35] with transient haze grade 0.5 being most frequently observed. More severe haze appears to be rare, and haze grade 1 was seen in only 0.4 % of eyes 3 months after surgery in a large cohort of patients [18]. The same study found visual acuity to be significantly affected in only 0.1 % of eyes, with gradual improvement to preoperative levels during the following year.

Interface sterile inflammation is another rare cause of diffuse reflectivity that in one study was associated with the occurrence of central epithelial defects [18]. The reported incidence is 0.3–1.6 % [18, 55], and in all reports, the inflammation was controlled with a short course of topical steroids without development of late sequelae.

Minor islands of epithelial cells within the stromal interface near the incision have been observed in 0.6–2.0 % of SMILE treated eyes [18, 34, 35]. The islands usually have no impact on the postoperative outcome and have been found to gradually disappear without specific treatment in most cases, leaving only faint scars (Fig. 10.5) [18].

Small fibres or debris at the interface have also been infrequently reported after SMILE and irrigation may be considered in cases with centrally located opacities. However, minor peripherally located interface opacities may be left in situ and usually cause no symptoms or impact on the postoperative visual outcome [18].

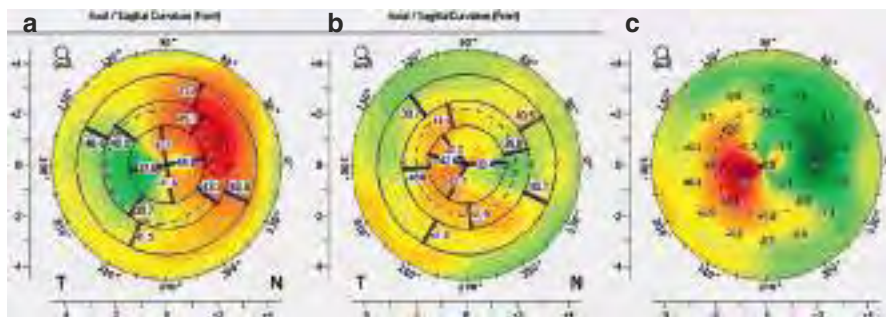


**Fig. 10.5** (a) Epithelial island (*arrow*) close to the peripheral incision 3 months after surgery. (b) Same eye 1 year after surgery, where the epithelial island has disappeared, leaving only a faint stromal scar (*arrow*)

### ***Complications Related to the Visual or Refractive Outcome***

A significant loss in corrected distance visual acuity (CDVA) of 2 or more lines has been reported in up to 2.3 % of eyes after 3 months [14]. In the largest study to date, all eyes with an initial loss in CDVA showed visual recovery, and gradually improved to within one line of their preoperative visual acuity during 1–2 years after surgery [18]. In most papers, no apparent cause for the delayed visual recovery has been identified; however, intraoperative lenticule extraction difficulties have been implicated in some eyes, as have postoperative irregular corneal topography, and increased stromal light-scatter [1, 2, 18].

Development of monocular ghost-images due to irregular postoperative corneal topography is another rare complication (Fig. 10.6a) that has been reported in 6 of 1574 eyes [18]. No apparent cause was identified in most eyes and perioperative complications were reported in only one eye. A conservative approach may be preferable, since gradual improvement will occur in most cases. However, in eyes with no improvement several months after SMILE, topography-guided PRK with application of perioperative Mitomycin C has been demonstrated as a useful approach to ameliorate the symptoms (Fig. 10.6b, c) [17, 19].



**Fig. 10.6** (a) Irregular topography 3 months after complicated SMILE surgery. (b) Topography 3 months after topography guided PRK with a 20 s application of Mitomycin C 0.02%. (c) Difference map showing the induced change in corneal topography from A to B

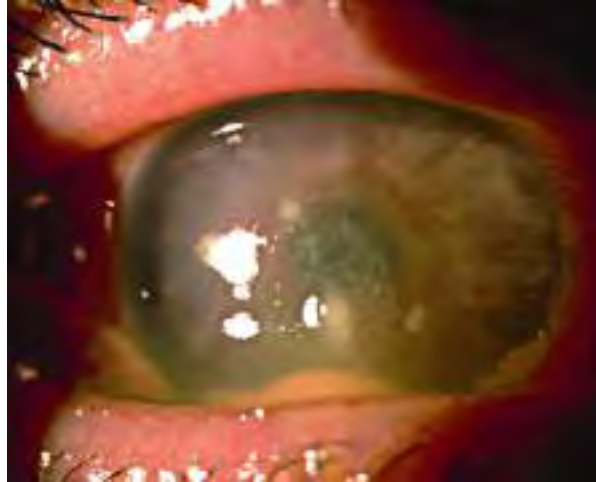### *Infectious Keratitis*

Development of microbial infiltrates at the stromal interface after SMILE is a rare but serious complication with a reported incidence of 0.3% (Fig. 10.7) [18]. Identification of the causative microorganism may be challenging to culture since it is difficult to obtain samples from the stromal interface. Preventive measures may include preoperative application of topical antibiotics or povidone iodine as well as a short course of topical antibiotics after surgery. Treatment strategies include topical antibiotics and irrigation of the stromal interface with antibiotic solution. The final outcome depends on the success of the treatment, and may, in worst case scenarios, lead to significantly reduced visual acuity and a need of further surgical interventions for visual rehabilitation.

### *Corneal Biomechanical Changes*

One of the most feared late complications after LASIK is development of iatrogenic keratectasia with development of a keratoconus like corneal topography [11]. In contrast to LASIK, SMILE leaves the anterior stromal lamellae nearly intact which has led to the assumption that the cornea is biomechanically stronger after SMILE than after LASIK and even PRK [32, 39]. However, clinical studies to support the biomechanical superiority of SMILE are few. Thus, there are contradictory reports on the biomechanical parameters after SMILE as measured with pneumatic force devices [28, 37, 38], and there has been limited success demonstrating significant differences between the various refractive procedures [1, 2, 7, 21, 22, 37, 43, 44, 47, 50]. To further complicate matters, two papers have recently reported clinically evident keratectasia after SMILE [8, 46]; however, in both cases forme fruste keratoconus was evident in the preoperative topography. Thus, iatrogenic keratectasia has not yet been demonstrated after SMILE in eyes with normal preoperative

**Fig. 10.7** Microbial keratitis a few days after SMILE. The exact pathogen was not identified, but the patient responded favourably to treatment with topical Moxifloxacin and Chloramphenicol as well as irrigation of the interface with Cefuroxime



topography, but further evidence to clarify the biomechanical impact of SMILE is needed and at present patient selection and treatment should be performed with the same caution as for all other keratorefractive procedures.

## Conclusions

SMILE represents a fundamentally different surgical approach to the correction of refractive errors than excimer laser based methods such as PRK or LASIK. Due to the nature of the treatment, SMILE is technically more demanding and has a number of different peri- and postoperative complications. Still, despite the more difficult surgical approach, complications with significant clinical impact are few and overall of the same magnitude as those seen after excimer based techniques. Furthermore, as outlined in the introduction, SMILE has several potential benefits over LASIK, including less induction of higher order aberrations, less disruption of stromal nerves, and possibly better post-operative biomechanical strength. Thus, although the technology is still very new, SMILE has already proven its potential and is being used in an increasing number of surgical centres all over the world. The technique is still only available on a single platform, but it will be of considerable interest to witness the development and evolution in refractive lenticule extraction that is bound to occur over the next few years.

## References

1. Agca A, Ozgurhan EB, Demirok A, Bozkurt E, Celik U, Ozkaya A, Cankaya I, Yilmaz OF. Comparison of corneal hysteresis and corneal resistance factor after small incision lenticule extraction and femtosecond laser-assisted LASIK: a prospective fellow eye study. *Cont Lens Anterior Eye*. 2014;37(2):77–80.



2. Agca A, Ozgurhan EB, Yildirim Y, Cankaya KI, Guleryuz NB, Alkin Z, Ozkaya A, Demirok A, Yilmaz OF. Corneal backscatter analysis by in vivo confocal microscopy: fellow eye comparison of small incision lenticule extraction and femtosecond laser-assisted LASIK. *J Ophthalmol*. 2014;2014:265012.
3. Agca A, Cankaya KI, Yilmaz I, Yildirim Y, Yasa D, Olcucu O, Demircan A, Demirok A, Yilmaz OF. Fellow Eye comparison of nerve fiber regeneration after SMILE and femtosecond laser-assisted LASIK: a confocal microscopy study. *J Refract Surg*. 2015;31(9):594–8.
4. Ang EK, Couper T, Dirani M, Vajpayee RB, Baird PN. Outcomes of laser refractive surgery for myopia. *J Cataract Refract Surg*. 2009;35(5):921–33.
5. Denoyer A, Landman E, Trinh L, Faure JF, Auclin F, Baudouin C. Dry eye disease after refractive surgery: comparative outcomes of small incision lenticule extraction versus LASIK. *Ophthalmology*. 2015;122(4):669–76.
6. Dong Z, Zhou X. Irregular astigmatism after femtosecond laser refractive lenticule extraction. *J Cataract Refract Surg*. 2013;39(6):952–4.
7. Dou R, Wang Y, Xu L, Wu D, Wu W, Li X. Comparison of corneal biomechanical characteristics after surface ablation refractive surgery and novel lamellar refractive surgery. *Cornea*. 2015;34(11):1441–6.
8. El-Naggar MT. Bilateral ectasia after femtosecond laser-assisted small-incision lenticule extraction. *J Cataract Refract Surg*. 2015;41(4):884–8.
9. Ganesh S, Gupta R. Comparison of visual and refractive outcomes following femtosecond laser-assisted lasik with smile in patients with myopia or myopic astigmatism. *J Refract Surg*. 2014;30(9):590–6.
10. Gao S, Li S, Liu L, Wang Y, Ding H, Li L, Zhong X. Early changes in ocular surface and tear inflammatory mediators after small-incision lenticule extraction and femtosecond laser-assisted laser in situ keratomileusis. *PLoS One*. 2014;9(9):e107370.
11. Geggel HS, Talley AR. Delayed onset keratectasia following laser in situ keratomileusis. *J Cataract Refract Surg*. 1999;25:582–6.
12. Gyldenkerne A, Ivarsen A, Hjortdal JØ. Comparison of corneal shape changes and aberrations induced By FS-LASIK and SMILE for myopia. *J Refract Surg*. 2015;31(4):223–9.
13. Hansen RS, Lyhne N, Grauslund J, Vestergaard AH. Small-incision lenticule extraction (SMILE): outcomes of 722 eyes treated for myopia and myopic astigmatism. *Graefes Arch Clin Exp Ophthalmol*. 2016;254(2):399–405.
14. Hjortdal JØ, Vestergaard AH, Ivarsen A, Rangunathan S, Asp S. Predictors for the outcome of small-incision lenticule extraction for Myopia. *J Refract Surg*. 2012;28(12):865–71.
15. Ishii R, Shimizu K, Igarashi A, Kobashi H, Kamiya K. Influence of femtosecond lenticule extraction and small incision lenticule extraction on corneal nerve density and ocular surface: a 1-year prospective, confocal, microscopic study. *J Refract Surg*. 2015;31(1):10–5.
16. Iskander NG, Peters NT, Anderson Penno E, Gimbel HV. Late traumatic flap dislocation after laser in situ keratomileusis. *J Cataract Refract Surg*. 2001;27:1111–4.
17. Ivarsen A, Hjortdal J. Correction of myopic astigmatism with small incision lenticule extraction. *J Refract Surg*. 2014;30(4):240–7.
18. Ivarsen A, Asp S, Hjortdal J. Safety and complications of more than 1500 small-incision lenticule extraction procedures. *Ophthalmology*. 2014;121(4):822–8.
19. Ivarsen A, Hjortdal JØ. Topography-guided photorefractive keratectomy for irregular astigmatism after small incision lenticule extraction. *J Refract Surg*. 2014;30(6):429–32.
20. Jung HG, Kim J, Lim TH. Possible risk factors and clinical effects of an opaque bubble layer created with femtosecond laser-assisted laser in situ keratomileusis. *J Cataract Refract Surg*. 2015;41(7):1393–9.
21. Kamiya K, Shimizu K, Igarashi A, Kobashi H. Visual and refractive outcomes of femtosecond lenticule extraction and small-incision lenticule extraction for myopia. *Am J Ophthalmol*. 2014;157(1):128–134.e2.
22. Kamiya K, Shimizu K, Igarashi A, Kobashi H, Sato N, Ishii R. Intraindividual comparison of changes in corneal biomechanical parameters after femtosecond lenticule extraction and small-incision lenticule extraction. *J Cataract Refract Surg*. 2014;40(6):963–70.

23. Kim JR, Kim BK, Mun SJ, Chung YT, Kim HS. One-year outcomes of small-incision lenticule extraction (SMILE): mild to moderate myopia vs. high myopia. *BMC Ophthalmol.* 2015;15:59.
24. Kobashi H, Kamiya K, Ali MA, Igarashi A, Elewa ME, Shimizu K. Comparison of astigmatic correction after femtosecond lenticule extraction and small-incision lenticule extraction for myopic astigmatism. *PLoS One.* 2015;10(4):e0123408.
25. Li M, Zhou Z, Shen Y, Knorz MC, Gong L, Zhou X. Comparison of corneal sensation between small incision lenticule extraction (SMILE) and femtosecond laser-assisted LASIK for myopia. *J Refract Surg.* 2014;30(2):94–100.
26. Lin F, Xu Y, Yang Y. Comparison of the visual results after SMILE and femtosecond laser-assisted LASIK for myopia. *J Refract Surg.* 2014;30(4):248–54.
27. Luo J, Yao P, Li M, Xu G, Zhao J, Tian M, Zhou X. Quantitative analysis of microdistortions in Bowman's layer using optical coherence tomography after SMILE among different myopic corrections. *J Refract Surg.* 2015;31(2):104–9.
28. Mastropasqua L, Calienno R, Lanzini M, Colasante M, Mastropasqua A, Mattei PA, Nubile M. Evaluation of corneal biomechanical properties modification after small incision lenticule extraction using Scheimpflug-based noncontact tonometer. *Biomed Res Int.* 2014;2014:290619.
29. Mohamed-Noriega K, Riau AK, Lwin NC, Chaurasia SS, Tan DT, Mehta JS. Early corneal nerve damage and recovery following small incision lenticule extraction (SMILE) and laser in situ keratomileusis (LASIK). *Invest Ophthalmol Vis Sci.* 2014;55(3):1823–34.
30. Pérez-Santonja JJ, Sakla HF, Cardona C, Chipont E, Alió JL. Corneal sensitivity after photorefractive keratectomy and laser in situ keratomileusis for low myopia. *Am J Ophthalmol.* 1999;127:497–504.
31. Ramirez-Miranda A, Ramirez-Luquin T, Navas A, Graue-Hernandez EO. Refractive lenticule extraction complications. *Cornea.* 2015;34 Suppl 10:S65–7.
32. Reinstein DZ, Archer TJ, Randleman JB. Mathematical model to compare the relative tensile strength of the cornea after PRK, LASIK, and small incision lenticule extraction. *J Refract Surg.* 2013;29(7):454–60.
33. Reinstein DZ, Carp GI, Archer TJ, Gobbe M. Outcomes of small incision lenticule extraction (SMILE) in low myopia. *J Refract Surg.* 2014;30(12):812–8.
34. Sekundo W, Kunert KS, Blum M. Small incision corneal refractive surgery using the small incision lenticule extraction (SMILE) procedure for the correction of myopia and myopic astigmatism: results of a 6 month prospective study. *Br J Ophthalmol.* 2011;95(3):335–9.
35. Sekundo W, Gertner J, Bertelmann T, Solomatin I. One-year refractive results, contrast sensitivity, high-order aberrations and complications after myopic small-incision lenticule extraction (ReLEx SMILE). *Graefes Arch Clin Exp Ophthalmol.* 2014;252(5):837–43.
36. Shah R, Shah S, Sengupta S. Results of small incision lenticule extraction: all-in-one femtosecond laser refractive surgery. *J Cataract Refract Surg.* 2011;37(1):127–37.
37. Shen Y, Chen Z, Knorz MC, Li M, Zhao J, Zhou X. Comparison of corneal deformation parameters after SMILE, LASEK, and femtosecond laser-assisted LASIK. *J Refract Surg.* 2014;30(5):310–8.
38. Shen Y, Zhao J, Yao P, Miao H, Niu L, Wang X, Zhou X. Changes in corneal deformation parameters after lenticule creation and extraction during small incision lenticule extraction (SMILE) procedure. *PLoS One.* 2014;9(8):e103893.
39. Sinha Roy A, Dupps Jr WJ, Roberts CJ. Comparison of biomechanical effects of small-incision lenticule extraction and laser in situ keratomileusis: finite-element analysis. *J Cataract Refract Surg.* 2014;40(6):971–80.
40. Vestergaard A, Ivarsen AR, Asp S, Hjortdal JØ. Small-incision lenticule extraction for moderate to high myopia: Predictability, safety, and patient satisfaction. *J Cataract Refract Surg.* 2012;38(11):2003–10.
41. Vestergaard AH, Hjortdal JØ, Ivarsen A, Work K, Grauslund J, Sjølie AK. Long-term outcomes of photorefractive keratectomy for low to high myopia: 13 to 19 years of follow-up. *J Refract Surg.* 2013;29(5):312–9.
42. Vestergaard AH, Grønbech KT, Grauslund J, Ivarsen AR, Hjortdal JØ. Subbasal nerve morphology, corneal sensation, and tear film evaluation after refractive femtosecond laser lenticule extraction. *Graefes Arch Clin Exp Ophthalmol.* 2013;251(11):2591–600.

43. Vestergaard AH, Grauslund J, Ivarsen AR, Hjortdal JØ. Central corneal sublayer pachymetry and biomechanical properties after refractive femtosecond lenticule extraction. *J Refract Surg.* 2014;30(2):102–8.
44. Vestergaard AH, Grauslund J, Ivarsen AR, Hjortdal JØ. Efficacy, safety, predictability, contrast sensitivity, and aberrations after femtosecond laser lenticule extraction. *J Cataract Refract Surg.* 2014;40(3):403–11.
45. Walter KA, Stevenson AW. Effect of environmental factors on myopic LASIK enhancement rates. *J Cataract Refract Surg.* 2004;30(4):798–803.
46. Wang Y, Cui C, Li Z, Tao X, Zhang C, Zhang X, Mu G. Corneal ectasia 6.5 months after small-incision lenticule extraction. *J Cataract Refract Surg.* 2015;41(5):1100–6.
47. Wang D, Liu M, Chen Y, Zhang X, Xu Y, Wang J, To CH, Liu Q. Differences in the corneal biomechanical changes after SMILE and LASIK. *J Refract Surg.* 2014;30(10):702–7.
48. Wei S, Wang Y. Comparison of corneal sensitivity between FS-LASIK and femtosecond lenticule extraction (ReLEx flex) or small-incision lenticule extraction (ReLEx smile) for myopic eyes. *Graefes Arch Clin Exp Ophthalmol.* 2013;251(6):1645–54.
49. Wong CW, Chan C, Tan D, Mehta JS. Incidence and management of suction loss in refractive lenticule extraction. *J Cataract Refract Surg.* 2014;40(12):2002–10.
50. Wu D, Wang Y, Zhang L, Wei S, Tang X. Corneal biomechanical effects: small-incision lenticule extraction versus femtosecond laser-assisted laser in situ keratomileusis. *J Cataract Refract Surg.* 2014;40(6):954–62.
51. Xu Y, Yang Y. Dry eye after small incision lenticule extraction and LASIK for myopia. *J Refract Surg.* 2014;30(3):186–90.
52. Xu Y, Yang Y. Small-incision lenticule extraction for myopia: results of a 12-month prospective study. *Optom Vis Sci.* 2015;92(1):123–31.
53. Yao P, Zhao J, Li M, Shen Y, Dong Z, Zhou X. Microdistortions in Bowman's layer following femtosecond laser small incision lenticule extraction observed by Fourier-domain OCT. *J Refract Surg.* 2013;6:1–7.
54. Zhang J, Wang Y, Wu W, Xu L, Li X, Dou R. Vector analysis of low to moderate astigmatism with small incision lenticule extraction (SMILE): results of a 1-year follow-up. *BMC Ophthalmol.* 2015;15:8.
55. Zhao J, He L, Yao P, Shen Y, Zhou Z, Miao H, Wang X, Zhou X. Diffuse lamellar keratitis after small-incision lenticule extraction. *J Cataract Refract Surg.* 2015;41(2):400–7.

# Chapter 11

## Complications and Management in Laser Refractive Surface Ablation (SA)

Johannes Steinberg and Stephan J. Linke

### Introduction

This chapter gives an overview on one of the oldest, but still indispensable corneal refractive laser surgery strategy. Whereas the currently most often performed corneal refractive strategies involve the creation of corneal lamellae either on the surface (LASIK) or within the corneal stroma (SMILE®), surface ablation (SA) aims to reshape the corneal curvature by directly ablating the corneal surface. SA was the first corneal refractive treatment performed with an Excimer-laser-system and thereby completely changed the world of refractive surgery. The oldest realized SA was the photorefractive keratectomy (PRK). It pioneered the field of laser-refractive-surgery more than 30 years ago and has been approved by the United States Food and Drug Administration (US FDA) in 1995 [1, 2]. The common principle of SA strategies is to remove the corneal epithelium either solely mechanically, with the aid of alcohol or with the Excimerlaser itself (see Table 11.1). After performing the abrasio, the laser ablates the corneal tissue using an ultraviolet 193 nm wavelength beam with a mixture of argon-fluorine gas serving as the energy source. Modern Excimer-laser systems work with pulse frequencies of 200–500 Hz. The corneal tissue absorbs the emitted laser-energy, so the effect concentrates on the surface without altering the deeper layer of the cornea. The binding energy of the corneal molecules is 3.6–6.4 eV. During the photoablation, the laser bursts these

---

J. Steinberg, MD (✉)  
zentrumsehstärke, Martinistr. 64, Hamburg 20251, Germany  
e-mail: [steinberg@zentrumsehstaerke.de](mailto:steinberg@zentrumsehstaerke.de)

S.J. Linke, MD, PhD  
Department of Ophthalmology, University Medical Center Hamburg Eppendorf,  
Martinistr. 52, 20246 Hamburg, Germany

CareVision Germany, Martinistr. 52, 20246 Hamburg, Germany

**Table 11.1** Techniques of epithelial removal in surface ablation (SA)

SA method	PRK-Photo Refractive Keratectomy	LASEK-Laser Assisted Sub Epithelial Keratectomy	Epi-LASIK "Epi-off"	Epi-LASIK "Epi-on"	Trans Epithelial PRK (t-PRK)
Epithelial removal	Mechanical scraping with a blunt blade or rotating brush	The Epithelium is detached from underlying Bowman with 20 % alcohol, using a metal funnel or a soaked sponge for 30 s	Automated microseparator peels the epithelium from Bowman. The epithelium flap is discarded.	Automated microseparator peels the epithelium from Bowman creating an epithelial flap with hinge. The epithelium flap is repositioned after the ablation.	The superior 50 µ corneal layer is ablated using the excimer laser before the refractive ablation.
Pros		Clean removal of epithelium. Less traumatic than PRK	No alcohol irritation	No alcohol irritation Theoretic faster healing and less pain.	Exact optical zone, "no touch" technique
Cons	Inadvertdant damage to Bowman. Risk of uneven surface and stroma	Irritation by alcohol	Cost of vacuum ring and motorized separator.	Cost of vacuum ring and motorized separator.	Unpredictable refractive effect due to non homogene epithelial thickness

inter-molecule-connections [3–5]. The released kinetic energy of the free protons results in a smoke emission observable during the treatment. Thus, almost no photodisruptive or thermic damage to the surrounding corneal tissue occurs [6].

The high energy, the short impulses, the flying-spot-technology and the high absorption-rate within the corneal tissue lead to a highly precise, controlled and tissue-saving procedure, with an ablation of only 0.6 mm<sup>2</sup> and a depth of only 0.25 µm per pulse [7]. The differences and special characteristics of the SA – strategies are summarized in Table 11.1.

## Historical Review

The PRK displays the oldest SA strategy, first in-vivo performed on a blind human eye in 1985 by Theo Seiler [2]. Back then, the epithelium has been removed solely mechanically. A drawback of this strategy was the risk of damaging the Bowman-layer in case of rough debridement due to very adherent epithelium and the high release of cytokines due to the massive (epithelial-) cellular trauma. Further attempts to improve the PRK led to alcohol assisted strategies first reported in 1996 [8]. The applied alcohol losses the epithelial – basement membrane adhesion, so less mechanical force has to be used to completely remove the epithelium. Concurrently, the anchoring of the basement membrane to the underlying Bowman layer doesn't get affected [9]. By preserving the Bowman layer as an intact barrier and avoiding an excessive cytokine-release due to epithelial damage during the first step of the procedure, the advances of the SA-strategies aim to reduce the inflammatory reaction of the underlying stroma. After inventing a simple way to remove the epithelium without the need of extensive mechanical force, the next historical step was to remove the entire epithelium in the form of a superficial flap. This can be done with a special funnel allowing to apply the alcohol within a predefined diameter and period of time and a trepan to circularly cut the loosened epithelium for 270° down to the Bowman lamella before bluntly lifting the epithelial flap ('epi-on'-procedure) or alternatively cutting the epithelium 360° and removing the flap without replacing him after the photoablation ('epi-off'-procedure). This 'laser epithelial keratomileusis' has firstly been called LASEK in 1998 [10]. In 2003, another SA strategy called Epi-LASIK was has been introduced [11]. Thereby, after stabilized by a suction-ring, a blunt oscillating 'plane' separates the epithelium and the adherent basement membrane from the Bowman lamella. As an advantage, the Epi-LASIK completely avoids the usage of cytotoxic and the potential irritating alcohol solution. As in LASEK and also displayed in Table 11.1, epi-on and epi-off strategies are possible. Despite the theory of a reduced inflammatory response of the corneal stroma in 'epi-on'-strategies, clinical studies couldn't demonstrate a real benefit [12, 13]. Therefore, most of the LASEK and Epi-LASIK surgeons prefer epi-of strategies (see also Chap. 11).

The latest strategy for epithelial removal in SA is the transepithelial PRK (t-PRK). Thereby, the epithelium gets removed by the Excimer-laser itself. Advantages are the simple and time-saving execution and the possibility to also remove epithelium involving scar-tissue without causing an irregular ablation.

A further potential benefit is the immediate evaporation of cytokines released by the damaged epithelium-cells, although the clinical benefit seems to be only minor [14].

Despite modern t-PRK programs considering the differences in central and peripheral thickness of the epithelial layer, a potential disadvantage is the risk of over- or under- correction due to a fixed ablation profile for the epithelial removal [15]. This might lead to partially remaining epithelial cells or partially ablated Bowman-lamella after the first step t-PRK. In this case the second step (Excimer photoablation of the corneal stroma) might not be as predictable as thought [14].

In modern refractive surgery, despite displaying the ‘oldest’ laser-refractive strategy, SA still has a high range of applications:

- Refractive treatment in particularly thin, steep or flat corneas or eyes with small palpebral fissures or deep position in the orbital cavity.
- Refractive treatment in patients with high risk of mechanical eye trauma (military special forces, contact-sports).
- Refractive treatment in patients with corneal irregularities (i.e., topography guided PRK).
- Refractive treatment in patients with epithelial basement membrane dystrophies/irregularities (PRK).
- Re-treatment option after LASIK or SMILE, if a flaplift (LASIK) or another lenticule extraction (SMILE) is not suitable.

Combining these results with the better biomechanical stability after treatment, the SA – strategies should not be underrated as an effective treatment option in the arsenal of modern corneal refractive laser treatments [16].

## **Complications and Management in Laser Refractive Surface Ablation (SA)**

Johannes Steinberg

The terminus Surface ablation (SA) combines a variety of different corneal refractive laser methods, which unifies their Excimer-based laser-ablation on the bowman-lamella. The SA – techniques, including PRK, LASEK and Epi-LASIK, have been described in the first chapter of this book. Next to general complications of corneal laser vision correction like decentered ablation and corneal ectasia, SA includes some procedure-specific challenges and complications, which are addressed in the following section:

### **Intraoperative Complications**

#### ***Irregular Ablation***

First step of SA is the removal of corneal epithelium. In PRK, the debridement can be done mechanically, laser-assisted or ethyl-alcohol-assisted. In LASEK as well as

in Epi-LASIK, the epithelium is removed after creating an epithelial flap. The common goal of the first step of SA is to ensure a homogenous and epithelium-free bowman exposure for the following Excimer-ablation. If the epithelium has not been removed completely due to careless epithelium debridement or in case of epithelium-involving corneal scars, the risk of an irregular ablation is high. Also a potential Bowman-defect after using the Epi-LASIK Microkeratom can lead to an irregular corneal surface and thereby increase the risk of an irregular ablation. The risk is also increased, if the photoablation starts with a significantly prolonged time delay after epithelial removal due to an increased uneven evaporation of H<sub>2</sub>O. This might lead to a consecutive local (irregular refractive results) or general (refractive overcorrection) thinning of the dehydrated corneal tissue. Also the direct biochemical reaction of the corneal stroma to the (too long or in a too high concentration) administered alcohol in PRK or LASEK can lead to an unpredictable and irregular ablation. Though removal of the corneal epithelium with 20% ethanol for up to 40 s is safe to the underlying corneal stroma, alcohol is known to be potentially cytotoxic by causing intra- and extra-cellular protein denaturation and thereby affecting or even permanently damaging regular cell-function [17, 18].

If the irregularity of the stromal bed is only small, the epithelium might smoothen the surface after reepithelialisation by local thickening or thinning. On the other hand, if the irregularity is too severe, higher order aberrations leading to halos, loss of visual quality and – acuity and thereby a decrease of the safety as well as the efficacy of the procedure might occur.

### ***Practical Recommendations***

In PRK, I prefer using a small sponge soaked with 20% alcohol and rubbing the sponge over the corneal epithelium for 30 s with smooth pressure in concentric circles. Thereby the epithelium often loosens without further need of using a scraping instrument. With this technique, the debridement usually starts in the central area, so you can remove the epithelium while using only the alcohol-soaked sponge and avoiding excessive manipulating the central area. After 30 s, I gently remove the remaining epithelium continuing my circuiting movement. Then I remove the epithelium within a diameter of about 9–10 mm (subtotal abrasion) and swiftly sweep the surface with a dry sponge to ensure a homogenous corneal surface avoiding remaining loose epithelium or local concentration of fluids. Doing this, you have to keep in mind not spending too much time to avoid excessive evaporation.

Further potential risks for irregular corneal ablation in corneal refractive surgery are epithelium-involving scars prior to the treatment. Theoretically, performing SA is possible, if the scar does not involve the central area and the patient has a good corrected visual acuity, no disturbing visual field defects or halos before treatment.

In every case of corneal scars, it is of outermost importance to clarify the underlying pathology. In case of a rheumatic disease with corneal involvement, PRK should not be performed because of the risk of a recurrence and even increased and unpredictable autoimmune activity. Performing SA in corneas with a herpetic scar embodies the risk of a recurrence and thereby a high risk of endothelial, stromal or epithelial keratitis leading delayed wound healing and ultimately of permanent



visual impairment. Still, some positive results of phototherapeutic keratectomy (PTK) [18] and few positive case reports of LASIK [19, 20] after herpes keratitis exist, which support the possibility of treating even such high risk patients. I personally wouldn't do SA in such cases especially because of the risk of prolonged (epithelial) wound healing which could potentially leading to bacterial infection, vascularization, calcification and corneal stromal scarring, but I know colleagues, which do treat patients after herpes keratitis with LASIK, which has the benefit of a covered wound-bed and therefore minimizes the risk of prolonged irritation. The co-editor of this book (TK) advises to avoid refractive corneal surgery if herpes infection was known in the last 6 months, and to start a systemic Acyclovir therapy (400 mg  $\times$  3 per day) a few days before the planned LASIK and continue 2 weeks afterwards in case of herpes keratitis or herpes labialis episodes that appeared 6 months earlier or more before the refractive procedure. Similar regimen is advisable before and after PRK. Anecdotal reports of persistent epithelial erosion after PRK in the presence of recent herpes labialis or reports of recurrent herpes keratitis several weeks or later after PRK speculate that the combination of epithelial erosion, local cortisone therapy and contact lens may accelerate the reactivation of pre-existing herpes infection [21]. Published data for herpes keratitis recurrence after PRK are derived from prospectively testing rabbit eyes [22]. Rabbits treated with systemic Valaciclovir in a dose of 150/mg per kg intraperitoneal were the only ones after PRK treatment without any signs of recurrence. Topical acyclovir was not sufficient in avoiding a recurrent inflammatory reaction. A study group from New Zealand analyzing herpes recurrence after LASIK in rabbit eyes, demonstrated, that 100 and 200 mg/kg/day Valaciclovir are equally effective to prevent recurrence of the herpes keratitis (1/122 cases in their rabbit cohort) [23].

If the cause for the corneal scar was a sterile (for example contact-lens associated) or bacterial keratitis or a mechanical or chemical trauma, you can perform a PRK without extra precautions but, in every case of corneal scars, you should wait at least 1 year after the scar-causing event to ensure refractive stable preconditions and the distance corrected visual acuity should be within normal range preoperatively.

Above, if you decide to perform SA in the presence of a corneal scar, you should not do LASEK or Epi-LASIK but choose PRK, to avoid incomplete epithelial removal. Further, you have to ablate the epithelium and the involving superficial scar with the excimer laser (transepithelial PRK; t-PRK) instead of using alcohol to ensure a homogenous corneal surface before using the Excimer laser for the refractive correction. In cases of superficial, paracentral or mid-peripheral corneal scars and the request for corneal refractive laser treatment, I perform a 50  $\mu$ m deep, aspherical plano epithelial ablation (PTK) before using the Excimer laser for the intended refractive correction. Despite good safety, a prospective study demonstrated a reduced efficacy after t-PRK compared to alcohol-PRK with slightly reduced uncorrected distance visual acuity (UDVA) 1 year after the treatment due to a refractive undercorrection [24]. Not only because of these findings, it is important to talk with your laser-manufacturer/provider regarding special regulations/different nomograms prior to performing t-PRK. Above, I recommend performing only myopic PRK in case of central/paracentral or mid-peripheral corneal scars because

of the central ablation profile. The refractive result of the mid-peripheral hyperopic ablation strategy depends on a weakened paracentral tissue, resulting in a central steepening of the cornea. If the biomechanic properties of the cornea are changed due to the corneal scar, the central shaping of the cornea might become unpredictable which might lead to under-, or overcorrection or even an irregular corneal surface. If the corneal scar involves the central cornea, and thereby leads to a decreased visual acuity or other disturbing visual phenomena, you should treat the cornea with a PTK first, to remove the scar. Only in case of an improved VA and stable refraction after the PTK, you might consider the option of performing a PRK in a second step. Again, I do not recommend creating an epithelial flap (LASEK-“Epi on”, Epi-LASIK) in case of a pre-treated or otherwise altered corneal surface.

Considering all these safety regulations, the PRK is excellent for refractive treatment in eyes with central/paracentral or mid-peripheral corneal scars because of its surface ablation strategy. In contrast, using lamellar-Femtolasar based refractive strategies, you have a risk of persisting tissue bridges and incomplete cutting reducing the safety and efficacy of the treatment, as discussed later in this book.

Pain and slow visual recovery time of 4–6 weeks are normal and represent the most important reasons for surgeons and patients to choose alternative refractive procedures for vision correction, if possible.

## *Pain*

Despite pain is no real complication after SA, it represents one of the most important aspects in SA. The treatment leads to a disintegrated surface with severed corneal nerves and an exposed wound bed. This results in an increased activity of the exposed nerve fibers causing a release of pain modulators including prostaglandins and neuropeptides [25].

Other than in PRK, LASEK and Epi-LASIK allow to replace the epithelium after the excimer-photoablation to cover the wound (‘epi-on’ procedure; see Chap. 1). Albeit the epithelium-flap displays a mechanical protection to the wound, it consists of mainly dead epithelial cells which are replaced by epithelial proliferation and migration. Therefore, it is not surprising, that several studies could not demonstrate a significant difference in re-epithelialization time or pain-level between flap-on and flap-off techniques in Epi-LASIK and LASEK [26, 27]. Still, there are other studies demonstrating faster re-epithelialization after “flap-on” procedures [28, 29]. These conflicting results are mainly caused by different methods used for gathering and analyzing the results. A recently conducted prospective study by Eliacik et al. compare epithelial healing time and pain after LASEK and PRK using anterior segment OCT and a subjective pain-score in 28 patients who received LASEK in one eye and PRK on the other eye. They could demonstrate a significantly faster healing time after PRK ( $3.07 \pm 0.64$  days vs.  $3.55 \pm 0.54$  days in the LASEK group), but also a significantly higher pain-score for the first 4 days after PRK (discomfort score of  $4.42 \pm 0.50$  in the PRK eyes, and  $2.85 \pm 0.44$  in the LASEK eyes with 5 being the maximum pain level in the test-chart) [30].

In summary, pain management represents an inevitable subject in SA no matter what strategy you prefer. Not only to provide relieve of discomfort but also to promote a proper wound healing.

For most surgeons, a multimodal strategy proved to be effective in postoperative pain management after SA. It includes a thorough explanation of the expected discomfort for 2–3 days after the treatment, perioperative usage of topical anesthetics and systemic non-steroidal anti-inflammatory drugs (NSAIDs), as well as postoperative topical NSAIDs, bandage contact lenses and lubricants [25]. Rinsing the exposed stroma with ice cold BSS and use of systemic and topical vitamin C to reduce pain are also reported.

The goal of postoperatively pain management is to provide an acceptable comfort level and simultaneously minimizing the risk for delayed corneal healing.

## Topical Anesthetics

The positive effect of topical anesthetic eye drops like Proparacaine, Oxybuprocaine, Lidocain and others on pain reduction in patients with a corneal epithelial defect is caused by blockage of sodium channels in neuronal axons and thereby stopping the conduction of painful stimuli [31, 32].

These drugs are used very effectively to prevent intra- and perioperative painful sensations. The postoperative usage has been controversially discussed in the literature because of the reported side effect of inhibiting the migration of epithelial cells [33, 34]. Nevertheless, some study groups could demonstrate a significant pain reduction without a delay in reepithelialisation after SA, if topical anesthetics were used every 30 min during waking hours within the first 24 h after the treatment (1% Tetracaine) [35], or even for 1 week in a diluted concentration (0.05% Proparacaine) applied every 15 min for 12 h on day 1 and every hour for 12 h on days 2 through 7 [36].

Despite these studies, my standard protocol does not include postoperative topical anesthetics and I recommend to be very cautious about handing local anesthetics to the patients because of the (high!) risk of drug abuse. Hereby induced corneal toxicity could lead to very severe and sight-threatening complications like haze formation, corneal infections, vascularization and calcification [37–39].

Current studies analyze the potential benefit of using topical opiates after SA [40, 41]. First results show, that these drugs might be able to effectively decrease pain-transduction by blocking local opioid receptors without affecting the epithelial migration and wound healing [41].

## Topical Non-steroidal Anti-inflammatory Drugs

NSAIDs inhibit the cyclooxygenase and thereby reduce inflammatory processes and pain. They are the standard drugs in postoperative pain-management because of their low side effects. Studies comparing different NSAIDS regarding their ability

to decrease the post-PRK-pain all agreed on their effective impact in post-surgical pain reduction [42–44]. Reported side effects include burning sensation after installation, superficial punctate keratitis, corneal infiltrates and delayed reepithelialization in some rare cases [44]. Frequently used agents are Diclofenac 0.1%, Bromfenac 0.09%, Ketorolac 0.4% and 0.5%, Nepafenac 0.1% and 0.03%, Flurbiprofen 0.03%, and Indomethacin 0.1% with a recommended frequency of three to four times daily for less than a week [44].

## Further Strategies for Pain Reduction After SA

Systemic NSAIDs, are widely used to support postoperative pain-management after SA. Other systemic pain-medication-agents like narcotics or anticonvulsants should be avoided due to potential systemic side-effects [9].

Bandage contact lenses, especially silicon hydrogel lenses, play a major role in postsurgical management after PRK. They significantly reduce the pain and support the reepithelialisation by reducing the mechanical impact of the eyelids on the exposed wound bed [45]. A study performed by the United States military forces analyzing the frequency of post-PRK bacterial infections in over 25,000 eyes provided with a bandage contact lens after treatment, could demonstrate an infection rate of less than 0.02% [46]. To not unnecessarily increase the risk of an infection, the contact lens should be removed 4–5 days after the treatment.

## Practical Recommendations

I use Oxybuprocainhydrochlorid 4 mg/ml (Conjuncain-EDO®; Bausch&Lomb) every 10 min starting 20 min before the surgery and during the treatment after positioning of the eyelid-speculum and before removing the speculum. After phtotoablation, I place a soft bandage contact lens (PureVision®; Bausch&Lomb) on the cornea, which I remove 5 days later. Above, the patient takes Ketorolac eyedrops (5 mg/ml Acular®, Allergan) for 5 days (every hour on the treatment day after the SA and four times daily on day 2–5) and lubricants (Hylo-Comod®, Ursapharm) every hour until the CL get removed. After epithelial closure and removal of the contact lens, the patient does not need any more pain medication and only uses locally administered lubricants and steroids, as described below. The most important and robust pain-management strategy is to inform the patient before and right after the treatment of the expected discomfort level (severe foreign body- and burning sensation, tearing and light sensitivity) for 2–3 days after the treatment and that the pain-level may shift for several hours. Encourage the patient by explaining, that it is a superficial wound, what causes the pain. It really burns, but it will heal fast without causing permanent damage and the pain will vanish almost instantly after the wound has finally closed.

## Early Postoperative Complications

### *Infectious Keratitis*

Infectious keratitis is one of the most severe and potentially vision threatening complications after SA. Comparing the incidence of infection after SA and LASIK, despite decreasing overall infection rates, SA display two to eight times higher infection rates mainly due to the prolonged epithelial defect and the use of postoperative bandage lenses [47, 48]. A study group from Spain analyzing >18,000 eyes after PRK demonstrated an infectious keratitis in 39 eyes of 38 patients (0.2%), who were treated with topical Tobramycin after SA. In 72%, the onset of infection was within 7 days after surgery and in case of a positive culture, the most frequently isolated microorganisms were Staphylococcus species. The final corrected distance visual acuity (CDVA) was 20/20 or better in 59%, 20/40 or better in 92%, and worse than 20/40 in 8% of the patients suffering from infection. After publishing their results in 2011, the study group published data of another analysis after changing their treatment regime by adding topical Moxifloxacin including >16,000 eyes. Thereby, they could decrease the infection rate down to 0.07% [49].

With 0.02%, the US Army and Navy refractive surgery centers reported an even lower incidence of infectious keratitis after SA, analyzing >25,000 eyes treated with PRK [46]. In all of their five cases with bacterial infection, the onset was between the second and seventh days after the treatment. One of them received a Trimethoprim sulfate/polymyxin b sulfate combination (Polytrim®, Allergan) as antibiotic prophylaxis, all others were treated with a second-generation fluoroquinolone (Ofloxacin®) after SA.

Next to Staphylococcus species, also Streptococcus species have been diagnosed as a frequent pathogen in bacterial keratitis after SA [50]. Because of the high incidence of gram-positive organisms, next to being broad spectrum, the prophylactic therapy should especially include gram-positive coverage. In case of an infectious keratitis after SA, mycobacterial or fungal keratitis are extremely rare and usually presents with a later onset and a different clinic [46, 51, 52].

In case of a suspected bacterial infection after SA, the antibiotics should be changed and used in an hourly frequency, especially, if the infiltrates presents during the first week after the treatment. In case that the patient still wears a bandage contact lens, the lens must be removed immediately and sent for culture specimen. An intensified antibiotic treatment regimen should be initiated without delay. One successful strategy is to use fortified Cefazolin and Gentamicin every hour. If suspected for MRSA infection, fortified Vancomycin instead of Cefazolin should be used [46]. As Wroblewski et al. recommended, not in every case of a corneal infiltrate, especially if small and located in the periphery, cultures have to be taken. Exceptions are, central or paracentral infiltrates larger than 2 mm, associated with significant pain or anterior chamber reaction and/or no adequate response to the antibiotic therapy [46].

## *Sterile Keratitis*

The most comprehensive study of sterile keratitis after SA has been published by Teal et al. in the early days of refractive surgery [53]. They reported, that sterile keratitis after PRK was first described after non-steroidal anti-inflammatory drugs (NASIDs) had been included into the SA-protocol. They surveyed 50 Canadian ophthalmologists who perform PRK about the incidence of sterile stromal opacification after PRK and received answers from 30 of them, reporting incidents between 1 to 40 and 1 to >600 eyes (average incidence rate: 1:300) [53]. Regarding their reports, sterile infiltrates tend to appear within the first 3 days after SA and most commonly present as a single central infiltrate with a ring shaped immune ring or as multiple peripheral located infiltrates.

In my experience, the high incidence of central corneal opacity is very unusual after PRK. Because the study analyzed results from the early days of PRK, this 'sterile keratitis' might be caused by a prolonged or increased exposition of the corneal stroma to chemical and mechanical irritation. Unfortunately, the methodology of the PRK has not been described in their study and might have differed both between the ophthalmologists surveyed in this study and to our present standards.

More recent case series analyzing sterile keratitis after laser vision correction, mostly report about sterile keratitis after lamellar procedures and will be discussed in the third chapter of this book [54–56]. To sum up their findings, they don't report about central, but almost always about peripheral infiltrates appearing within the first 3 days after the treatment and typically present outside the zone of laser treatment. The reason for sterile keratitis is not completely clear. The high incidence of peripheral sterile infiltrates is most probably related to the rich vascular and lymphatic supply to the limbus and increased by predisposing factors like staphylococcal blepharitis [55]. As Teal et al. already assumed in 1995, in SA, the probability of sterile keratitis is highly correlated with the use of NSAID [53]. As Al-Amry recently wrote in his case report about sterile keratitis after SA, 'NSAIDs inhibit the cyclooxygenase pathway for the metabolism of arachidonic acid. This inhibition causes increased production of leukotrienes and hydroxyeicosatetraenoic acid from the alternate pathway mediated by lipoxigenase. These chemoattractants result in a deposition of inflammatory cells causing infiltrates' [57].

Regarding the clinical symptoms of a sterile keratitis after SA, the patient presents with acute increase of pain, redness of the conjunctiva and tearing.

The 'classic' peripheral sterile infiltrates tend to dissolve after a few days and do usually not affect the final visual outcome. Single cases of severe sterile corneal melting after SA have been reported [58, 59]. These disastrous outcomes have been linked to preexisting risk factors like diabetes and prolonged [58] or increased [59] application of topical NASIDs.

## Haze

As described by Marshal et al., the term ‘haze’ is used to describe alterations in corneal transparency caused by refractive surgery [60]. It develops as a result of a pronounced wound healing response of the corneal tissue to the photoablation in SA basically in every patient. Due to the preservation of Bowman layer and epithelial-basement membrane within LASIK flap we do not expect haze even after LASIK with deep ablation. On the contrary, the ablation of the epithelial basement membrane and the Bowman layer during SA induces haze and the haze is more pronounced in the ablated stroma beneath. Ablating central stroma induces central haze, ablating peripheral stroma induces ring shaped haze and deeper ablations induce more haze than shallower ablations. The fact, that haze occurs much more frequently after SA than after lamellar laser-refractive treatments is attributed to the removal of the Bowman layer and epithelial basement membrane and to the epithelial and stromal trauma, which lead to an increased transduction of inflammatory cytokines and growth factors and thereby stimulate the haze formation (see above). Further, the SA-effect concentrates on the anterior segment of the corneal stroma, where the keratocyte-density, and therefore the possibility of activating/transforming into myofibroblasts, is highest. The most commonly accepted classification system for haze has been established by Fantes (see Table 11.2).


Next to bacterial infections and corneal sensitivity ectasia, haze represents the potentially most severe complication after PRK. Clinical symptoms of advanced haze (Fantes >2) are a reduced corrected visual acuity, night vision disturbance and reduced contrast sensitivity [61].

Starting with removal of the epithelium, tear film cytokine- and growth-factor-levels increase, initiating apoptosis of the underlying keratocytes and proliferation, transformation and migration of neighboring keratocytes [62]. These activated keratocytes are called myofibroblasts and produce several matrix metalloproteases, collagen and extracellular matrix to remodel the stroma, until the new generated epithelial basement membrane prevents further inflow of cytokines [62–64]. This relationship between the basement membrane and the myofibroblast-activity explains the increased risk of clinical relevant haze formation after SA compared to lamellar laser refractive procedures [65].

**Table 11.2** Fantes grading of corneal haze

Stage	Slit-lamp examination
0	Clear, no haze
0.5	Trace haze; seen with careful oblique examination
1	Haze not interfering with visibility of iris details
2	Mild obscuration of iris details
3	Moderate obscuration of iris and lens details
4	Complete opacification of the stroma obscuring anterior chamber

**Fig. 11.1** Subepithelial haze 4 weeks after SA (PRK)



Sub-epithelial trace haze can be seen in virtually all patients after SA and occurs usually 60–150  $\mu\text{m}$  beneath the corneal surface, starts 1–3 month after PRK (early haze), mostly peaking at the third month after SA, but might increase up to 6 month after the treatment, and then slowly diminishes throughout the following months [65]. In vivo confocal microscopy reveals hyper-reflective keratocytes (= myofibroblasts) in a clear cornea 4 weeks after SA resembling subclinical trace haze, i.e., Fantes <1 (see also Fig. 11.1).

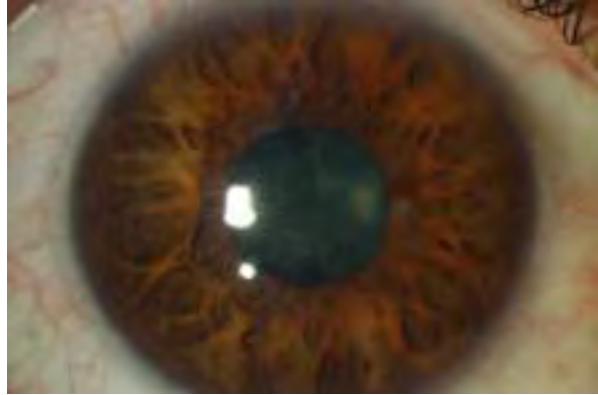Lin et al., analyzing the duration of haze after LASEK reported, that +1 haze resolved after  $4.0 \pm 2.2$  months, while +2 haze resolved after  $5.5 \pm 3.3$  months. In their study of 90 eyes treated with LASEK, haze formation peaked at 3 months after the treatment [66].

More complicated are rare cases of ‘late-onset haze’ occurring later than 3 month after PRK (see next segment of this chapter). Attributed to the above explained inflammatory process, haze always develops in the area, where the excimer-laser ablated the corneal tissue. Therefore, haze-formation after myopic, hyperopic and astigmatic PRK display significant morphological differences.

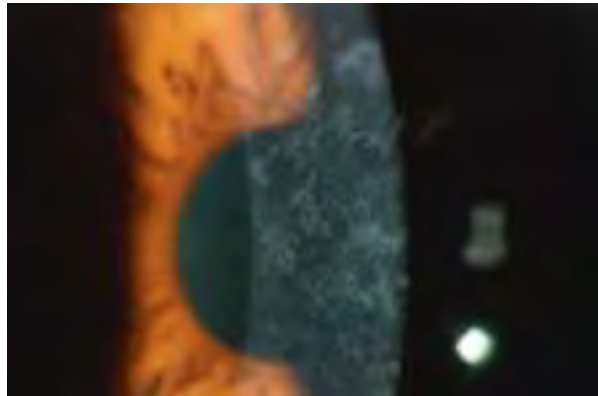
Figure 11.2 displays haze after myopic PRK with a mild opacification at the central area of the cornea (Fantes Stage 1). If not treated properly, haze can progress to more advanced stages as seen in Figs. 11.3, 11.4, and 11.5 (all Fantes Stage 3). Thereby, Fig. 11.4 demonstrates the typical subepithelial location of the haze formation.




**Fig. 11.2** Slit-lamp picture of haze after myopic PRK (Fantes I)




**Fig. 11.3** Slit-lamp picture of haze after myopic PRK (Fantes 3)




**Fig. 11.4** Slit-lamp documentation of sub-epithelial location of corneal haze after myopic PRK



**Fig. 11.5** Confocal microscopy picture of clinical Fantes +3 haze



**Fig. 11.6** Slit-lamp picture of haze and a prominent ferrum-line after hyperopic PRK (Fantes 2)



In contrast to haze-formation after myopic PRK, haze displays paracentrally and in an arcuate-shape after hyperopic SA (Fig. 11.6). Unrelated to haze it is worth mentioning that typical for a cornea after hyperopic laser correction is the arcuate-shaped, paracentral ferrum-line caused by a changed corneal lubrication and thereby increased deposits from tear film along the ablated area.

Different strategies have been established to decrease post-PRK corneal inflammation and thereby minimize the incidence of haze.

## ***Antiinflammatory Drugs (Topical Mitomycin-C, MMC)***

To reduce the myofibroblast activation, besides topical steroids, especially topical, intraoperatively applied MMC plays a major role in post SA haze-prevention [67–69]. As described by Tomás-Juan et al. in the comprehensive review, ‘MMC is an antineoplastic antibiotic agent of the family of anti-tumor quinolones and derived from *Streptomyces caespitosus*. It is a potent DNA crosslinker: it inhibits the replication of deoxyribonucleic acid (DNA). Thereby, MMC inhibits cell mitosis, including epithelial and stromal cells. MMC decreases corneal haze compared to corticosteroid treatment, and, consequently, improves visual acuity. Its use is specially indicated in high myopia ( $\geq -6.00$  D) and deeper ablation depths ( $\geq 75$   $\mu\text{m}$ )’ [70].

Above, Teus et al. recommended to use MMC not only in haze-prevention, but also to treat long lasting haze formation after photoablation [71]. In a study analyzing the effect and possible side-effects of MMC after PRK in hen, Blanco-Mezquita et al. could demonstrate less haze, keratocyte proliferation, myofibroblast differentiation, and new collagen deposition if MMC has been administered during PRK. Potentially synergistic cytotoxic effects of ethanol and MMC could not be observed [72].

However, to avoid adverse effects like conjunctival or scleral ulcerations, delayed epithelial closure or endothelial cell-damage, MMC should be used only intraoperatively (sponge), for a short period of time (from 15 s for small ablation up to 60 s in high ablation or secondary treatment) and in a concentration of 0.02% [67–69]. Some studies advocate for MMC 0.002% and a topical application of up to 2 min [71]. Thornton et al. could demonstrate an equal effect in haze prevention comparing 0.02 and 0.002% in low-to mild ablation. However, in eyes with an ablation of  $\geq 6$  diopters of myopia, the 0.02% concentration demonstrated to be more effective in haze-prevention [73]. A longer exposure time of the 0.002% MMC had no positive effect.

I use topical MMC in a concentration of 0.02% applied on the central cornea with a soaked round shaped sponge (8–10 mm sparing the limbus) between 15 and 45 s in every PRK procedure based on a personal nomogram: 15 s in myopic correction  $\leq -4$  diopters, 30 s if the myopic correction exceeds  $-4$  diopters and 45 s in a hyperopic correction or in case of a retreatment after previous corneal treatment. Reviewing our data retrieved from CareVision database, the total incidence for haze  $\geq$  Fantes +1 was 3.8% (100 of 2.657 eyes). Thereof, 90% displayed Fantes +1 and 10% Fantes +2.

## ***Epithelial Removal***

The main techniques in SA to remove the epithelium prior to the photoablation are mechanical scraping by using a rotary brush, using chemical agents (topical application of diluted 20% ethanol for 30 s), or using the laser itself (transepithelial PRK;

t-PRK). Intraoperative strategies to reduce the risk for postoperative haze formation aim to limit epithelial injury. Some authors suggest a potential haze-amplifying effect caused by the alcohol in rabbit eyes [74], whereas others could demonstrate faster epithelial regeneration and less haze after alcohol abrasio compared to solely mechanical removal in clinical studies in human eyes [75]. Lee et al. analyzed postoperative clinical outcome 6 months after either removing the epithelium mechanically, with an excimer-laser (transepithelial) or by using 20% diluted alcohol with flap-repositioning (i.e., Epi-on LASEK) [76]. Despite the theory of reducing the stromal inflammatory reaction after SA by preserving an epithelial flap along with the basement membrane structure over the ablated stromal bed, they reported similar postoperative pain and haze intensity between all groups. Contemporaneously, they demonstrated a slightly overcorrection in the t-PRK group and a slightly undercorrection in the LASEK-group. The mean spherical equivalent before SA ranged from  $-5.17$  D (PRK) to  $-5.26$  D without demonstrating statistically significant differences. Carones et al. show lower haze rates in eyes deepithelialized with alcohol 20% than in those deepithelialized solely mechanically [77]. All the above mentioned results were achieved by using optical zones  $\leq 6.0$  mm, no MMC and partially older excimer-laser systems operating with lower frequency and higher energy than the modern excimer generations.

A more recent study including  $>3,500$  subjects treated either with mechanical, alcohol-assisted, or t-PRK with the current standard (up-to date excimer-laser, intraoperative topical use of 0.02% MMC) could demonstrate for more than 1 year after SA, an UDVA (logMAR) of  $0.05 \pm 0.12$  (mechanical PRK),  $0.2 \pm 0.25$  (transepithelial PRK) and  $0.07 \pm 0.18$  (alcohol-PRK) accompanied by a safety index of  $0.96 \pm 0.15$ ;  $0.99 \pm 0.17$  and  $1.06 \pm 0.35$  [8]. Comparing t-PRK and LASEK (both SA were conducted with up to date excimer laser and optical zones  $\geq 6.5$  mm but without MMC), Korkmaz et al. reported, that LASEK appeared to induce less intense wound healing in the early postoperative period, but no difference in haze 3 month after the SA [78]. A study conducted by the US Army comparing mechanical PRK, mechanical PRK+MMC (topical intraoperatively application of 0.02% for 60 s) and LASEK (for all: optical zones of 6.5 mm, same up-to date excimer laser system) could demonstrate a general progressive clearing of corneal haze in all treatment groups [79]. They stated, that 'the number of eyes with corneal haze of any grade after MMC-PRK was comparable to that after PRK without MMC except at 3 and 6 months postoperatively when corneal haze was less common in MMC-PRK ( $P < .01$  and  $.03$ , respectively). There was no significant difference between LASEK without MMC and PRK. Compared to MMC-PRK, the rate of corneal haze (grade 0.5 or higher) was significantly higher after LASEK at 1, 3, and 6 months postoperatively ( $P < .01$ ).' In an analyzed subgroup of 77 patients either treated with PRK, MMC-PRK or LASEK for myopia of  $-6$ D or higher, they reported 'a statistically significant lower incidence of corneal haze of any grade in MMC-PRK versus PRK at 3 months postoperatively (12.8% MMC-PRK, 35.9% PRK;  $P = .03$ ) but not at other times [79]. Grade 0.5 haze or greater was significantly less common after MMC-PRK compared to LASEK at 1 month (21.4% MMC-PRK, 55.9% LASEK;  $P < .01$ ), 3 months (12.8% MMC-PRK, 42.4% LASEK;  $P < .01$ ), and 6 months

(12.2% MMC-PRK, 36.4% LASEK;  $P=.03$ ) postoperatively.’ [79] The authors concluded, that ‘MMC-PRK offered some advantages in minimizing postoperative haze formation and preserving corneal transparency in predisposed eyes. Despite few differences at specific time periods, the refractive outcomes were equally favorable among the three techniques 1 year after surgery’ [79].

A study group, analyzing haze after epi-LASIK, reported, that 97% of the eyes displayed haze 0.5 or less 3 month after the treatment [80].

## ***Ablation Depth***

As Tomás-Juan et al. summarized in their review, ‘haze formation is rarely seen in corneal ablation  $< -6$  D of myopia or  $< +4$  D of hyperopia, but common after correction of  $> -6$  D of myopia’ [70]. They also reported, that the duration of the epithelial defect, postoperative steroid treatment and male sex are correlated with post-PRK-haze-formation.

In another review, Qazi et al. demonstrated, that the treatment of moderate to high myopia leads to significant haze formation in 8–10% of LASEK eyes [81]. Others report a haze incidence of 7.5% with +3 haze, 17.8% with +2 haze, and 31.5% with +1 haze 12 months after LASEK for high myopia [82].

## **Late Postoperative (> 3 Month) Complications**

### ***Late Haze***

Despite the intraoperative topical use of MMC has become routine in modern SA, severe complications like late-onset after more than 6 months post SA still occur. In contrary to the early and transient haze, the late-onset variant has a high risk of persisting and thereby leading to severe reduction of visual acuity, increased halos and higher order aberrations. Some cases of severe late-onset haze have been reported with an onset even more than 1 year after SA [81]. Despite several studies analyzing risk factors, the cause and exact mechanisms of late-onset haze remain unclear [81]. Lifshitz et al. reported late haze appearing first  $>12$  months after PRK in 18 eyes of 17 patients from 1000 consecutive PRK patients (incidence 1.8%) treated in sunny Israel [83].

Kuo et al. reported an incidence of 1.8% for late-onset haze in eyes after PRK treated without MMC [84]. In their study, the mean age at the time of surgery was years (range 23–51 years). Three of the eight patients (37.5%) were female. The median attempted correction (SE) was  $-6.69$ D (range  $-4.0$  to  $-12.25$ ). Mean haze was +3 (range: +2 to +4) and peaked at  $7.4 \pm 2.8$  month (range: 4–12 month) accompanied by a mean SE regression of  $-2.01 \pm 0.79$ D (range  $-1.00$  to  $-3.00$ D), which was correlated with topographic steepening. The amount of late haze was positively correlated with the amount of attempted correction ( $r=0.66$ ,  $p=0.04$ ).

The amount of regression was not correlated with the amount of haze or the amount of the attempted correction [84].

Alio et al., analyzing over 3,000 eyes after PRK treated with optical zones  $\leq 6.0$  mm and no MMC, demonstrated a Fantes grade  $\geq +2$  haze occurring 1 year after SA in 1% of the patients treated for high myopia between  $-6$  and  $-10$  D [85]. This incidence increased up to 2%, when combining high myopia correction with an astigmatism correction  $\geq 1$ D. To analyze the potential haze-preserving effect of MMC, Carones et al. comparing PRK with and without haze in otherwise equally assembled groups, found 'haze higher than +1 at 6 month after the treatment in 0% of MMC eyes versus 63% of control eyes [86]. Further, the MMC-group presented, better UDVA and CDVA results, and more accurate refractive outcomes than those achieved in the control group without MMC. Evaluating the applied optical zone in SA procedures as another important risk factor for late-onset haze, Rajan et al. could demonstrate a negative correlation between late haze and the applied optical zone [87].

To sum up, reviewing the literature and respecting our own experience, late haze seems to be positively correlated with the amount of refractive correction and negatively with the applied optical zone. Further independent risk factors are previous corneal traumata/surgery, atopy, autoimmune disease and increased ultraviolet radiation [81]. The most effective prevention of (early and) late-onset haze could be demonstrated for the intraoperative topical application of 0.02% MMC.

In case of late-onset haze, despite no scientific evidence and many reported resistant cases, the most frequently applied therapy of late haze are topical steroids used for up to 1 year after SA [84]. In our experience with rare cases of severe late-onset haze – formation, topical steroids should be applied in a high frequency (up to four times daily), but only for a few weeks after the initial presentation. Thereby, it is important to slowly temper the frequency of the steroid (for example reduce one drop every 2 weeks) to avoid an increased inflammatory response.

If severe haze formation remains even 12 month after surgery, combining a phototherapeutic keratectomy (PTK) with intraoperative MMC proved to be very effective in visual rehabilitation in these seldom cases [71, 81].

Based on my own experience and the results of the studies analyzed and cited in this chapter, I recommend to consider SA only in patients with an expected ablation depth of  $<110$   $\mu\text{m}$ , apply an optical zone of at least 6.0 mm (I usually don't treat with OZ  $<6.5$  mm) and use intraoperative topical 0.02% MMC in every patient to minimize the risk of late-onset MMC.

## ***Regression***

In the early days of SA, the PRK presented with significant level of refractive regression months and years after the treatment [88, 89]. The main reasons for regression were small and spherical ablation zones and a prolonged inflammation after the treatment resulting in a remodeling/haze of the corneal tissue after the treatment.

Nowadays, smoothed, aspheric laser profiles, larger treatment zones and flying-spot laser technologies ensure not only improved postsurgical visual quality but also stable refractive results [87, 90, 91]. In SA, the additional improvement of anti-inflammatory strategies, especially the intraoperative topical application of MMC, lead to a refractive stability comparable to LASIK – treated eyes [92–95]. This also includes high myopic and hyperopic correction [95–99]. Above, some authors report less higher order aberrations after PRK compared to LASIK, due to the absence of flap-related irregularities [93, 98].

### *Persistent Dry Eye*

As outlined above, in SA, the nerve endings terminating in the anterior stroma and epithelium are severely damaged by epithelial removal and photoablation. Whereas a transient dry eye is expected after the treatment, it is still unclear how many patients might develop prolonged or even chronic dry eye disease (DED) after SA. As former studies could demonstrate, the neural damage after SA impairs the feedback to the lacrimal gland, and the conjunctival goblet cell mucin secretion causing a spectrum of ocular surface conditions associated with reduced tear production and secretion, tear-film instability, corneal and conjunctival epitheliopathy, and dry-eye symptoms [100–102].

Bower et al. could demonstrate a reduced corneal sensitivity, tearfilm production, and epithelial integrity during the first 3 month after mechanical PRK, without statistically significant changes of the tearfilm break up time (BUT). The corneal sensitivity and tearfilm parameters reached baseline-levels 6–12 month after PRK. Other studies on dry eye disease after PRK reported of a recurrence of dry eye disease related test-parameters 4 [103] to 12 [104] month after PRK.

Sia et al., comparing mechanical and alcohol-assisted PRK in more than 1,500 eyes, could demonstrate a statistically higher percentage of patients with dry eye symptoms and signs for the alcohol-PRK group (14.4% vs 8.9%) 1 month after SA, with equal results thereafter [105].

Reviewing published studies about dry eye after SA, most of them report different findings. This is mostly attributed to the inconsistencies in methodologies regarding the dry eye examination, as well as classification. Referring to the well written article by Bower et al., the incidence of chronic dry eye disease after PRK is 6% [101].

Regression analysis performed by this study group could demonstrate, that dry eye test-scores before SA (i.e., Schirmer Test, rose Bengal staining, BUT, corneal sensitivity, topographic corneal surface regularity index) and the usage/absence of intra-surgery applied topical MMC could explain only 11% of the post-SA-development of chronic dry eye in persons without suspect dry eye disease before SA [101]. These results suggest, that other, mostly unknown and not routinely tested factors predominantly influence the incidence of post-SA chronic dry eye disease. The strongest analyzed risk factor for chronic dry eye disease after PRK in otherwise regular eyes before SA, was a reduced pre-treatment Schirmer score [101].

Another prospective study suggested especially increasing age and female sex as risk factors for dry eye disease after corneal refractive surgery [106].

Studies comparing different SA-techniques regarding post-treatment dry eye do not exist. However, from my experience, there are no differences and should not be expected, because no matter how the epithelium is removed during SA, there will be a complete renewal of the epithelial layer and basement membrane afterwards. The main differences regarding the discomfort level after the different techniques have been discussed above (see section “Pain” in the “Early Postoperative Complications” section of this chapter).

The therapy for dry eye disease (DED) after SA starts with a thorough examination of the patient before the SA. In case of dry eye symptoms and/or signs like conjunctival folds, irregular corneal epithelium, a pathologic Schirmer Score ( $\leq 5$  mm) or break up time ( $< 5$  sec.), the patient should be delayed for surgery and start treating his dry eye until the condition stabilizes [107].

After the SA, even in the absence of dry eye before the treatment, the eyes have to be treated for several weeks with at least preservative free lubricants due to the known transient reduction of the tearfilm quantity and quality [101, 103]. If treated appropriately before and after the laser-procedure, even many mild-to-moderate dry eye patients can undergo successful corneal refractive surgery [108, 109].

Especially in case of preexisting dry eye, I strongly recommend informing the patient about the condition and focusing the patients sensibility on the status before the SA so he won't lose his patience in (the expected) situation of a prolonged and intensified treatment for dry eye after the SA. In eyes unsuspected for DED before SA, I administer preservative free artificial tears every hour during the first week after laser treatment, reduce the frequency to eight times daily for the next 3 weeks and then decrease to four times daily for 6–8 weeks. This usually helps the patients to recover from the surgical trauma without any further dry eye-related discomfort.

In case of mild to severe dry eye post SA, additional strategies proved to be helpful. Next to further increasing the frequency of the lubricants (up to every hour), ointments (at night or up to four times daily), temporary punctum plugs and ciclosporin A 0.05% eye drops (twice a day) should enable at least a stabilization and further rehabilitation of the condition. Usually, the intensified therapy has to be continued for several months, but in most cases not longer than for 1 year to achieve pre-operative level regarding the dry eye status [101, 107].

## References

### *Therapeutic Excimer Ablation*

1. Munnerlyn CR, Koons SJ, Marshall J. Photorefractive keratectomy: a technique for laser refractive surgery. *J Cataract Refract Surg.* 1988;14(1):46–52.
2. Seiler T, Bende T, Wollensak J. Use of far UV light in photoablation of the cornea. *Fortschr Ophthalmol.* 1986;83(5):556–8.



3. Kahle G, Stadter H, Seiler T, Wollensak J. Gas chromatographic and mass spectroscopic analysis of excimer and erbium: yttrium aluminum garnet laser-ablated human cornea. *Invest Ophthalmol Vis Sci.* 1992;33(7):2180–4.
4. Krueger RR, Rabinowitz YS, Binder PS. The 25th anniversary of excimer lasers in refractive surgery: historical review. *J Refract Surg.* 2010;26(10):749–60. doi:[10.3928/1081597X-20100921-01](https://doi.org/10.3928/1081597X-20100921-01).
5. Puliafito CA, Stern D, Krueger RR, Mandel ER. High-speed photography of excimer laser ablation of the cornea. *Arch Ophthalmol.* 1987;105(9):1255–9.
6. Bende T, Seiler T, Wollensak J. Side effects in excimer corneal surgery. Corneal thermal gradients. *Graefes Arch Clin Exp Ophthalmol.* 1988;226(3):277–80.
7. Seiler T, McDonnell PJ. Excimer laser photorefractive keratectomy. *Surv Ophthalmol.* 1995;40(2):89–118.
8. Abad JC, An B, Power WJ, Foster CS, Azar DT, Talamo JH. A prospective evaluation of alcohol-assisted versus mechanical epithelial removal before photorefractive keratectomy. *Ophthalmology.* 1997;104(10):1566–74. discussion 1574–5.
9. Espana EM, Grueterich M, Mateo A, Romano AC, Yee SB, Yee RW, et al. Cleavage of corneal basement membrane components by ethanol exposure in laser-assisted subepithelial keratectomy. *J Cataract Refract Surg.* 2003;29(6):1192–7.
10. Sekundo W, Tietjen A. Laser-assisted subepithelial keratectomy (LasEk). Review of the current state of knowledge. *Ophthalmologe.* 2003;100(8):603–10. doi:[10.1007/s00347-003-0853-8](https://doi.org/10.1007/s00347-003-0853-8).
11. Pallikaris IG, Katsanevaki VJ, Kalyvianaki MI, Naoumidi II. Advances in subepithelial excimer refractive surgery techniques: Epi-LASIK. *Curr Opin Ophthalmol.* 2003;14(4):207–12.
12. Liu XQ, Xu L, Yi CJ. Flap removal or flap preservation during LASEK surgery. *Cell Biochem Biophys.* 2010;57(1):45–8. doi:[10.1007/s12013-010-9082-3](https://doi.org/10.1007/s12013-010-9082-3).
13. Na KS, Lee KM, Park SH, Lee HS, Joo CK. Effect of flap removal in myopic epi-LASIK surgery on visual rehabilitation and postoperative pain: a prospective intraindividual study. *Ophthalmologica.* 2010;224(5):325–31. doi:[10.1159/000313834](https://doi.org/10.1159/000313834).
14. Lee YG, Chen WY, Petroll WM, Cavanagh HD, Jester JV. Corneal haze after photorefractive keratectomy using different epithelial removal techniques: mechanical debridement versus laser scrape. *Ophthalmology.* 2001;108(1):112–20.
15. Moller-Pedersen T, Cavanagh HD, Petroll WM, Jester JV. Corneal haze development after PRK is regulated by volume of stromal tissue removal. *Cornea.* 1998;17(6):627–39.
16. de Benito-Llopis L, Alio JL, Ortiz D, Teus MA, Artola A. Ten-year follow-up of excimer laser surface ablation for myopia in thin corneas. *Am J Ophthalmol.* 2009;147(5):768–73, 773. e761–2. doi:[10.1016/j.ajo.2008.12.022](https://doi.org/10.1016/j.ajo.2008.12.022).

### ***Complications and Management in Laser Refractive Surface Ablation (SA)***

17. Kim SY, Sah WJ, Lim YW, Hahn TW. Twenty percent alcohol toxicity on rabbit corneal epithelial cells: electron microscopic study. *Cornea.* 2002;21(4):388–92.
18. Zhang P, Liu M, Liao R. Toxic effect of using twenty percent alcohol on corneal epithelial tight junctions during LASEK. *Mol Med Rep.* 2012;6(1):33–8. doi:[10.3892/mmr.2012.880](https://doi.org/10.3892/mmr.2012.880).
19. Kaufman SC. Use of photorefractive keratectomy in a patient with a corneal scar secondary to herpes zoster ophthalmicus. *Ophthalmology.* 2008;115(2 Suppl):S33–4. doi:[10.1016/j.ophtha.2007.10.014](https://doi.org/10.1016/j.ophtha.2007.10.014).
20. Levy J, Lapid-Gortzak R, Klemperer I, Lifshitz T. Herpes simplex virus keratitis after laser in situ keratomileusis. *J Refract Surg.* 2005;21(4):400–2.
21. Wulff K, Fechner PU. Herpes simplex keratitis after photorefractive keratectomy. *J Refract Surg.* 1997;13(7):613.

22. Asbell PA. Valacyclovir for the prevention of recurrent herpes simplex virus eye disease after excimer laser photokeratectomy. *Trans Am Ophthalmol Soc.* 2000;98:285–303.
23. Dhaliwal DK, Romanowski EG, Yates KA, Hu D, Mah FS, Fish DN, et al. Valacyclovir inhibition of recovery of ocular herpes simplex virus type 1 after experimental reactivation by laser in situ keratomileusis. *J Cataract Refract Surg.* 2001;27(8):1288–93.
24. Shapira Y, Mimouni M, Levartovsky S, Varssano D, Sela T, Munzer G, et al. Comparison of three epithelial removal techniques in PRK: mechanical, alcohol-assisted, and transepithelial laser. *J Refract Surg.* 2015;31(11):760–6. doi:10.3928/1081597X-20151021-05.
25. Fay J, Juthani V. Current trends in pain management after photorefractive and phototherapeutic keratectomy. *Curr Opin Ophthalmol.* 2015;26(4):255–9. doi:10.1097/ICU.0000000000000170.
26. Kalyvianaki MI, Kymionis GD, Kounis GA, Panagopoulou SI, Grentzelos MA, Pallikaris IG. Comparison of Epi-LASIK and off-flap Epi-LASIK for the treatment of low and moderate myopia. *Ophthalmology.* 2008;115(12):2174–80. doi:10.1016/j.ophtha.2008.08.025.
27. Torres LF, Sancho C, Tan B, Padilla K, Schanzlin DJ, Chayet AS. Early postoperative pain following Epi-LASIK and photorefractive keratectomy: a prospective, comparative, bilateral study. *J Refract Surg.* 2007;23(2):126–32.
28. Cui M, Chen XM, Lu P. Comparison of laser epithelial keratomileusis and photorefractive keratectomy for the correction of myopia: a meta-analysis. *Chin Med J (Engl).* 2008;121(22):2331–5.
29. Zhao LQ, Wei RL, Cheng JW, Li Y, Cai JP, Ma XY. Meta-analysis: clinical outcomes of laser-assisted subepithelial keratectomy and photorefractive keratectomy in myopia. *Ophthalmology.* 2010;117(10):1912–22. doi:10.1016/j.ophtha.2010.02.004.
30. Eliacic M, Bayramlar H, Erdur SK, Karabela Y, Demirci G, Gulkilik IG, et al. Anterior segment optical coherence tomography evaluation of corneal epithelium healing time after 2 different surface ablation methods. *Saudi Med J.* 2015;36(1):67–72. doi:10.15537/smj.2015.1.9983.
31. McAlvin JB, Zhan C, Dohlman JC, Kolovou PE, Salvador-Culla B, Kohane DS. Corneal anesthesia with site 1 sodium channel blockers and dexmedetomidine. *Invest Ophthalmol Vis Sci.* 2015;56(6):3820–6. doi:10.1167/iovs.15-16591.
32. Wang L, Shankarappa SA, Tong R, Ciolino JB, Tsui JH, Chiang HH, et al. Topical drug formulations for prolonged corneal anesthesia. *Cornea.* 2013;32(7):1040–5. doi:10.1097/ICO.0b013e31828cbf6e.
33. Grant RL, Acosta D. Comparative toxicity of tetracaine, proparacaine and cocaine evaluated with primary cultures of rabbit corneal epithelial cells. *Exp Eye Res.* 1994;58(4):469–78. doi:10.1006/exer.1994.1040.
34. McGee HT, Fraunfelder FW. Toxicities of topical ophthalmic anesthetics. *Expert Opin Drug Saf.* 2007;6(6):637–40. doi:10.1517/14740338.6.6.637.
35. Verma S, Corbett MC, Marshall J. A prospective, randomized, double-masked trial to evaluate the role of topical anesthetics in controlling pain after photorefractive keratectomy. *Ophthalmology.* 1995;102(12):1918–24.
36. Shahinian Jr L, Jain S, Jager RD, Lin DT, Sanislo SS, Miller JF. Dilute topical proparacaine for pain relief after photorefractive keratectomy. *Ophthalmology.* 1997;104(8):1327–32.
37. Lee JK, Stark WJ. Anesthetic keratopathy after photorefractive keratectomy. *J Cataract Refract Surg.* 2008;34(10):1803–5. doi:10.1016/j.jcrs.2008.04.051.
38. Rao SK, Wong VW, Cheng AC, Lam PT, Lam DS. Topical anesthesia-induced keratopathy after laser-assisted subepithelial keratectomy. *J Cataract Refract Surg.* 2007;33(8):1482–4. doi:10.1016/j.jcrs.2007.04.020.
39. Yagci A, Bozkurt B, Egrilmez S, Palamar M, Ozturk BT, Pekel H. Topical anesthetic abuse keratopathy: a commonly overlooked health care problem. *Cornea.* 2011;30(5):571–5.
40. Faktorovich EG, Basbaum AI. Effect of topical 0.5% morphine on postoperative pain after photorefractive keratectomy. *J Refract Surg.* 2010;26(12):934–41. doi:10.3928/1081597X-20100212-06.

41. Zollner C, Mousa S, Klinger A, Forster M, Schafer M. Topical fentanyl in a randomized, double-blind study in patients with corneal damage. *Clin J Pain*. 2008;24(8):690–6. doi:[10.1097/AJP.0b013e318175929e](https://doi.org/10.1097/AJP.0b013e318175929e).
42. Donnenfeld ED, Holland EJ, Durrie DS, Raizman MB. Double-masked study of the effects of nepafenac 0.1% and ketorolac 0.4% on corneal epithelial wound healing and pain after photorefractive keratectomy. *Adv Ther*. 2007;24(4):852–62.
43. Durrie DS, Kennard MG, Boghossian AJ. Effects of nonsteroidal ophthalmic drops on epithelial healing and pain in patients undergoing bilateral photorefractive keratectomy (PRK). *Adv Ther*. 2007;24(6):1278–85.
44. Faktorovich EG, Melwani K. Efficacy and safety of pain relief medications after photorefractive keratectomy: review of prospective randomized trials. *J Cataract Refract Surg*. 2014;40(10):1716–30. doi:[10.1016/j.jcrs.2014.08.001](https://doi.org/10.1016/j.jcrs.2014.08.001).
45. Edwards JD, Bower KS, Sediq DA, Burka JM, Stutzman RD, Vanroekel CR, et al. Effects of lotrafilcon A and omafilcon A bandage contact lenses on visual outcomes after photorefractive keratectomy. *J Cataract Refract Surg*. 2008;34(8):1288–94. doi:[10.1016/j.jcrs.2008.04.024](https://doi.org/10.1016/j.jcrs.2008.04.024).
46. Wroblewski KJ, Pasternak JF, Bower KS, Schallhorn SC, Hubickey WJ, Harrison CE, et al. Infectious keratitis after photorefractive keratectomy in the United States army and navy. *Ophthalmology*. 2006;113(4):520–5. doi:[10.1016/j.ophtha.2005.09.038](https://doi.org/10.1016/j.ophtha.2005.09.038).
47. de Oliveira GC, Solari HP, Ciola FB, Lima AL, Campos MS. Corneal infiltrates after excimer laser photorefractive keratectomy and LASIK. *J Refract Surg*. 2006;22(2):159–65.
48. Haq Z, Farooq AV, Huang AJ. Infections after refractive surgery. *Curr Opin Ophthalmol*. 2016. doi:[10.1097/ICU.0000000000000275](https://doi.org/10.1097/ICU.0000000000000275).
49. Ortega-Usobiaga J, Llovet-Osuna F, Djodeyre MR, Llovet-Rausell A, Beltran J, Baviera J. Incidence of corneal infections after laser in situ keratomileusis and surface ablation when moxifloxacin and tobramycin are used as postoperative treatment. *J Cataract Refract Surg*. 2015;41(6):1210–6. doi:[10.1016/j.jcrs.2014.09.041](https://doi.org/10.1016/j.jcrs.2014.09.041).
50. Donnenfeld ED, O'Brien TP, Solomon R, Perry HD, Speaker MG, Wittmann J. Infectious keratitis after photorefractive keratectomy. *Ophthalmology*. 2003;110(4):743–7. doi:[10.1016/S0161-6420\(02\)01936-X](https://doi.org/10.1016/S0161-6420(02)01936-X).
51. Kothari SG, Kothari RS. Successful treatment of fusarium keratitis after photo refractive keratectomy. *Indian J Ophthalmol*. 2014;62(5):661. doi:[10.4103/0301-4738.133526](https://doi.org/10.4103/0301-4738.133526).
52. Rodriguez B, Holzinger KA, Le LH, Winkle RK, Allen RD. Mycobacterium chelonae keratitis after laser-assisted subepithelial keratectomy. *J Cataract Refract Surg*. 2006;32(6):1059–61. doi:[10.1016/j.jcrs.2006.03.011](https://doi.org/10.1016/j.jcrs.2006.03.011).
53. Teal P, Breslin C, Arshinoff S, Edmison D. Corneal subepithelial infiltrates following excimer laser photorefractive keratectomy. *J Cataract Refract Surg*. 1995;21(5):516–8.
54. Lahners WJ, Hardten DR, Lindstrom RL. Peripheral keratitis following laser in situ keratomileusis. *J Refract Surg*. 2003;19(6):671–5.
55. Lifshitz T, Levy J, Mahler O, Levinger S. Peripheral sterile corneal infiltrates after refractive surgery. *J Cataract Refract Surg*. 2005;31(7):1392–5. doi:[10.1016/j.jcrs.2004.12.057](https://doi.org/10.1016/j.jcrs.2004.12.057).
56. Yu EY, Rao SK, Cheng AC, Law RW, Leung AT, Lam DS. Bilateral peripheral corneal infiltrates after simultaneous myopic laser in situ keratomileusis. *J Cataract Refract Surg*. 2002;28(5):891–4.
57. Al-Amry MA. Severe bilateral paralimbal sterile infiltrates after photorefractive keratectomy. *Middle East Afr J Ophthalmol*. 2014;21(1):83–5. doi:[10.4103/0974-9233.124114](https://doi.org/10.4103/0974-9233.124114).
58. Gabison EE, Chastang P, Menashi S, Mourah S, Doan S, Oster M, et al. Late corneal perforation after photorefractive keratectomy associated with topical diclofenac: involvement of matrix metalloproteinases. *Ophthalmology*. 2003;110(8):1626–31. doi:[10.1016/S0161-6420\(03\)00486-X](https://doi.org/10.1016/S0161-6420(03)00486-X).
59. Mian SI, Gupta A, Pineda 2nd R. Corneal ulceration and perforation with ketorolac tromethamine (Acular) use after PRK. *Cornea*. 2006;25(2):232–4.
60. Marshall J, Trokel SL, Rothery S, Krueger RR. Long-term healing of the central cornea after photorefractive keratectomy using an excimer laser. *Ophthalmology*. 1988;95(10):1411–21.

61. Corbett MC, O'Brart DP, Patmore AL, Marshall J. Effect of collagenase inhibitors on corneal haze after PRK. *Exp Eye Res.* 2001;72(3):253–9. doi:[10.1006/exer.2000.0959](https://doi.org/10.1006/exer.2000.0959).
62. Wilson SE, Chaurasia SS, Medeiros FW. Apoptosis in the initiation, modulation and termination of the corneal wound healing response. *Exp Eye Res.* 2007;85(3):305–11. doi:[10.1016/j.exer.2007.06.009](https://doi.org/10.1016/j.exer.2007.06.009).
63. Chaurasia SS, Kaur H, de Medeiros FW, Smith SD, Wilson SE. Dynamics of the expression of intermediate filaments vimentin and desmin during myofibroblast differentiation after corneal injury. *Exp Eye Res.* 2009;89(2):133–9. doi:[10.1016/j.exer.2009.02.022](https://doi.org/10.1016/j.exer.2009.02.022).
64. Martinez-Garcia MC, Merayo-Llodes J, Blanco-Mezquita T, Mar-Sardana S. Wound healing following refractive surgery in hens. *Exp Eye Res.* 2006;83(4):728–35. doi:[10.1016/j.exer.2006.02.017](https://doi.org/10.1016/j.exer.2006.02.017).
65. Alio JL, Javaloy J. Corneal inflammation following corneal photoablative refractive surgery with excimer laser. *Surv Ophthalmol.* 2013;58(1):11–25. doi:[10.1016/j.survophthal.2012.04.005](https://doi.org/10.1016/j.survophthal.2012.04.005).
66. Lin N, Yee SB, Mitra S, Chuang AZ, Yee RW. Prediction of corneal haze using an ablation depth/corneal thickness ratio after laser epithelial keratomileusis. *J Refract Surg.* 2004;20(6):797–802.
67. Diakonis VF, Kankariya VP, Kymionis GD, Kounis G, Kontadakis G, Gkenos E, et al. Long term followup of photorefractive keratectomy with adjuvant use of mitomycin C. *J Ophthalmol.* 2014;2014:821920. doi:[10.1155/2014/821920](https://doi.org/10.1155/2014/821920).
68. Ghoreishi M, Attarzadeh H, Zandi A, Moini HA, Tavakoli M, Fesharaki H, et al. Outcomes of photorefractive keratectomy with intraoperative mitomycin-C. *J Ophthalmic Vis Res.* 2009;4(3):142–6.
69. Nassaralla BA, McLeod SD, Nassaralla Jr JJ. Prophylactic mitomycin C to inhibit corneal haze after photorefractive keratectomy for residual myopia following radial keratotom. *J Refract Surg.* 2007;23(3):226–32.
70. Tomás-Juan J, Murueta-Goyena Larranaga A, Hanneken L. Corneal regeneration after photorefractive keratectomy: a review. *J Optom.* 2015;8(3):149–69. doi:[10.1016/j.optom.2014.09.001](https://doi.org/10.1016/j.optom.2014.09.001).
71. Teus MA, de Benito-Llopis L, Alio JL. Mitomycin C in corneal refractive surgery. *Surv Ophthalmol.* 2009;54(4):487–502. doi:[10.1016/j.survophthal.2009.04.002](https://doi.org/10.1016/j.survophthal.2009.04.002).
72. Blanco-Mezquita T, Espandar L, Torres R, Alvarez-Barcia A, Cantalapiedra-Rodriguez R, Martinez-Garcia C, et al. Does mitomycin C cause toxicity in the cornea after photorefractive keratectomy? A comparative wound-healing study in a refractive surgery animal model. *Cornea.* 2014;33(11):1225–31. doi:[10.1097/ICO.0000000000000219](https://doi.org/10.1097/ICO.0000000000000219).
73. Thornton I, Xu M, Krueger RR. Comparison of standard (0.02%) and low dose (0.002%) mitomycin C in the prevention of corneal haze following surface ablation for myopia. *J Refract Surg.* 2008;24(1):S68–76.
74. de Medeiros FW, Mohan RR, Suto C, Sinha S, Bonilha VL, Chaurasia SS, et al. Haze development after photorefractive keratectomy: mechanical vs ethanol epithelial removal in rabbits. *J Refract Surg.* 2008;24(9):923–7.
75. Einollahi B, Baradaran-Rafii A, Rezaei-Kanavi M, Eslani M, Parchegani MR, Zare M, et al. Mechanical versus alcohol-assisted epithelial debridement during photorefractive keratectomy: a confocal microscopic clinical trial. *J Refract Surg.* 2011;27(12):887–93. doi:[10.3928/1081597X-20110823-02](https://doi.org/10.3928/1081597X-20110823-02).
76. Lee HK, Lee KS, Kim JK, Kim HC, Seo KR, Kim EK. Epithelial healing and clinical outcomes in excimer laser photorefractive surgery following three epithelial removal techniques: mechanical, alcohol, and excimer laser. *Am J Ophthalmol.* 2005;139(1):56–63. doi:[10.1016/j.ajo.2004.08.049](https://doi.org/10.1016/j.ajo.2004.08.049).
77. Carones F, Fiore T, Brancato R. Mechanical vs. alcohol epithelial removal during photorefractive keratectomy. *J Refract Surg.* 1999;15(5):556–62.
78. Korkmaz S, Bilgihan K, Sul S, Hondur A. A clinical and confocal microscopic comparison of transepithelial PRK and LASEK for myopia. *J Ophthalmol.* 2014;2014:784185. doi:[10.1155/2014/784185](https://doi.org/10.1155/2014/784185).

79. Sia RK, Ryan DS, Edwards JD, Stutzman RD, Bower KS. The U.S. Army Surface Ablation Study: comparison of PRK, MMC-PRK, and LASEK in moderate to high myopia. *J Refract Surg.* 2014;30(4):256–64. doi:[10.3928/1081597X-20140320-04](https://doi.org/10.3928/1081597X-20140320-04).
80. Pallikaris IG, Kalyvianaki MI, Katsanevaki VJ, Ginis HS. Epi-LASIK: preliminary clinical results of an alternative surface ablation procedure. *J Cataract Refract Surg.* 2005;31(5):879–85. doi:[10.1016/j.jcrs.2004.09.052](https://doi.org/10.1016/j.jcrs.2004.09.052).
81. Qazi MA, Johnson TW, Pepose JS. Development of late-onset subepithelial corneal haze after laser-assisted subepithelial keratectomy with prophylactic intraoperative mitomycin-C Case report and literature review. *J Cataract Refract Surg.* 2006;32(9):1573–8. doi:[10.1016/j.jcrs.2006.04.027](https://doi.org/10.1016/j.jcrs.2006.04.027).
82. Kim JK, Kim SS, Lee HK, Lee IS, Seong GJ, Kim EK, et al. Laser in situ keratomileusis versus laser-assisted subepithelial keratectomy for the correction of high myopia. *J Cataract Refract Surg.* 2004;30(7):1405–11. doi:[10.1016/j.jcrs.2003.12.053](https://doi.org/10.1016/j.jcrs.2003.12.053).
83. Lipshitz I, Loewenstein A, Varssano D, Lazar M. Late onset corneal haze after photorefractive keratectomy for moderate and high myopia. *Ophthalmology.* 1997;104(3):369–73. discussion 373–4.
84. Kuo IC, Lee SM, Hwang DG. Late-onset corneal haze and myopic regression after photorefractive keratectomy (PRK). *Cornea.* 2004;23(4):350–5.
85. Alio JL, Artola A, Claramonte PJ, Ayala MJ, Sanchez SP. Complications of photorefractive keratectomy for myopia: two year follow-up of 3000 cases. *J Cataract Refract Surg.* 1998;24(5):619–26.
86. Carones F, Vigo L, Scandola E, Vacchini L. Evaluation of the prophylactic use of mitomycin-C to inhibit haze formation after photorefractive keratectomy. *J Cataract Refract Surg.* 2002;28(12):2088–95.
87. Rajan MS, O’Brart D, Jaycock P, Marshall J. Effects of ablation diameter on long-term refractive stability and corneal transparency after photorefractive keratectomy. *Ophthalmology.* 2006;113(10):1798–806. doi:[10.1016/j.ophtha.2006.06.030](https://doi.org/10.1016/j.ophtha.2006.06.030).
88. Kim JH, Sah WJ, Kim MS, Lee YC, Park CK. Three-year results of photorefractive keratectomy for myopia. *J Refract Surg.* 1995;11(3 Suppl):S248–52.
89. Tengroth B, Epstein D, Fagerholm P, Hamberg-Nystrom H, Fitzsimmons TD. Excimer laser photorefractive keratectomy for myopia. Clinical results in sighted eyes. *Ophthalmology.* 1993;100(5):739–45.
90. O’Brart DP. Excimer laser surface ablation: a review of recent literature. *Clin Exp Optom.* 2014;97(1):12–7. doi:[10.1111/cxo.12061](https://doi.org/10.1111/cxo.12061).
91. Reynolds A, Moore JE, Naroo SA, Moore CB, Shah S. Excimer laser surface ablation—a review. *Clin Experiment Ophthalmol.* 2010;38(2):168–82. doi:[10.1111/j.1442-9071.2010.02230.x](https://doi.org/10.1111/j.1442-9071.2010.02230.x).
92. Manche EE, Haw WW. Wavefront-guided laser in situ keratomileusis (Lasik) versus wavefrontguided photorefractive keratectomy (Prk): a prospective randomized eye-to-eye comparison (an American Ophthalmological Society thesis). *Trans Am Ophthalmol Soc.* 2011;109:201–20.
93. McAlinden C, Skiadaresi E, Moore JE. Hyperopic LASEK treatments with mitomycin C using the SCHWIND AMARIS. *J Refract Surg.* 2011;27(5):380–3. doi:[10.3928/1081597X-20101104-01](https://doi.org/10.3928/1081597X-20101104-01).
94. Moshirfar M, Schliesser JA, Chang JC, Oberg TJ, Mifflin MD, Townley R, et al. Visual outcomes after wavefront-guided photorefractive keratectomy and wavefrontguided laser in situ keratomileusis: prospective comparison. *J Cataract Refract Surg.* 2010;36(8):1336–43. doi:[10.1016/j.jcrs.2010.02.012](https://doi.org/10.1016/j.jcrs.2010.02.012).
95. Settas G, Settas C, Minos E, Yeung IY. Photorefractive keratectomy (PRK) versus laser assisted in situ keratomileusis (LASIK) for hyperopia correction. *Cochrane Database Syst Rev.* 2012;6, CD007112. doi:[10.1002/14651858.CD007112.pub3](https://doi.org/10.1002/14651858.CD007112.pub3).
96. Dirani M, Couper T, Yau J, Ang EK, Islam FM, Snibson GR, et al. Long-term refractive outcomes and stability after excimer laser surgery for myopia. *J Cataract Refract Surg.* 2010;36(10):1709–17. doi:[10.1016/j.jcrs.2010.04.041](https://doi.org/10.1016/j.jcrs.2010.04.041).

97. Katz T, Wagenfeld L, Galambos P, Darrelmann BG, Richard G, Linke SJ. LASIK versus photorefractive keratectomy for high myopic (> 3 diopter) astigmatism. *J Refract Surg.* 2013;29(12):824–31. doi:[10.3928/1081597X-20131029-03](https://doi.org/10.3928/1081597X-20131029-03).
98. Kirwan C, O'Keefe M. Comparative study of higher-order aberrations after conventional laser in situ keratomileusis and laser epithelial keratomileusis for myopia using the technolas 217z laser platform. *Am J Ophthalmol.* 2009;147(1):77–83. doi:[10.1016/j.ajo.2008.07.014](https://doi.org/10.1016/j.ajo.2008.07.014).
99. O'Brart DP, Mellington F, Jones S, Marshall J. Laser epithelial keratomileusis for the correction of hyperopia using a 7.0-mm optical zone with the Schwind ESIRIS laser. *J Refract Surg.* 2007;23(4):343–54.
100. Ang RT, Dartt DA, Tsubota K. Dry eye after refractive surgery. *Curr Opin Ophthalmol.* 2001;12(4):318–22.
101. Bower KS, Sia RK, Ryan DS, Mines MJ, Dartt DA. Chronic dry eye in photorefractive keratectomy and laser in situ keratomileusis: manifestations, incidence, and predictive factors. *J Cataract Refract Surg.* 2015;41(12):2624–34. doi:[10.1016/j.jcrs.2015.06.037](https://doi.org/10.1016/j.jcrs.2015.06.037).
102. Quinto GG, Camacho W, Behrens A. Postrefractive surgery dry eye. *Curr Opin Ophthalmol.* 2008;19(4):335–41. doi:[10.1097/ICU.0b013e3283009ef8](https://doi.org/10.1097/ICU.0b013e3283009ef8).
103. Beheshtnejad AH, Hashemian H, Kermanshahani AM, Mahmoudi A, Johari MK. Evaluation of tear osmolarity changes after photorefractive keratectomy. *Cornea.* 2015;34(12):1541–4. doi:[10.1097/ICO.0000000000000649](https://doi.org/10.1097/ICO.0000000000000649).
104. Murakami Y, Manche EE. Prospective, randomized comparison of self-reported postoperative dry eye and visual fluctuation in LASIK and photorefractive keratectomy. *Ophthalmology.* 2012;119(11):2220–4. doi:[10.1016/j.ophtha.2012.06.013](https://doi.org/10.1016/j.ophtha.2012.06.013).
105. Sia RK, Ryan DS, Stutzman RD, Psolka M, Mines MJ, Wagner ME, et al. Alcohol versus brush PRK: visual outcomes and adverse effects. *Lasers Surg Med.* 2012;44(6):475–81. doi:[10.1002/lsm.22036](https://doi.org/10.1002/lsm.22036).
106. Farahi A, Hashemi H, Mehravaran S, Tavakolizadeh S, Khabazkhoob M. Tear function evaluation in candidates of corneal laser refractive surgery for myopia. *Eye Contact Lens.* 2014;40(2):91–4. doi:[10.1097/ICL.0000000000000015](https://doi.org/10.1097/ICL.0000000000000015).
107. Torricelli AA, Bechara SJ, Wilson SE. Screening of refractive surgery candidates for LASIK and PRK. *Cornea.* 2014;33(10):1051–5. doi:[10.1097/ICO.0000000000000171](https://doi.org/10.1097/ICO.0000000000000171).
108. Salib GM, McDonald MB, Smolek M. Safety and efficacy of cyclosporine 0.05% drops versus unpreserved artificial tears in dry-eye patients having laser in situ keratomileusis. *J Cataract Refract Surg.* 2006;32(5):772–8. doi:[10.1016/j.jcrs.2005.10.034](https://doi.org/10.1016/j.jcrs.2005.10.034).
109. Toda I, Yagi Y, Hata S, Itoh S, Tsubota K. Excimer laser photorefractive keratectomy for patients with contact lens intolerance caused by dry eye. *Br J Ophthalmol.* 1996;80(7):604–9.

**Part IV**  
**Post Corneal Refractive Surgery**  
**Ectasia (PRSE)**

# Chapter 12

## Post Refractive Surgery Ectasia

Renato Ambrósio Jr, Isaac Ramos, and Fernando Faria Correia

### Introduction

Progressive “iatrogenic” keratectasia after LASIK was first described by Prof. Theo Seiler, MD and represents a relatively rare but very severe complication of laser vision correction (LVC) procedures [1–3]. Despite several studies on the etiology and the pathophysiology of this condition, these aspects are not fully determined [2, 4–6]. The incidence rate falls between relatively high levels of 0.66% [7] and 0.57% [8],

---

R. Ambrósio Jr, MD, PhD (✉)  
Instituto de Olhos Renato Ambrósio, Rio de Janeiro, Brazil

VisareRIO, Rio de Janeiro, Brazil

Rio de Janeiro Corneal Tomography and Biomechanics Study Group, Rio de Janeiro, Brazil

Brazilian Study Group of Artificial Intelligence and Corneal Analysis – BRAIN,  
Maceio, AL, Brazil

Department of Ophthalmology, Federal University of São Paulo, Sao Paulo, Brazil  
e-mail: [dr.renatoambrosio@gmail.com](mailto:dr.renatoambrosio@gmail.com)

I. Ramos, MD

Rio de Janeiro Corneal Tomography and Biomechanics Study Group, Rio de Janeiro, Brazil

Brazilian Study Group of Artificial Intelligence and Corneal Analysis – BRAIN,  
Maceio, AL, Brazil

Hospital de Olhos Santa Luzia, Maceió, AL, Brazil

F.F. Correia, MD

Rio de Janeiro Corneal Tomography and Biomechanics Study Group, Rio de Janeiro, Brazil

Life and Health Sciences Research Institute (ICVS), School of Health Sciences,  
University of Minho, Braga, Portugal

ICVS/3B's-PT Government Associate Laboratory, Braga/Guimaraes, Portugal

Ophthalmology Department, Hospital de Braga, Braga, Portugal



**Table 12.1** Risk factors for ectasia progression after laser vision correction

Preoperative ectatic disease (which may also occur despite of normal topography)
Young age
High corrections
Multiple enhancements
Low residual stromal bed
High percentage of tissue altered
Thin cornea
Thick flap
Small optical zone
Chronic eye rubbing or trauma after surgery

down to 0.2% [9], 0.05% [10], 0.04% [11] or 0.029% (Schallhorn, 2013, unpublished data). Ectasia is related to a very high potential for vision impairment and morbidity, causing frustration and dissatisfaction for either patients and refractive surgeons. It should also be emphasized that there is a relatively high risk of malpractice liability claims and lawsuits related to progressive ectasia after LVC [12].

Ectasia occurs due to the biomechanical failure of the corneal stroma, leading to thinning and protrusion [12–16]. In essence, this process occurs because of the inability of corneal tissue to support the continuous stresses caused by intraocular (IOP) pressure, extra-ocular muscles actions, blinking, eye rubbing and other forces [5, 15–17]. The current understanding is that long-term stability after corneal surgery is determined by the combination of the preoperative biomechanical resiliency related to the elastic strength of the patient’s corneal stroma and to the amount of biomechanical change induced by the surgery in addition to the postoperative stress load to the cornea. Table 12.1 summarizes the recognized risk factors for ectasia after LVC. Nevertheless, the pathophysiology associated with ectasia development are related to these three possible considerations:

1. preoperative structural abnormalities, such as keratoconus or other corneal ectatic diseases (clinical or subclinical), or high corneal susceptibility due to weak biomechanical properties [4, 17, 18];
2. severe biomechanical impact from surgery [18–20];
3. severe trauma after surgery, such as vigorous eye rubbing due to allergic conjunctivitis, to cause (possibly unilaterally) post-LASIK keratectasia without other known predisposing risk factors [21].


## Preoperative Screening

Considering the severity of ectasia after LVC, the best treatment strategy is preventing it. The concept of screening for ectasia risk is intimately related to such preventive approach. Screening represents the application of a diagnostic test to detect cases with mild to moderate disease or with high susceptibility or predisposition for


developing the disease. It is usually applied to prevent suffering and morbidity, when treatment decisions can alter the natural course of the disease [12].

Understanding of corneal geometry analysis by using the current diagnostic technology and the knowledge about the impact of kerato-refractive procedures on the corneal structure are the basis of screening for ectasia risk preoperatively. However, identifying cases at high risk or susceptibility for biomechanical failure after LVC represents a major challenge for refractive surgeons [12, 13]. Classic methodology for screening refractive patients includes Placido-disk based corneal topography and central corneal thickness (CCT) [22]. Randleman and coworkers designed the “Ectasia Risk Scoring System” (ERSS), based on a retrospective case-control study, which included Placido disc-based corneal topography, CCT, level of correction, residual stromal bed (RSB) and patient’s age [11, 18]. Abnormal topography was the most important risk factor for ectasia development [11, 18]. The ERSS was validated by a second study which found a relatively lack of proper sensitivity with 8 % of false negatives [23]. Another retrospective study, including 36 cases with post-LASIK ectasia, described 9 (25 %) eyes classified as low risk and 7 (19 %) eyes as moderate risk on the ERSS [24]. The relatively high incidence of false negatives on the ERSS goes in agreement with other reported cases of ectasia after LASIK in the absence of apparent risk factors [25, 26]. In addition, a relatively high incidence of false positives may be registered, especially if a younger population of LASIK candidates with normal topographies is evaluated [4, 27]. Another limitation is related to the subjectivity criteria for corneal topography classifications. In fact, Ramos and coworkers reported significant inter-observer variability in subjective classifications of corneal topography maps [28]. In the same study, changing from an absolute to a normative scale increased the scores on the classifications by the same examiner, with significant intra-observer variability [28]. There are objective quantitative indices, such as the classic Rabinowitz inferior-superior dioptric asymmetry value (I-S) and the keratoconus percentage index (KISA), and qualitative pattern of asymmetric bowtie with skewed radial axes (AB/SRAX) should be taken into account for proper interpretation of corneal curvature maps [12, 29, 30].

Previous reports showed that corneal topography was very sensitive for detecting subclinical ectatic changes on the anterior corneal surface, even before loss of best spectacle-corrected visual acuity and development of typical slit lamp biomicroscopy finding [31, 32]. However, the awareness that a normal topography does not exclude mild or early ectatic corneal disease should be present among refractive surgeons [12, 13, 33, 34]. In this context, there is an essential need to recognize subclinical cases with normal topography, such as those from patients with keratoconus in the fellow eye (Figs. 12.1 and 12.2). While these cases have been considered to demonstrate enhanced accuracy of corneal tomography using different commercial approaches [12, 13, 34–36], they do not represent the ideal study population for assessing high susceptibility or predisposition for ectasia progression. One important fact is the presence of truly unilateral ectatic disease in some patients, due to unilateral stimuli, such as chronic eye rubbing [21]. While only longitudinal follow-up studies are able to clarify this definition, these cases have been referred to as forme fruste keratoconus (FFKC) in the non-affected eye with normal topography [13, 34, 36]. The FFKC



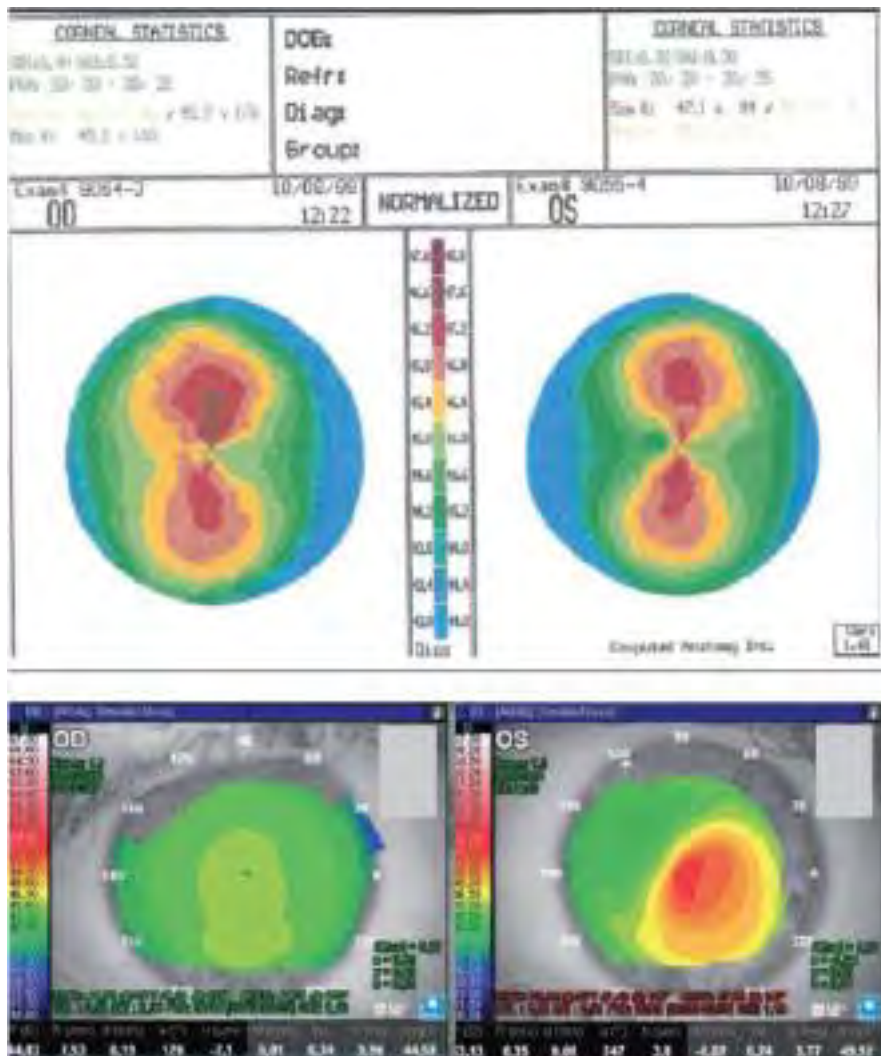
**Fig. 12.1** Anterior curvature sagittal map of both eyes from a patient with mild keratoconus OD and forme fruste keratoconus OS



**Fig. 12.2** Figure 1. Belin/Ambrósio Enhanced Ectasia Display from OD (A) and OS (B) from the same patient as in Figure 12.1

concept was originally introduced and described by Prof. Marc Amsler in the early 1960s, based on reflection Placido-disk photography, a few decades prior to the development of computerized corneal imaging technologies. FFKC was used to describe an abortive form of the disease that may or not progress [37, 38].

The need for enhancing the sensitivity for detecting mild or subclinical ectatic disease is also supported by the reported cases of ectasia after LASIK (Figs. 12.2 and 12.3) [25, 39–42]. The retrospective study of such cases represent the ideal group for testing and further enhancing the sensitivity for detecting ectasia risk. However, this is important to consider the impact from the procedure, for example, a thick flap or excessive tissue. In fact, the analysis of the preoperative data from these cases has provided the most important advances in the field [12, 23]. Many of the reported cases, however, had limited preoperative data to front surface curvature and CCT,



**Fig. 12.3** Progressive unilateral ectasia after LASIK. The patient only performed unilateral LASIK in the left eye to correct -6.00 -1.00 x 180°. (Above) Preoperative axial curvature maps using a normalized adjustable scale of both eyes. (Below) Postoperative axial curvature maps using the absolute Smolek-Klyce scale.

which restricts their study potential [12]. Another major concept is that any cornea can undergo ectasia progression, if there is enough disturbances from surgery and/or by other environmental factors, such as ocular trauma and eye rubbing [12, 21].

Therefore, the aim is not exclusively to detect mild or subclinical keratoconus, but to lengthily assess individual’s susceptibility for ectasia progression, which also depends on the biomechanical impact from the LVC procedure [12, 34]. Regarding this goal, the screening methodology should go beyond front surface topography and CCT evaluation.




Fig. 12.4 ESS-1 Pre-operative Display

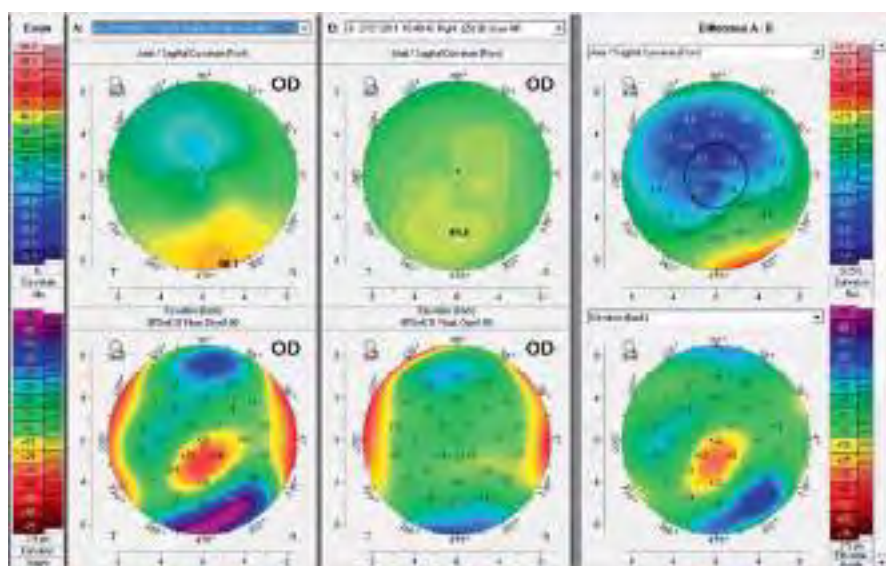


Fig. 12.5 Post-op (left column), Pre-op (middle column) and differential (right column) of a post-LASIK ectasia after uneventful surgical procedure. Note the changes in posterior corneal elevation on the differential map (superior to 7µm in the central 4mm zone).

## Interpretation of Corneal Tomography

Corneal tomography has proven to be more effective than topography for enhancing the accuracy for screening ectatic disease [12, 13, 25, 33, 34, 43]. Tomography enables a three dimensional (3D) reconstruction of the corneal shape, providing elevation maps of the front and back surfaces of the cornea, along with pachymetric mapping [44]. Corneal elevation maps represent the difference from the examined corneal surface (anterior or posterior) compared to a chosen reference body.

Typically, the reference is calculated to have more coincident points (best-fit) with the examined surface. The best-fit sphere (BFS) to the 8 mm zone has been recommended, as it provides adequate data points without the need of use extrapolated data for the majority of cases [13]. The map pattern, the elevation values at the thinnest point and at maximum elevation within central 4–5 mm zone are the most important features for clinical interpretation. Different geometric references may be used in these maps, such as best-fit toric and aspheric ellipsoid (BFTA or BFTE). The clinician should understand the impact of selecting different geometric bodies, along with the zone diameter to calculate the best-fit. For example, the BFS allows for the identification of regular astigmatism, while the best-fit toric ellipsoid (BFTE) facilitates the evaluation of irregular astigmatism. Regarding keratoconus detection, we reported similar performances for the elevation values at the thinnest point of the posterior surface by using BFS and BFTE (8 mm zone). Using the Pentacam (Oculus, Wetzlar, Germany), the cut-off criteria for the posterior elevation value at the thinnest point using the BFS was 12  $\mu\text{m}$  and using the BFTE was 8  $\mu\text{m}$ , with respectively sensitivity of 96.28% and 95.04% and specificity of 98.79% and 99.09% for detecting keratoconus [33, 35]. The concept of an “enhanced elevation” has also been introduced by Michael Belin, MD and implemented on the Pentacam. After calculating the standard BFS for the 8-mm corneal zone, a second “enhanced” best-fit sphere for the same zone excluding the 3.5-mm-diameter zone centered at the thinnest point is calculated. The difference map from the standard and enhanced BFS will emphasize any differences within the excluded zone. More than 5  $\mu\text{m}$  of difference for the front elevation and 12  $\mu\text{m}$  difference for the back elevation are considered suspicious [13, 33, 35].

Corneal tomography also enables detailed thickness mapping, providing the characterization of the thinnest point value and its location, along with thickness distribution all through the entire cornea [44]. Previous studies showed that the thinnest point (TP) is a more accurate parameter than central thickness for screening ectatic corneal diseases, as well as for calculating the “Percentage Tissue Altered” (PTA) and RSB. In the Pentacam, the thickness distribution is described by using the corneal thickness spatial profile (CTSP) and percentage thickness increase (PTI) concepts [45]. Starting from the TP outwards, the CTSP describes the rate of increase of corneal thickness using the average of pachymetric values within annular rings concentric to the TP separated by 0.1 mm steps. The PTI involves a similar measuring process centered on the TP, but it takes the percentage of thickness increase from the TP for the average along each ring. The Pentacam software reports CTSP and PTI of the examined cornea in graphs, along with the data of the mean and two standard deviations (95% confidence intervals) of a normal population [13, 33, 35]. From this data, pachymetric progression indexes (PPI) are calculated for all hemi-meridian over the entire cornea, starting from the TP. The average of all meridians is noted as the pachymetric progression average (PPI Ave) and the meridians with maximal (PPI Max) and minimal (PPI Min) pachymetric increase are noted along with their axes. In a normal population, the averages and SD of PPI of the minimal, maximal meridians and average of all meridians are  $0.58 \pm 0.3$ ,  $0.85 \pm 0.18$  and  $0.13 \pm 0.33$ , respectively [13, 45]. The pachymetric index will be higher if the cornea gets thicker in a more abrupt pattern from the thinnest point out to the periphery (PTI and CTSP graphs falling down) [45].

The Ambrósio's Relational Thickness (ART) values are calculated as the ratios of the TP and the average of the PPI at all meridians (ART-Ave) and the meridian with maximal PPI (ART-Max) [46]. The cut-off criteria for ART-Ave for clinical and mild (FFKC) keratoconus were 474  $\mu\text{m}$  and 521  $\mu\text{m}$ , respectively, with sensitivity and specificity of 99.59 % and 98.19 % for keratoconus and 91.49 % and 93.05 % for FFKC. For ART-Max, 386  $\mu\text{m}$  and 416  $\mu\text{m}$  were the cut-offs which had, respectively, sensitivity and specificity of 99.17 % and 97.28 % for keratoconus and 85.11 % and 93.05 % for subclinical disease [35].

In the Pentacam, the Belin-Ambrósio Enhanced Ectasia Display (BAD) was designed for enhancing accuracy for screening ectatic corneal diseases. This consists on a comprehensive display that combines the standard and enhanced BFS elevation maps of the front and back surfaces, and the thickness distribution data. Different tomographic parameters are presented as the standard deviation from normality towards disease (d values): anterior and posterior elevation at the thinnest point (8 mm BFS), change in anterior and posterior elevation of the standard and enhanced BFS, thinnest value and location, PPI, ART and maximal curvature (KMax). This software provides a final deviation value (BAD-D) that combines the tomographic data, and is calculated based on linear regression analysis to optimize the sensitivity and specificity to detect ectasia [13, 33, 35]. BAD-D higher than 2.11 was a criteria with sensitivity and specificity of 99.59 and 100 % for diagnosing keratoconus, while for detecting mild or subclinical disease the criteria of higher than 1.22 provided 93.62 % sensitivity and 94.56 % specificity [35].

Although previous studies revealed that the BAD-D was the most accurate parameter in predicting ectasia risk, the integration of pre-operative clinical data has provided a further improvement of its accuracy [12, 47]. For example, we created the ectasia susceptibility score (ESS-I) based on the preoperative clinical and corneal tomography data from 23 cases that developed ectasia after LASIK and from 266 stable-LASIK with over 1 year of follow up. The regression formula combining BAD-D, age and RSB was calculated. The cut-off of 0.068 (6.8 % of relative risk) provided 100 % sensitivity and 94 % specificity, with better area under the receiver operating characteristic (ROC) curve (AUC=0.989; 95 % CI: 0.969–0.998) than all parameters, including the BAD-D (AUC=0.931; CI: 0.895–0.957; De Long,  $p > 0.001$ ). Therefore, the ESS-I enabled the calculation of the relative risk of developing ectasia accordingly to the BAD-D, age and RSB. The logarithmic function led to a binary outcome from zero to one, which represents the relative risk for ectasia (Fig. 12. 4). For example, a patient with 21 years-old, BAD-D of 0.9 would be at high risk of ectasia (24 %) with 350  $\mu\text{m}$  of RSB. But a patient with 21 years-old, BAD-D of 0.2 and RSB of 350  $\mu\text{m}$  would be at low risk (3 %). Also, a patient with 42 years old, BAD-D of 0.9 would have low ectasia risk (1 %) with RSB of 350  $\mu\text{m}$  [47]. This approach was demonstrated to improve the sensitivity and specificity for assessing ectasia risk among refractive candidates. Beyond the ESS-1, an enhanced approach was developed by the BrAIN (Brazilian Study Group of Artificial Intelligence and Corneal Analysis) including more tomographic parameters with demonstrated improvement in accuracy (<https://www.youtube.com/watch?v=d4jOG7jAPwU>).

## Beyond Corneal Tomography

Beyond pachymetric evaluation by corneal tomography, the advent of layered pachymetric tomography or “segmental tomography” by using optical coherence tomography (OCT) or very-high frequency ultrasound allows for epithelial thickness mapping, which may provide additional knowledge for ectasia risk detection [48–51]. For example, Reinstein and coworkers demonstrated improved specificity by verifying stability after LASIK in corneas with preoperative topographic abnormalities, but confirmed as non-ectasia susceptible by epithelial thickness profile in a retrospective case-control comparative study [40].

Nevertheless, corneal morphologic changes due to ectasia (including curvature, elevation, and thickness) seem to be secondary signs of a primary structural or biomechanical abnormality [15, 17]. Roberts and Dupps have proposed that there is a focal biomechanical failure in ectasia, rather than a generalized weakening [16]. Thereby, clinical evaluation of corneal elastic properties promises to enhance safety and efficiency of LVC [12, 15]. The Ocular Response Analyzer (ORA; Reichert, Buffalo, NY, USA) [13, 15], the Corvis ST (Oculus, Wetzlar, Germany) [13, 35] and Brillouin optical microscopy (Harvard Medical School, Boston, MA, USA) [52, 53] are promising technologies for the clinical evaluation of the biomechanical properties of corneal tissue. Even though, there is still no definitive screening parameter based on biomechanical analysis for clinical use to date. However, this is possible that future advents on molecular biology allow for a genetic evaluation that would characterize the risk for ectatic corneal diseases in the future.

## Postoperative Diagnosis

The diagnosis of ectasia should be considered when evaluating any refractive patient who had LVC. The main clinical characteristics of ectasia are progressive loss of vision associated with increasing levels of refractive error (usually myopia) and astigmatism. Ectasia is much more common after LASIK, but has also been reported after surface ablation procedures [3, 12, 54, 55]. The excimer ablation itself has a biomechanical impact on the cornea, but the LASIK flap has a more pronounced effect. Interestingly, there are reported cases of unilateral keratectasia after LASIK, while the fellow eye remained stable after photorefractive keratectomy (PRK) [39]. Interestingly, a potential benefit from surface ablation in preventing long-term ectasia has been proposed based on anecdotal reports [56].

In our clinical practice, we educate and encourage patients to undertake regular follow-up visits and not to rub the eyes. Although rare, it should be noted that such complication has a much better prognosis with detected and adequately managed at an early phase [11, 57–62]. When a post-LVC patient complains of decreased visual acuity, the clinician needs to perform a meticulous evaluation beyond refraction, considering wavefront aberrations, corneal architecture analysis (topography and tomography) along with general eye health evaluations, such as IOP assessment and



retinal exams. The integration of ancillary tests is essential to assess the corneal status. For example, corneal topography usually displays corneal steepening along with irregular astigmatism in cases with ectasia after LVC [3, 4, 42, 46, 63]. Changes in the wavefront analysis, such as increasing of high-order aberrations (particularly vertical coma, spherical aberration and trefoil aberrations), may also be present in these patients [64, 65]. Corneal tomography also aids to establish the diagnosis of ectasia after LVC [13, 33, 35]. Properly using imaging techniques, the clinician will be able to identify irregular astigmatism, which is present in the front surface of cornea, along with changes in the posterior elevation and pachymetry maps [13, 33, 35]. Changes in posterior corneal elevation have been studied to document long-term stability after LASIK, so that using the same BFS for the preoperative corneal information, less than 7  $\mu\text{m}$  on the maximal difference in the central 4.0 mm zone was found on stable LASIK cases [66]. Figure 12.5 shows the posterior elevation changes in a clinical example with post-LASIK ectasia. Progressive corneal thinning may also be present in these cases with ectasia after LVC [12, 33, 47, 67].

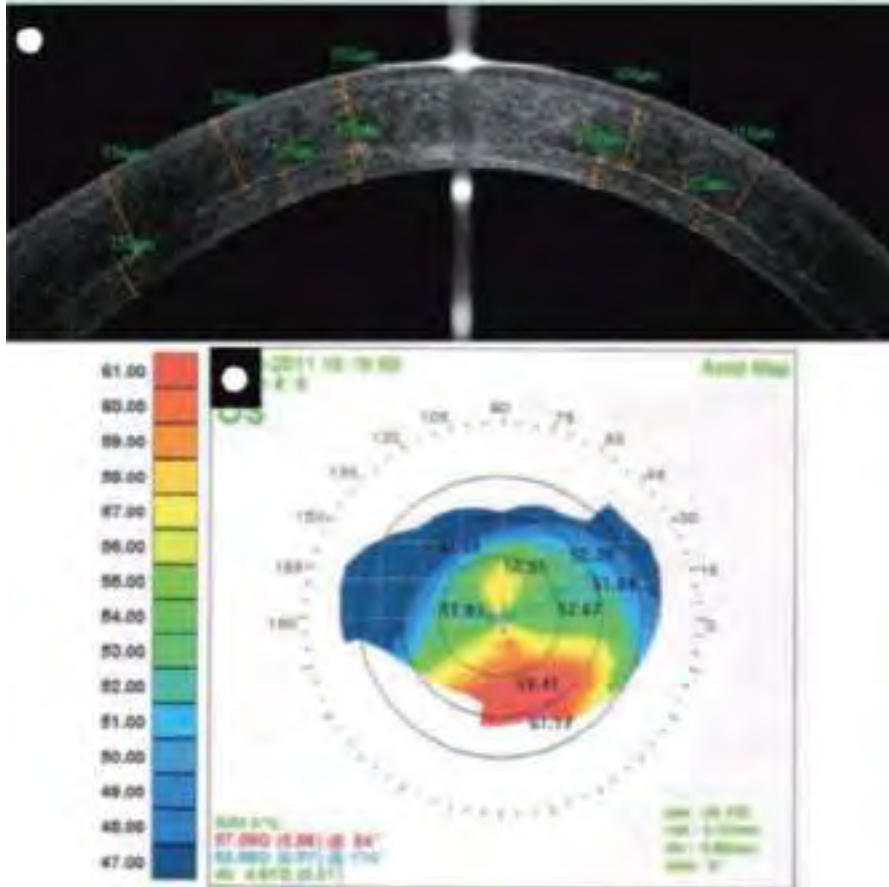
As there are other conditions that may induce irregular astigmatism (such as dry eye, irregular cuts or flaps complications), it is crucial to combine clinical data with complementary exams such as corneal tomography with posterior elevation and thickness profile for a proper diagnosis and treatment plan. In this context, understanding the clinical status prior to surgery is imperative, as well as the information regarding the procedure performed [12, 57, 64]. Topography, pachymetry, refractive error and visual acuity are the most relevant preoperative data [12, 57, 64].

Along with a complete and detailed evaluation of the current patient status, data related to the previous refractive surgery is needed to determine the reason for ectasia development, the prognosis and thereby, deciding best treatment strategy. Preoperative refractive status, along with the available corneal thickness and geometry data should be considered. Flap thickness, type of cut and maximum depth of photoablation are essential information for clinical decision.

The actual evaluation of flap geometry and thickness may be accomplished with spectral or Fourier domain OCT or very high frequency ultrasound (UBM) [12, 68]. Regarding the flap geometry, a flap created by femtosecond laser and having a planar configuration also revealed superiority in terms of biomechanical stability [68–70]. Previous studies also illustrated the major role of the flap in the biomechanical impact of LASIK procedures [69–71]. In several clinical cases, a thick flap was considered the cause of corneal ectasia after LASIK [20, 68, 72]. Fig. 12.6 shows a clinical example with ectasia after LASIK due to thick corneal flap.

## Treatment

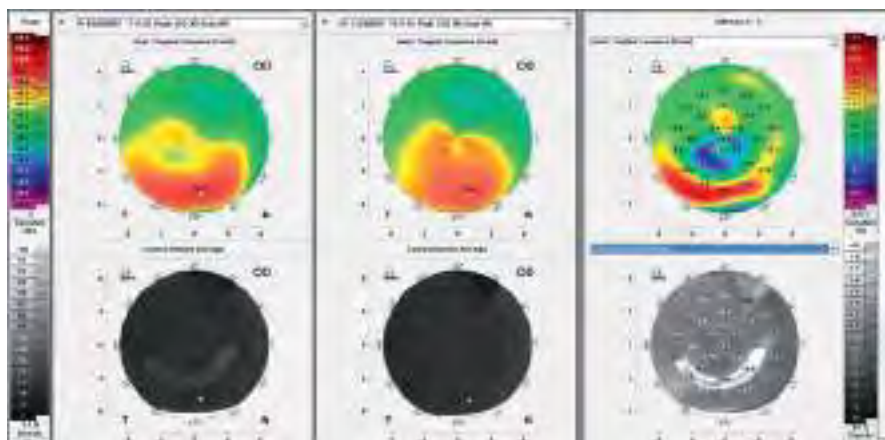
Once the diagnosis of ectasia is confirmed, the complete clinical picture should be considered in order to plan the best treatment approach for each patient. In a simple manner, treatment will aim to avoid progression of the disease and to provide visual rehabilitation (Table 12.2) [65, 73].



**Fig. 12.6** Ectasia after LASIK due to thick corneal flap: (Above) Corneal optical coherence tomography; (Below) Anterior sagittal map

**Table 12.2** Treatment options for ectasia after LVC

Patient education
Glasses
Contact lenses (including RGP, scleral, semi-scleral and hybrid)
Collagen cross-linking (CXL)
ICRS implantation
CXL plus
Cretan Protocol (PTK + CXL)
Athens Protocol (PTK/PRK + CXL)
CK + CXL
ICRS + CLX
Phakic IOL
Corneal transplantation (DALK or Penetrating Keratoplasty)

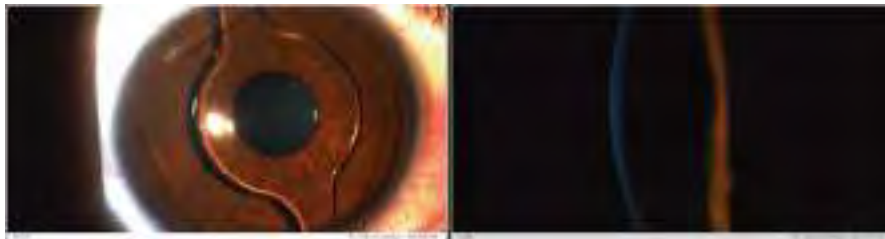

**Fig. 12.7** Post-op (left column), Pre-op (middle column) and differential (left column) anterior curvature and average densitometry maps of a post-LASIK ectasia case that underwent femtosecond assisted ICRS (Keraring SI6 150/250; Mediphacos, Belo Horizonte, Brazil) with improvement of uncorrected (20/400 to 20/60) and corrected distance visual (20/50 to 20/25) acuity

The same therapeutic and surgical approaches for keratoconus and other ectatic corneal diseases may be indicated in cases of ectasia after LVC [65]. This includes and starts with patient education and clarification of the possible need of corneal transplantation as a last option. However, there are important differences that should be considered between ectasia after LVC and keratoconus. First, refractive patients have much higher expectations and demands, since they previously performed refractive surgery with the goal of eliminating refractive error for eliminating or reducing the need for spectacles and contact lenses. Due to this reason, this is also important to consider medico-legal issues related to performing therapeutic procedures in such patients.

Glasses and contact lens fitting are the primary tools for restoring visual acuity and vision quality. While these options may be more difficult for these patients to accept, the role of patient education about the disease and the therapeutic options should be emphasized. As in keratoconus, the need for surgery is related to the risk of progression of ectasia and for visual rehabilitation [11, 65].

Corneal cross-linking procedures and implantation of intracorneal ring segments (ICRS) represent the major surgical alternatives for managing ectasia after LVC (Fig. 12.7) [46, 59, 60, 62, 65]. Phakic intraocular lens implantation may be indicated to treat residual refractive error once ectasia stabilization is achieved and the patient has adequate vision with spherical-cylindrical corrections (Fig. 12.8) [65, 73, 74]. Different combinations of procedures, such as the Athens or Cretan Protocols, are effective methods to improve visual quality and contact lens tolerance [58–60, 65, 75–77]. The ICRS implantation technique should be assisted with femtosecond laser. With this technology, the tunnel's depth is more precise and is associated with lower complication rates [59]. Since the introduction of cross-linking, the excimer laser became a useful tool for the ectasia management [58]. The Athens Protocol (PTK/custom PRK + CXL) is more suitable in patients who have sufficient



**Fig. 12.8** Anterior Chamber phakic IOL (Acrysof Cachet; Alcon Laboratories, Fort Worth, USA) implantation 3 months after collagen cross-linking. Manifest refraction prior to implantation was  $-11.50 -0.75 \times 43$ , giving 20/30+. Post-op uncorrected visual acuity was 20/30+2. Endothelial cell count remains stable 3 years after the procedure with minimal change on curvature maps. Avoiding eye rubbing is fundamental for these cases

pachymetry after the ablation to allow the crosslinking treatment [58, 78]. However, the Cretan Protocol (PTK+CXL) along with the use of hypo-osmolar Riboflavin solutions and/or distilled water may be considered in cases with corneas thinner than  $400 \mu\text{m}$  [76, 79–81]. The flap geometry analysis is also important for planning the treatment. For example, cases with very thick flap have a lesser chance of success with ICRS implantation because there is no tissue support for the ring segment [68, 72]. Cross-linking procedures are more appropriate options for these cases [65, 72, 76, 77]. Corneal transplant procedures are indicated as a least option for visual rehabilitation when other surgical modalities fail. Deep lamellar keratoplasty should be always considered prior to penetrating keratoplasty [65].

## Conclusion

The main goals of refractive surgery screening are not only to identify cases with mild ectasia, but also to characterize each cornea in terms of its susceptibility to undergo biomechanical failure and ectasia. In fact, this approach may enable enhancing efficiency and predictability of corneal procedures. The standard screening criteria, based on Placido-disk based corneal topography and CCT, has important limitations regarding sensitivity and specificity. The key concept that ectasia can occur even in the absence of anterior surface changes should be present among refractive surgeons. This very mild disease state may explain cases of ectasia reported after LASIK without identifiable risk factors (and when excluding a thick flap or excessive tissue ablation). New technologies have already demonstrated the potential for improving the accuracy of ectasia risk detection. While we do not currently have a definitive clinical method for assessing the corneal biomechanical properties, appropriate corneal geometrical analysis is essential for understanding the susceptibility of each cornea to biomechanical failure. However, recent advances related provide promising approaches to elucidate corneal biomechanical properties. As shown by EES-I, integration of clinical data with complementary exams

allows an enhanced screening approach that increases the accuracy to detect susceptible cases. Validation studies and further improvement of artificial intelligence approached such as considered by the BRAIN (Brazilian Artificial Intelligence for Corneal Analysis) are currently being performed. In future, screening approaches for detecting ectasia risk should consider a combination of patient-related data and procedure-related parameters by using simulation analysis and artificial intelligence strategies. As also shown, the integration of complementary exams with clinical data can also ensure a proper diagnosis and the most appropriate treatment for cases with post refractive surgery ectasia.

## References

1. Seiler T, Koufala K, Richter G. Iatrogenic keratectasia after laser in situ keratomileusis. *J Refract Surg.* 1998;14(3):312–7.
2. Binder PS. Analysis of ectasia after laser in situ keratomileusis: risk factors. *J Cataract Refract Surg.* 2007;33(9):1530–8.
3. Binder PS, Lindstrom RL, Stulting RD, et al. Keratoconus and corneal ectasia after LASIK. *J Cataract Refract Surg.* 2005;31(11):2035–8.
4. Binder PS, Trattler WB. Evaluation of a risk factor scoring system for corneal ectasia after LASIK in eyes with normal topography. *J Refract Surg.* 2010;26(4):241–50.
5. Dawson DG, Randleman JB, Grossniklaus HE, et al. Corneal ectasia after excimer laser keratorefractive surgery: histopathology, ultrastructure, and pathophysiology. *Ophthalmology.* 2008;115(12):2181–91.e2181.
6. Ou RJ, Shaw EL, Glasgow BJ. Keratectasia after laser in situ keratomileusis (LASIK): evaluation of the calculated residual stromal bed thickness. *Am J Ophthalmol.* 2002;134(5):771–3.
7. Pallikaris IG, Kymionis GD, Astyrakakis NI. Corneal ectasia induced by laser in situ keratomileusis. *J Cataract Refract Surg.* 2001;27(11):1796–802.
8. Spadea L, Cantera E, Cortes M, Conocchia NE, Stewart CW. Corneal ectasia after myopic laser in situ keratomileusis: a long-term study. *Clin Ophthalmol.* 2012;6:1801–13.
9. Rad AS, Jabbarvand M, Saifi N. Progressive keratectasia after laser in situ keratomileusis. *J Refract Surg.* 2004;20(5 Suppl):S718–22.
10. Moshirfar M, Smedley JG, Muthappan V, Jarsted A, Ostler EM. Rate of ectasia and incidence of irregular topography in patients with unidentified preoperative risk factors undergoing femtosecond laser-assisted LASIK. *Clin Ophthalmol.* 2014;8:35–42.
11. Randleman JB, Russell B, Ward MA, Thompson KP, Stulting RD. Risk factors and prognosis for corneal ectasia after LASIK. *Ophthalmology.* 2003;110(2):267–75.
12. Ambrósio Jr R, Randleman JB. Screening for ectasia risk: what are we screening for and how should we screen for it? *J Refract Surg.* 2013;29(4):230–2.
13. Ambrósio Jr R, Nogueira LP, Caldas DL, et al. Evaluation of corneal shape and biomechanics before LASIK. *Int Ophthalmol Clin.* 2011;51(2):11–38.
14. Ambrósio R, Jr., Ramos I, Faria-Correia F, Belin MW. Tomographic Screening for Ectasia Susceptibility – analysis must go beyond corneal curvature and central thickness. *Cataract Refract Surg Today Eur.* 2012;20–5.
15. Dupps Jr WJ, Wilson SE. Biomechanics and wound healing in the cornea. *Exp Eye Res.* 2006;83(4):709–20.
16. Roberts CJ, Dupps Jr WJ. Biomechanics of corneal ectasia and biomechanical treatments. *J Cataract Refract Surg.* 2014;40(6):991–8.
17. Dawson DG, Grossniklaus HE, McCarey BE, Edelhauser HF. Biomechanical and wound healing characteristics of corneas after excimer laser keratorefractive surgery: is there a difference

- between advanced surface ablation and sub-Bowman's keratomileusis? *J Refract Surg.* 2008;24(1):S90–6.
18. Randleman JB, Woodward M, Lynn MJ, Stulting RD. Risk assessment for ectasia after corneal refractive surgery. *Ophthalmology.* 2008;115(1):37–50.
  19. Santhiago MR, Smadja D, Gomes BF, et al. Association between the percent tissue altered and post-laser in situ keratomileusis ectasia in eyes with normal preoperative topography. *Am J Ophthalmol.* 2014;158(1):87–95.e81.
  20. Santhiago MR, Smadja D, Wilson SE, Randleman JB. Relative contribution of flap thickness and ablation depth to the percentage of tissue altered in ectasia after laser in situ keratomileusis. *J Cataract Refract Surg.* 2015;41(11):2493–500.
  21. Padmanabhan P, Aiswaryah R, Abinaya Priya V. Post-LASIK keratectasia triggered by eye rubbing and treated with topography-guided ablation and collagen cross-linking – a case report. *Cornea.* 2012;31(5):575–80.
  22. Ambrosio Jr R, Klyce SD, Wilson SE. Corneal topographic and pachymetric screening of keratorefractive patients. *J Refract Surg.* 2003;19(1):24–9.
  23. Randleman JB, Trattler WB, Stulting RD. Validation of the Ectasia Risk Score System for preoperative laser in situ keratomileusis screening. *Am J Ophthalmol.* 2008;145(5):813–8.
  24. Chan CC, Hodge C, Sutton G. External analysis of the Randleman Ectasia Risk Factor Score System: a review of 36 cases of post LASIK ectasia. *Clin Experiment Ophthalmol.* 2010;38(4):335–40.
  25. Ambrosio Jr R, Dawson DG, Salomao M, Guerra FP, Caiado AL, Belin MW. Corneal ectasia after LASIK despite low preoperative risk: tomographic and biomechanical findings in the unoperated, stable, fellow eye. *J Refract Surg.* 2010;26(11):906–11.
  26. Klein SR, Epstein RJ, Randleman JB, Stulting RD. Corneal ectasia after laser in situ keratomileusis in patients without apparent preoperative risk factors. *Cornea.* 2006;25(4):388–403.
  27. Duffey RJ, Hardten DR, Lindstrom RL, et al. Ectasia after refractive surgery. *Ophthalmology.* 2008;115(10):1849; autor reply 1849–50.
  28. Ramos IC, Correa R, Guerra FP, et al. Variability of subjective classifications of corneal topography maps from LASIK candidates. *J Refract Surg.* 2013;29(11):770–5.
  29. Rabinowitz YS, Rasheed K. KISA% index: a quantitative videokeratography algorithm embodying minimal topographic criteria for diagnosing keratoconus. *J Cataract Refract Surg.* 1999;25(10):1327–35.
  30. Rabinowitz YS. Videokeratographic indices to aid in screening for keratoconus. *J Refract Surg.* 1995;11(5):371–9.
  31. Maeda N, Klyce SD, Smolek MK. Comparison of methods for detecting keratoconus using videokeratography. *Arch Ophthalmol.* 1995;113(7):870–4.
  32. Maeda N, Klyce SD, Tano Y. Detection and classification of mild irregular astigmatism in patients with good visual acuity. *Surv Ophthalmol.* 1998;43(1):53–8.
  33. Belin MW, Ambrosio R. Scheimpflug imaging for keratoconus and ectatic disease. *Indian J Ophthalmol.* 2013;61(8):401–6.
  34. Saad A, Gatinel D. Topographic and tomographic properties of forme fruste keratoconus corneas. *Invest Ophthalmol Vis Sci.* 2010;51(11):5546–55.
  35. Ambrosio Jr R, Valbon BF, Faria-Correia F, Ramos I, Luz A. Scheimpflug imaging for laser refractive surgery. *Curr Opin Ophthalmol.* 2013;24(4):310–20.
  36. Smadja D, Touboul D, Cohen A, et al. Detection of subclinical keratoconus using an automated decision tree classification. *Am J Ophthalmol.* 2013;156(2):237–46.e231.
  37. Amsler M. The “forme fruste” of keratoconus. *Wien Klin Wochenschr.* 1961;73:842–3.
  38. Amsler M. Some data on the problem of keratoconus. *Bull Soc Belge Ophthalmol.* 1961;129:331–54.
  39. Hodge C, Lawless M, Sutton G. Keratectasia following LASIK in a patient with uncomplicated PRK in the fellow eye. *J Cataract Refract Surg.* 2011;37(3):603–7.
  40. Reinstein DZ, Archer TJ, Gobbe M. Stability of LASIK in topographically suspect keratoconus confirmed non-keratoconic by Artemis VHF digital ultrasound epithelial thickness mapping: 1-year follow-up. *J Refract Surg.* 2009;25(7):569–77.

41. Tuli SS, Iyer S. Delayed ectasia following LASIK with no risk factors: is a 300-microm stromal bed enough? *J Refract Surg.* 2007;23(6):620–2.
42. Geggel HS, Talley AR. Delayed onset keratectasia following laser in situ keratomileusis. *J Cataract Refract Surg.* 1999;25(4):582–6.
43. Ambrosio Jr R. A revolução dos lasers de femtossegundo na oftalmologia. *Rev Bras Oftalmol.* 2011;70(4):207–10.
44. Ambrosio Jr R, Belin MW. Imaging of the cornea: topography vs tomography. *J Refract Surg.* 2010;26(11):847–9.
45. Ambrosio Jr R, Alonso RS, Luz A, Coca Velarde LG. Corneal-thickness spatial profile and corneal-volume distribution: tomographic indices to detect keratoconus. *J Cataract Refract Surg.* 2006;32(11):1851–9.
46. Ambrosio Jr R, Caiado AL, Guerra FP, et al. Novel pachymetric parameters based on corneal tomography for diagnosing keratoconus. *J Refract Surg.* 2011;27(10):753–8.
47. Ambrósio Jr R, Ramos I, Lopes B, et al. Assessing ectasia susceptibility prior to LASIK: the role of age and residual stromal bed (RSB) in conjunction to Belin-Ambrósio deviation index (BAD-D). *Rev Bras Oftalmol.* 2014;73:75–80.
48. Li Y, Tan O, Brass R, Weiss JL, Huang D. Corneal epithelial thickness mapping by Fourier-domain optical coherence tomography in normal and keratoconic eyes. *Ophthalmology.* 2012;119(12):2425–33.
49. Reinstein DZ, Archer TJ, Gobbe M. Corneal epithelial thickness profile in the diagnosis of keratoconus. *J Refract Surg.* 2009;25(7):604–10.
50. Reinstein DZ, Archer TJ, Urs R, Gobbe M, RoyChoudhury A, Silverman RH. Detection of keratoconus in clinically and algorithmically topographically normal fellow eyes using epithelial thickness analysis. *J Refract Surg.* 2015;31(11):736–44.
51. Reinstein DZ, Gobbe M, Archer TJ, Silverman RH, Coleman DJ. Epithelial, stromal, and total corneal thickness in keratoconus: three-dimensional display with artemis very-high frequency digital ultrasound. *J Refract Surg.* 2010;26(4):259–71.
52. Scarcelli G, Pineda R, Yun SH. Brillouin optical microscopy for corneal biomechanics. *Invest Ophthalmol Vis Sci.* 2012;53(1):185–90.
53. Scarcelli G, Yun SH. In vivo Brillouin optical microscopy of the human eye. *Opt Express.* 2012;20(8):9197–202.
54. Mohammadpour M. Corneal ectasia after LASIK in one eye and uneventful PRK in the fellow eye. *J Cataract Refract Surg.* 2007;33(10):1677; author reply 1677–8.
55. Randleman JB, Caster AI, Banning CS, Stulting RD. Corneal ectasia after photorefractive keratectomy. *J Cataract Refract Surg.* 2006;32(8):1395–8.
56. Khochtali S, Colin J, Touboul D, Binder PS. Does photorefractive keratectomy affect keratoconus progression? *J Refract Surg.* 2010;26(12):925–6.
57. Ambrosio Jr R, Wilson SE. Complications of laser in situ keratomileusis: etiology, prevention, and treatment. *J Refract Surg.* 2001;17(3):350–79.
58. Kanellopoulos AJ, Binder PS. Management of corneal ectasia after LASIK with combined, same-day, topography-guided partial transepithelial PRK and collagen cross-linking: the Athens protocol. *J Refract Surg.* 2011;27(5):323–31.
59. Pinero DP, Alio JL, Uceda-Montanes A, El Kady B, Pascual I. Intracorneal ring segment implantation in corneas with post-laser in situ keratomileusis keratectasia. *Ophthalmology.* 2009;116(9):1665–74.
60. Vinciguerra P, Camesasca FI, Albe E, Trazza S. Corneal collagen cross-linking for ectasia after excimer laser refractive surgery: 1-year results. *J Refract Surg.* 2010;26(7):486–97.
61. Wang JC, Hufnagel TJ, Buxton DF. Bilateral keratectasia after unilateral laser in situ keratomileusis: a retrospective diagnosis of ectatic corneal disorder. *J Cataract Refract Surg.* 2003;29(10):2015–8.
62. Yam JC, Cheng AC. Prognostic factors for visual outcomes after crosslinking for keratoconus and post-LASIK ectasia. *Eur J Ophthalmol.* 2013;23(6):799–806.
63. Randleman JB. Post-laser in-situ keratomileusis ectasia: current understanding and future directions. *Curr Opin Ophthalmol.* 2006;17(4):406–12.

64. Ambrosio Jr R, Jardim D, Netto MV, Wilson SE. Management of unsuccessful LASIK surgery. *Compr Ophthalmol Update*. 2007;8(3):125–41; discussion 143–4.
65. Faria-Correia F, Luz A, Ambrósio Jr R. Managing corneal ectasia prior to keratoplasty. *Expert Rev Ophthalmol*. 2015;10(1):22–48.
66. Ciolino JB, Khachikian SS, Cortese MJ, Belin MW. Long-term stability of the posterior cornea after laser in situ keratomileusis. *J Cataract Refract Surg*. 2007;33(8):1366–70.
67. Ciolino JB, Khachikian SS, Belin MW. Comparison of corneal thickness measurements by ultrasound and Scheimpflug photography in eyes that have undergone laser in situ keratomileusis. *Am J Ophthalmol*. 2008;145(1):75–80.
68. Randleman JB, Hebson CB, Larson PM. Flap thickness in eyes with ectasia after laser in situ keratomileusis. *J Cataract Refract Surg*. 2012;38(5):752–7.
69. Knox Cartwright NE, Tyrer JR, Jaycock PD, Marshall J. Effects of variation in depth and side cut angulations in LASIK and thin-flap LASIK using a femtosecond laser: a biomechanical study. *J Refract Surg*. 2012;28(6):419–25.
70. Medeiros FW, Sinha-Roy A, Alves MR, Dupps Jr WJ. Biomechanical corneal changes induced by different flap thickness created by femtosecond laser. *Clinics (Sao Paulo)*. 2011;66(6):1067–71.
71. Yip YW, Yu MC, Jhanji V. Randomized, contralateral eye study to evaluate the effect of standard and inverted side-cut angle on corneal biomechanical properties during femtosecond laser-assisted in situ keratomileusis. *Acta Ophthalmol*. 2014;92(6):e437–42.
72. Valbon BF, Ambrósio RJ, Glícéria J, Santos R, Luz A, Alves MR. Unilateral corneal ectasia after Bilateral LASIK: the thick flap counts. *Int J Kerat Ect Cor Dis*. 2013;2(2):79–83.
73. Ambrosio R, Jr. Intracorneal ring segment, phakic IOL implantation enable keratoconus management without keratoplasty. *Ocul Surg News US Ed*. 2011.
74. Kymionis GD, Grentzelos MA, Karavitaki AE, Zotta P, Yoo SH, Pallikaris IG. Combined corneal collagen cross-linking and posterior chamber toric implantable collamer lens implantation for keratoconus. *Ophthalmic Surg Lasers Imaging*. 2011;42 Online:e22–5.
75. Coskunseven E, Kymionis GD, Tsiklis NS, et al. Complications of intrastromal corneal ring segment implantation using a femtosecond laser for channel creation: a survey of 850 eyes with keratoconus. *Acta Ophthalmol*. 2011;89(1):54–7.
76. Kymionis GD, Grentzelos MA, Kankariya VP, Pallikaris IG. Combined transepithelial phototherapeutic keratectomy and corneal collagen crosslinking for ectatic disorders: cretan protocol. *J Cataract Refract Surg*. 2013;39(12):1939.
77. Kymionis GD, Grentzelos MA, Portaliou DM, Kankariya VP, Randleman JB. Corneal collagen cross-linking (CXL) combined with refractive procedures for the treatment of corneal ectatic disorders: CXL plus. *J Refract Surg*. 2014;30(8):566–76.
78. Kanellopoulos AJ, Asimellis G. Keratoconus management: long-term stability of topography-guided normalization combined with high-fluence CXL stabilization (the Athens Protocol). *J Refract Surg*. 2014;30(2):88–93.
79. Kozobolis V, Labiris G, Gkika M, Sideroudi H. Additional applications of corneal cross linking. *Open Ophthalmol J*. 2011;5:17–8.
80. Mastropasqua L, Nubile M, Calienno R, et al. Corneal cross-linking: intrastromal riboflavin concentration in iontophoresis-assisted imbibition versus traditional and transepithelial techniques. *Am J Ophthalmol*. 2014;157(3):623–30.e621.
81. Mastropasqua L, Nubile M, Lanzini M, et al. Morphological modification of the cornea after standard and transepithelial corneal cross-linking as imaged by anterior segment optical coherence tomography and laser scanning in vivo confocal microscopy. *Cornea*. 2013;32(6):855–61.



**Part V**  
**Complications and Management in**  
**Phototherapeutic and Laser**  
**Transplant Surgery**

# Chapter 13

## Therapeutic Excimer Ablation

Johannes Steinberg, Stephan J. Linke, and Toam R. Katz

### Phototherapeutic Keratectomy (PTK)

Johannes Steinberg and Stephan J. Linke

Next to corneal refractive laser procedures, the therapeutic laser application in the form of phototherapeutic keratectomy (PTK) is an essential tool in the arsenal of modern corneal surgery.

The PTK has been approved by the FDA in 1995 [1]. It is an Excimer-laser-based procedure, which ablates superficial corneal tissue with the principle of photoablation (193 nm wavelength), which has already been described in Chap. 1 ([Surface ablation \(PRK, LASEK, Epi-LASIK\) overview](#)).

Different from the PRK, the PTK does not aim to change the corneal curvature and thereby the corneal refraction. On the contrary, the goal of the PTK is to remove pathological corneal tissue without altering corneal refraction. Thereby it is an effective and minimal invasive treatment option for superficial corneal pathologies. PTK is often a first line therapy and can successfully delay or avoid more aggressive corneal surgeries. The main indications for PTK are epithelial adhesion pathologies (recurrent erosion), superficial corneal opacifications and, if used as a topography-based keratectomy (TBK), the treatment of superficial corneal irregularities/asymmetry.

---

J. Steinberg (✉)  
zentrumsehstärke, Hamburg, Germany  
e-mail: [steinberg@zentrumsehstaerke.de](mailto:steinberg@zentrumsehstaerke.de)

S.J. Linke • T.R. Katz  
Department of Ophthalmology, University Medical Center Hamburg Eppendorf,  
Martinistr. 52, 20246 Hamburg, Germany

CareVision Germany, Ruesterst. 1, 60325 Frankfurt/Main, Germany  
e-mail: [slinke@uke.de](mailto:slinke@uke.de)

The next section concentrates on special aspects and complications of the PTK, whereas the TBK will be discussed separately in this book.

## ***General Considerations***

### **The Right Indication**

The success of PTK is strongly correlated with the correct indication! Pathologies originating from the cornea and involving the anterior corneal layers can often be healed or at least be significantly improved by the right usage of the Excimer laser. On the other hand clinical symptoms can be misleading. For example blepharitis related recurrent foreign body sensation with only secondary corneal involvement can mimic recurrent erosion. In this case PTK will not improve the situation of the patient. In contrast wound healing will be delayed and symptoms aggravated. Another example are small paracentral corneal irregularities/scars. Technically it is easy to remove these scars, but the irregularity will persist and often spectacle corrected vision will not improve significantly. The use of a masking substance may help to smooth the surface but the expected visual improvement will not occur, if the main cause were topographic irregularities causing higher order aberrations.

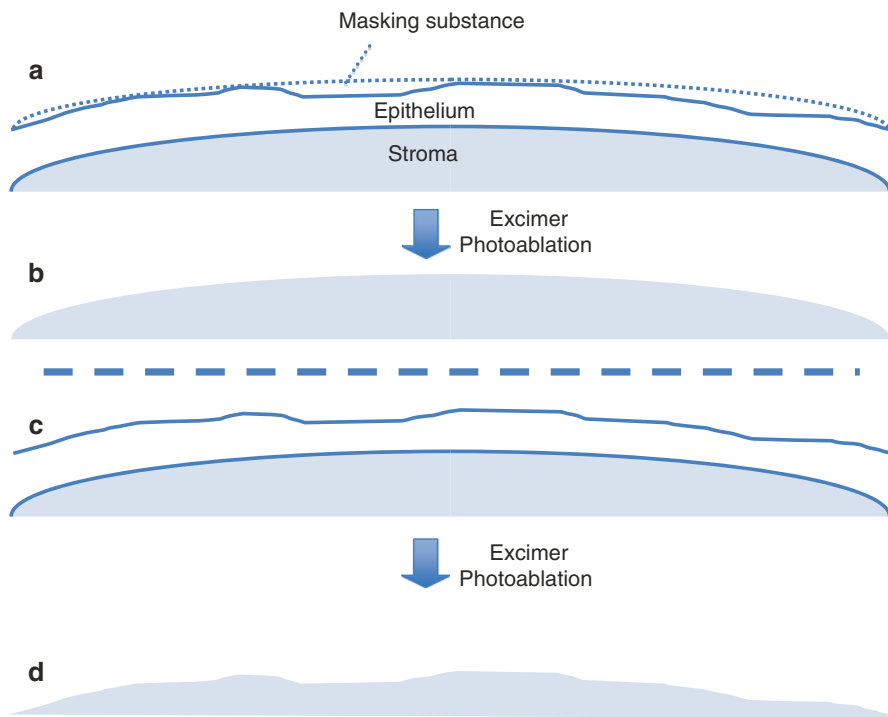
With regard to the importance of the correct indication and the special characteristics associated with the different modalities, we will discuss ‘Specific aspects of the PTK in different indications’ down below.

### **Maintaining a Homogenous Corneal Surface After PTK**

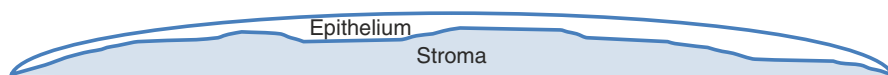
As mentioned above, the PTK aims for a refractive-neutral ablation of the anterior cornea. The challenge is to achieve this theoretically ideal situation despite the challenges of the pathologically altered cornea. These are an irregular epithelium (EBMD), corneal scars, corneal stromal dystrophies and the uneven epithelial thickness with a thicker epithelial layer in the periphery compared to the central area as well as the aspheric shape of the cornea.

To overcome these hurdles, different strategies are available:

- (a) In case of an irregular epithelial surface, a regular Bowmans’ lamella and the absence of epithelium involving scars, the preferred method to remove the epithelium should be to start with an alcohol-assisted abrasio corneae to ensure a homogenous corneal (Bowmans’ lamella) surface. In a second step, the Excimer-ablation of Bowman/stroma can be conducted. If you prefer transepithelial PTK (meaning removing also the epithelium with the Excimer-laser), you have to consider masking/smoothing substances. The application of a moderately viscous solution (for example Vismed) during therapeutic Excimer laser keratectomy enhances the smoothing effect of surface ablation, because the ablation rate of these substances equals the ablation rate of corneal tissue (Fig. 13.1a, b) [2]. If masking substances are not used during ablation these irregularities might be preserved and you risk persistent post-treatment topo-



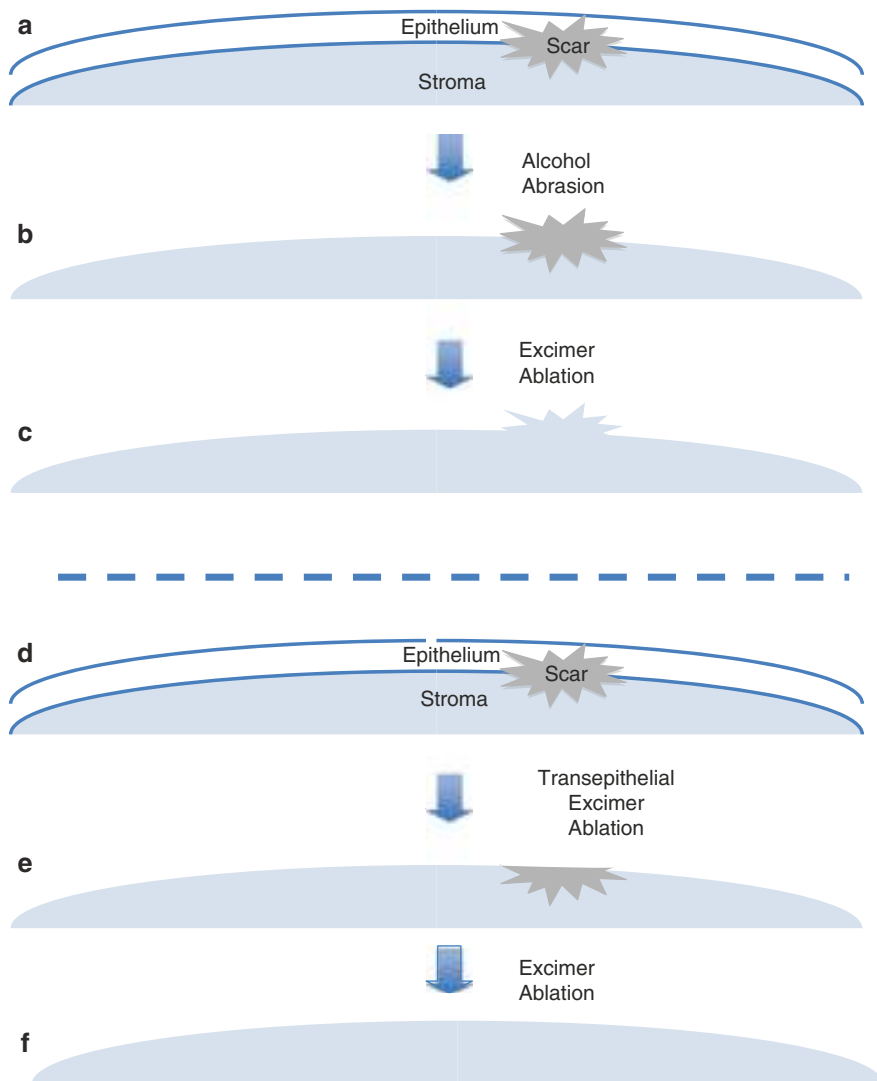
**Fig. 13.1** Transepithelial PTK in a cornea with an irregular epithelium using masking substances (a, b), or (falsely) treating without masking substances (c, d)



**Fig. 13.2** Cornea with an irregular bowman-lamella/stromal surface

graphic irregularities. Epithelial remodelling can compensate for superficial irregularities (Fig. 13.1c, d), however the expected success of postoperative epithelial remodeling is not (yet) to predict preoperatively

If an irregular bowman-lamella/stromal surface before the PTK exists, removing the epithelium with alcohol would also consequence in an uneven corneal surface (see also Fig. 13.2). Because the epithelium can compensate local irregularities of the corneal stroma, you should be aware of the possibility of an irregular stromal surface despite of a regular topography. In the future high resolution swept-source OCT might prove helpful in differentiating irregularities at the distinct anatomical levels, as described later in chapter TBK. Up to then, you have to base your decision on a thorough anamnesis (i.e. ask for trauma, older infections etc.) and a detailed slit-lamp-examination. If you expect an irregular Bowman, you should perform a transepithelial PTK without masking substances. If you performed an alcohol abra-



**Fig. 13.3** PTK of a cornea with an epithelium-involving (hypertrophic) scar treated either (falsely) with alcohol PTK (a–c), or with transepithelial Excimer-Ablation (d–f)

sion and get a suspicious result after removing the epithelium, you can use masking substances during the Excimer ablation.

Unpredictable post-PTK visual acuity and quality results might occur, if the epithelium is alcohol assisted removed as a first step followed by the PTK in patients with epithelium involving corneal scars (See Fig. 13.3a–c). In these cases, a transepithelial PTK should be performed (Fig. 13.3d, e).

## Avoiding Unpredictable Refractive Changes after PTK

Even if all the above-mentioned aspects regarding the first step of the PTK have been considered, a risk of a refractive shift after PTK remains. Next to unwanted inflammatory processes in the course of the wound healing response, which potentially could affect the corneal curvature/topography, the most important (risk) factor is the aspheric corneal shape. To ensure a refraction-neutral ablation, the profile has to be adjusted to the individual corneal surface and asphericity (Q value) as accurate as possible. Despite the aspheric ablation profile (wavefront optimized or wavefront based) of modern PTK-strategies and the consideration of the patients k-values, interpersonal/individual variations can lead to refractive changes after PTK. Although these refractive changes tend to be only minor, they still can be very unsatisfying for the patient, especially in case of a higher ablation depth [3]. Depending on the laser-profile, the refractive change can be different. Logically a high ablation ( $>80\ \mu\text{m}$ ) and smaller optical zones will change the refractive and optical properties of the cornea more significantly than a low ablation depth ( $<20\ \mu\text{m}$ ) and larger optical zones. On the one hand, a too oblate ablation profile would lead to an increased ablation at the periphery and a myopic shift due to a protruding/steepening central corneal surface. On the other hand, a pronounced prolate profile would accentuate the central ablation leading to a hyperopic shift after the PTK. The height of the refractive shift correlates with the ablated tissue. In case of a transepithelial PTK, the risk of unwanted refractive changes increase: If the epithelium is ablated with a too oblate or prolate ablation profile, the simultaneous presence of areas with still remaining epithelium and areas with already ablated bowman-lamellae (for example central Bowmans ablation and remaining epithelium in the periphery in a too prolate ablation profile (also to be seen as the central bowman-reflex surrounded by still existing epithelium-reflexes shown in the video – file “slides tprk”), adds to the following PTK-steps. Occasionally, hyperopic shifts have been described when deeper ablation depths have been used [4, 5]. Interestingly, analyzing our data of more than 100 PTKs for recurrent erosion with the Allegretto Wavelight Excimer Laser System (PTK modus: optical zone 7.0 mm, ablation depth 15  $\mu\text{m}$ ), revealed a myopic shift of 0.5 diopters (D) average (mean sphere before PTK:  $+0.29 (\pm 1.57)$  D; mean sphere after PTK:  $-0.33 (\pm 1.93)$  D;  $P=0.003$ ). A special ablation nomogram may compensate for the induced prolativity by defining a target asphericity of  $-0.25$  to  $-0.3$  (“Q value”) in the Wavelight Allegretto “F-CAT” software. Other coarser solutions are adding a refractive correction of  $-0.5$  D with 6.5 mm optical zone or choosing a large optical zone decreases the risk of an unwanted keratometric change. The risk of a refractive change due to the PTK has to be a central part of every informed consent form!

## Pain Management and Infections

See section ‘Early postoperative complications’ in the chapter ‘Complications of refractive surface ablation (SA)’

## *Specific Aspects of the PTK in Different Indications*

### **Recurrent Erosion**


One of the main indications for the PTK in ophthalmology is the recurrent erosion syndrome caused by either a former corneal trauma leading to an epithelial adhesion disorder, or an underlying epithelial-basement-dystrophy (EBMD; IC3D-classification) [6]. Typical clinical signs are foreign body sensation especially during the night-time and in the morning because of an increased destabilization of the epithelium due to hypoxicity and sudden opening of the eye. Reduced visual acuity is a consequence of centrally located epithelial defects. Refractive instability is another typical sign due to epithelial remodeling/hyper-proliferation and an unstable epithelial sheet. A cornea with EBMD is displayed in Fig. 13.4.

Whereas the PTK itself is a simple procedure, some special aspects have to be considered when treating patients with recurrent corneal erosion:

- (a) **Methodology:** Because of the often rough and irregular epithelium, the Excimer-Ablation should follow a mechanical debridement of the epithelium and must not be performed as a trans-epithelial PTK approach. The recurrent erosion and the potentially underlying corneal dystrophy causes an irregular epithelial thickness and not perfectly attached epithelial sheet, which might lead to an incomplete epithelial ablation and a consecutively inhomogeneous ablation of the underlying bowman lamella. In most of the cases, the epithelium can easily be removed with a sponge without the additional help of alcohol. This intraoperative observation strengthens the diagnosis of recurrent corneal erosion.

Because of recurrence-rates up to 50% after solely mechanical abrasion without any further treatment, alternative strategies should be preferred [7]. One example is the mechanical abrasion followed by a mechanical manipulation of the bowman-lamella (bur/hockey-knife or similar). This strategy reduces the recurrence rate down to less than 10% [8, 9].

Our current standard protocol for the treatment of recurrent erosion is, to remove the epithelium mechanically with or without the additional use of 20%-alcohol-



**Fig. 13.4** Cornea with an epithelial-basement-dystrophy (EBMD)

solution and then perform an Excimer ablation of 15 microns with an optical zone of 7.0 mm and thereby remove the entire bowman-lamella (Hamburger Schema). Further, we perform the PTK without the additional use of MMC to increase the post-surgical epithelial adhesion strength due to the triggered inflammatory process [10]. After the treatment, we place a bandage contact lens on the cornea, which is removed 5 days later. The patient takes ketorolac eyedrops for 5 days (every hour on the treatment day after the SA and 4 times daily on day 2–5) and lubricants every hour until the CL is removed. From then on, lubricants should be continued for at a couple of weeks at least 3–4 times/day to ensure patients comfort and a stable corneal surface. According to our data, this “aggressive” PTK leads to recurrent rates of only 3.6% after the first treatment (2 recurrences in 55 patients; mean follow-up: 23 month). In our sample, the recurrences occurred within the first 4 month after the PTK. After a re-treatment with the same PTK strategy, no further recurrences occurred [10].

Especially in recurrent erosion, combining PTK and PRK seems natural in patients with know ametropia. Zaidman et al. reported a case series of 19 myopic/ astigmatic eyes of 14 patients treated for recurrent erosion by PTK/PRK [3]. After manual debridement of the corneal epithelium, a PTK with a 6.5 mm optical zone, followed by a PRK for the refractive error was performed. The treatment was based on the cycloplegic manifest refraction, but in patients with difficult refractive measurement due to the irregular astigmatism, the treatment was based on the most recent spectacle refraction. Mean presurgical myopia was  $-3.76 \pm 1.97D$ , mean astigmatism was  $+0.96 \pm 74D$ . Three month postoperatively, the mean myopia was  $-0.53 \pm 0.85D$  and the mean astigmatism was  $+0.58 \pm 0.46D$ . They reported, that ‘six month after surgery, 15 of 17 eyes were within  $\pm 1.0 D$  of emmetropia and 12 of 17 eyes were within  $\pm 0.5 D$ ’ and that ‘fourteen of 17 eyes had not gained or lost any vision, 2 eyes gained 1 line of vision, and 1 eye had lost 1 line of vision’ [3]. Based on their findings, they concluded, that the combined PTK/PRK Excimer laser surgery ‘is safe and effective in eliminating the symptoms of pain, diplopia, and ghost images in patients with these corneal disorders. The results are predictable, reproducible, and stable’ [3].

This coincides with our experience in combining PTK/PRK. The main restriction of combining PTK and PRK is the only reduced accuracy of presurgical refraction because of the mostly irregular corneal surface. Therefore, if you want to offer the patient not only a relieve of the recurrent-erosion-associated symptoms, but also an improved uncorrected visual acuity after the treatment, you should take the time to comprehensively explain the patient the chances and limitations of this approach. By combining PTK/PRK, no further medical risks like delayed wound healing or higher recurrence rate have to be expected. So, if you can exclude any risks for post-treatment ectasia, both, the patient and you, the physician, will get a chance to make the most of the situation.

## Corneal Opacities

The PTK is an excellent treatment strategy for almost all corneal scars located within the anterior stroma ( $<150 \mu m$ ). I would like to emphasize three general considerations when treating corneal scars with the PTK:



(a) The ablation depth:

Corresponding to recommendations for refractive surgery procedures, in general, the ablation should be restricted to the following parameters/limits [11, 12]:

- Total ablation depth should be  $\leq 150$  microns,
- The remaining stromal thickness (RSB) should be  $\geq 300$  microns,
- The total ablation should be less than 30% of the central corneal thickness CCT.

The success or failure of a PTK is strongly correlated with the visual acuity of the patient after the treatment. Because the corneal surface irregularities increases with the ablation depth, an excessive ablation should be avoided. In our experience, if the ablation doesn't exceed 100 microns (i.e. 50 microns epithelium, 50 microns stromal ablation), a good glasses corrected visual acuity can be expected. If necessary and if the theoretically calculated RSB is thick enough, exceptions regarding the total ablation are possible up to 200  $\mu\text{m}$  if the patient is willing to wear hard contact lenses (or sclera contact lenses) and is informed about the procedure as a last resort before keratoplasty. Next to the risk of post-PTK ectasia due to biomechanical destabilization, the risk of haze increases with increasing ablation depth.

To ensure an effective but also tissue saving and therefore safe procedure, the PTK for corneal scars should be performed in a step-by-step procedure with slit-lamp-observation during each step.

The examination before the treatment will give you an estimation of the total ablation depth necessary to remove the sight-limiting opacity.

Because most of the opacities involve also the corneal epithelium, we start with an Excimer epithelium ablation of 50 microns (transepithelium PTK). Then we tend to ablate about 80% of the estimated total stromal ablation depth and do the first slit-lamp examination afterwards. In case of only minor remaining opacities, we used to go on in 10–15 micron – steps until either the opacity has been completely removed, or we reach the limits of the ablation depth (see above). Dependent on the ablation depth and the pathology of the corneal opacity, mitomycin-C 0.02% (MMC) should be administered intraoperatively with a soaked sponge for 15 up to 60 s (longer application time in corneal dystrophies, young patients and high ablation depth [10]). For high ablations always weight minor remaining opacities against further excessive ablation. Paracentral remaining opacities might only have a minor impact on visual acuity compared to increasing optical aberrations due to stromal thinning.

(b) The potential benefit:

During the pre-surgical assessment, it is crucial to estimate the potential benefit of the PTK: Is the scar limited to the anterior stroma or will even a maximum Excimer-ablation not be able to remove the visually relevant proportion of the opacification? As described above, an excessive ablation increases the risk of a sub-optimal visual quality/CL necessity or even post-treatment ectasia. If the scar is located only paracentrally, the main reason for the decreased visual acuity might be the irregular corneal surface, rather than the opacification itself. In uncertain cases, a contact lens trial should be performed to distinguish between both possibilities. In case of a distinct increase of the visual acuity during the CL-trial, rather a TBK, than a topographic neutral PTK should be performed.

(c) The underlying pathology

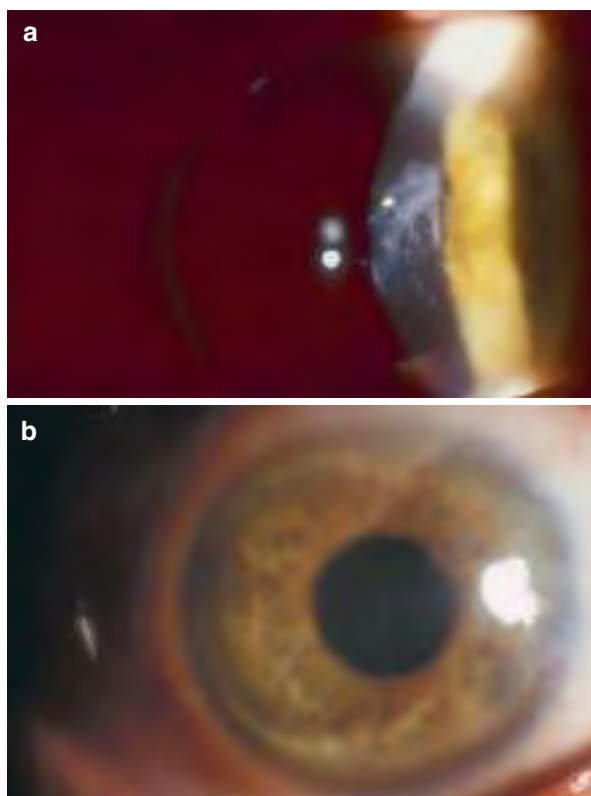
Despite the Excimer laser ablates all (organic) opacities without differentiating between pathologies, not all corneal opacities are alike regarding their requirements on the PTK strategy and their prognosis after the treatment.

### Posttraumatic Corneal Scar

Theoretically, the best assessable cause of a corneal opacity: a straightforward medical history (e.g. after trauma due to a splinter during drilling without protective glasses) and no risk of exacerbation or recurrence after the PTK. Still, as described above, a pre-surgical assessment is crucial to estimate the potential benefit and risk profile of the PTK. In case of hypertrophic corneal scars which surmount the epithelium-surface, an transepithelial PTK with masking substances should be performed (see Fig. 13.5 as an example).

### Rheumatoid Corneal Ulcers/Scars

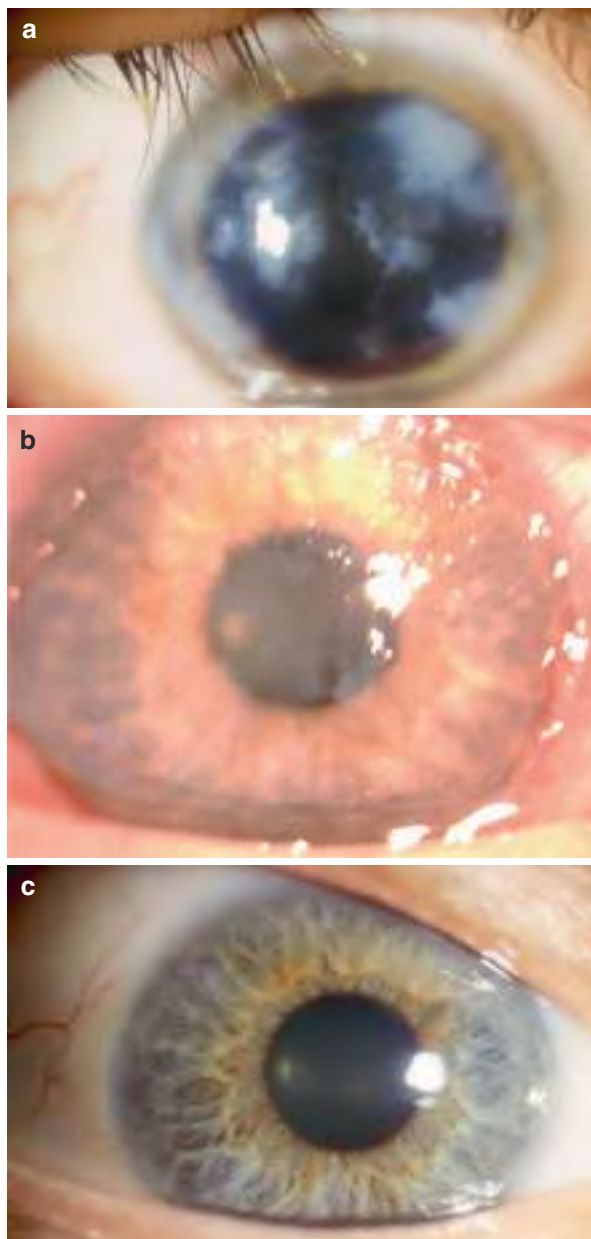
Because of the high risk of an exacerbation, PTK surgery is an absolute contraindication.



**Fig. 13.5** Hypertrophic corneal scar after lacerating trauma before (a) and 3 month after PTK and intraoperative applied MMC 0.02% (60 s) (b)

### Salzmann's Nodular Degeneration

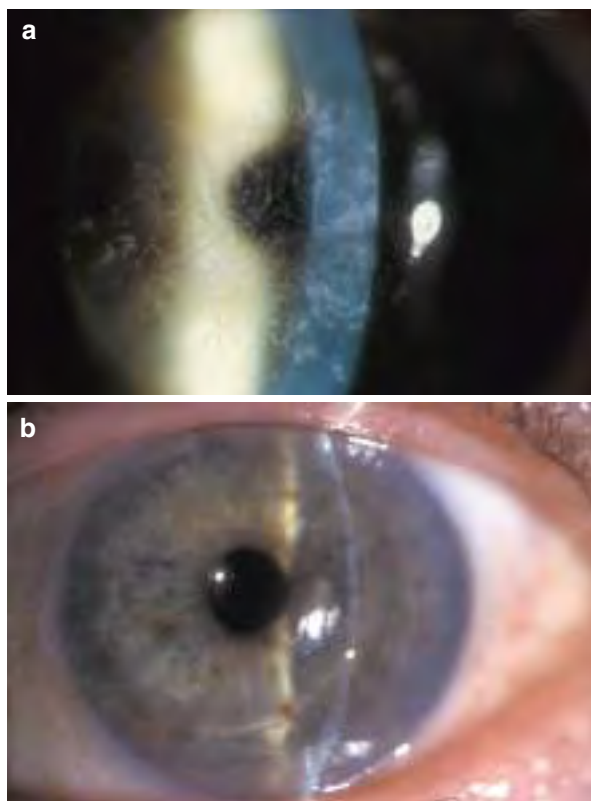
This degeneration can be excellently treated with a combination of a superficial mechanical keratectomy (hockey-knife) and the PTK. Thereby, the PTK ensures a homogenous and degeneration-free corneal surface. Combined with local intraoperative MMC application of 60 s, the treatment has a high safety and efficacy (see also Fig. 13.6) [10, 13].



**Fig. 13.6** Salzmann's nodular degeneration preoperatively (a), intraoperatively with residual irregularities (b) and 3 month after superficial keratectomy, PTK and intraoperative applied MMC 0.02% (60 s) (c)

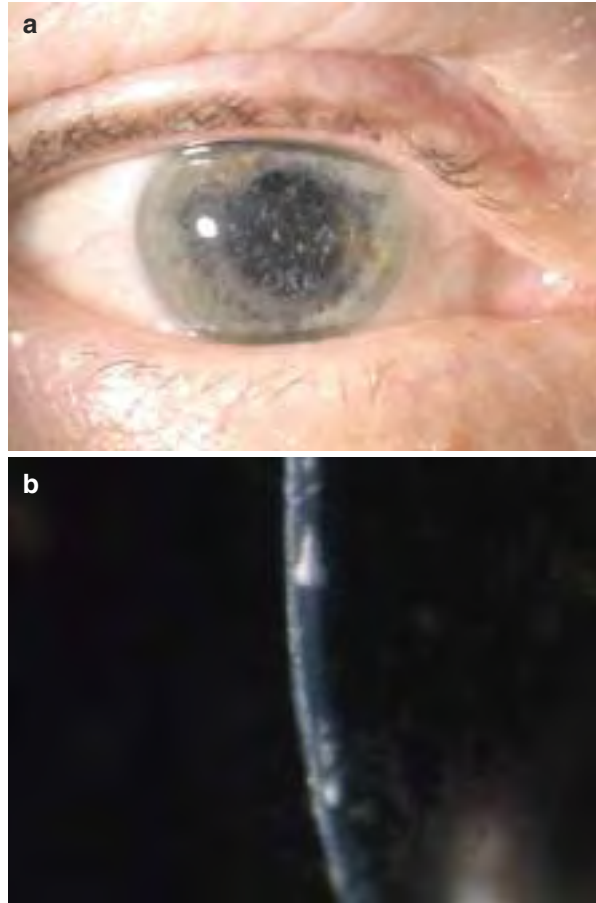
### Corneal Dystrophies with Opacities in the Anterior Stroma

In most corneal dystrophies, the PTK should be preferred to any kind of keratoplasty because the abandonment of a donor cornea, the untouched endothelium, the less invasive strategy, no suture related complications and the possibility of retreatment in case of recurrence. Above, the PTK can also be performed on a corneal graft if the underlying dystrophy recurs. When treating corneal dystrophies, the recurrence rates and their clinical picture are of special interest and should be considered before setting the time and ablation depth. For example the PTK in granular dystrophy shows good results and successful retreatment options, whereas macular and lattice corneal dystrophies demonstrate very high recurrence rates and partially signs of exacerbation (see also Fig. 13.7) [4, 14, 15]. Figure 13.8, as a counterexample to the cornea displayed in Fig. 13.7, displays the cornea of a patient with advanced granular dystrophy which is not sufficiently treatable with PTK because the granular opacities already expanded up to the posterior corneal stroma. Because of the importance and complexity of this topic, we recommend studying the cited surveys before performing PTK in patients with corneal dystrophies [4, 16–18].



**Fig. 13.7** Slit-lamp image of a recurrence of granular dystrophy on a corneal graft before (a) and 3 month after PTK and intraoperative applied MMC 0.02% (60 s) (b)

**Fig. 13.8** Slit-lamp image of an advanced granular dystrophy as an overview (a) and with a small slit to demonstrate the extend of the opacifications up to the posterior corneal stroma (b)



## Infectious Keratitis

### Acanthamoeba Keratitis

As always in Excimer-Laser-Treatment, the ablation depth defines the limits of success. If the amoebic cysts are within an acceptable depth (see above), the PTK is an excellent treatment option. However, because of the deep ablation necessary in most of the cases, the therapy should not be first line. The best results can be achieved after successful non-interventional medical treatment in a quiet and stable state. This way, the extension of the corneal opacifications can be reduced. In case of a resistance to local treatment with chlorhexidine or polyhexamethylene biguanide, the PTK can be a very efficient treatment option. One of the strongest benefits is, that the Excimerlaser not only ablates the clouded corneal tissue, but also directly removes the resistant amoebic cysts potentially leading to a better visual recovery [19, 20].

The same principles apply for bacterial and/or fungus-keratitis: Principally, the PTK is an effective treatment option to ,eradicate lesions, hasten reepithelialization, and restore and preserve useful visual function' [21].

However, despite of morphological good results in the literature, PTK is not a first-line therapy for treating acute infectious keratitis because of the implemented thinning of the cornea, the refractive shift, the risk of a progressing infection in a thinner cornea and a delayed wound healing. If possible, it is always more beneficial to treat the infection conservatively first, and then use the PTK to remove the remaining corneal opacities. The authors have no experience in performing PTK for acute infectious keratitis and recommend cross linking for severe cases of keratitis resistant to medical therapy.

### Corneal Scars After Herpes Keratitis

Excimer treatment for corneal scars after herpes keratitis involve the danger of delayed wound healing, recurrences and even exacerbation of the keratitis..On the other hand, in case of central corneal involving and sight limiting scars, the option of a PTK should not be discarded. Despite reduced literature reports, at least some case reports exist which could demonstrate the benefits of the PTK [22, 23]. Still, the surgeon (and the patient) has to be aware of the high risk of post-PTK complications mentioned above. The treatment should be seen as an option to avoid more aggressive corneal surgeries like a corneal transplantation, which also carries the same risks of post-surgical complications, but potentially with even more disastrous consequences like a triggered graft-rejection which might require high-risk secondary (or even tertiary) replacement of the donor-tissue. In any case of corneal surgery after herpes keratitis, systemic virostatic agents like acyclovir or valacyclovir should be administered and the patient should be closely followed after the treatment [24, 25]. In case of a delayed wound healing/epithelialization timely, therapeutic options like amniotic membrane transplantation should be considered without delay.

### PTK After Complications in Refractive Excimer Laser Surgery

The PTK is an important instrument for complication management in refractive surgery. In case of a decentered ablation or flap-related irregularities like button-holes or striae, special PTK strategies can be used to regularize the corneal surface. After successful PTK – treatment, if needed, a PRK can be conducted to improve residual refractive errors. Another important indication for the PTK is haze after surface ablation (SA). The PTK is very effective in removing the usually superficial but potentially severely sight-limiting opacification (Haze Fantes grade 3–4). To avoid an exacerbation/recurrence after the treatment, topical mitomycin C 0.02% should be applied intraoperatively for 45–60 seconds. MMC should not be as eye drop solutions for a prolonged time after corneal surgery because of the high risk of limbal stem-cell-deficiency and delayed epithelial recovery.

## Topography Based Keratectomy (TBK)

Toam R. Katz

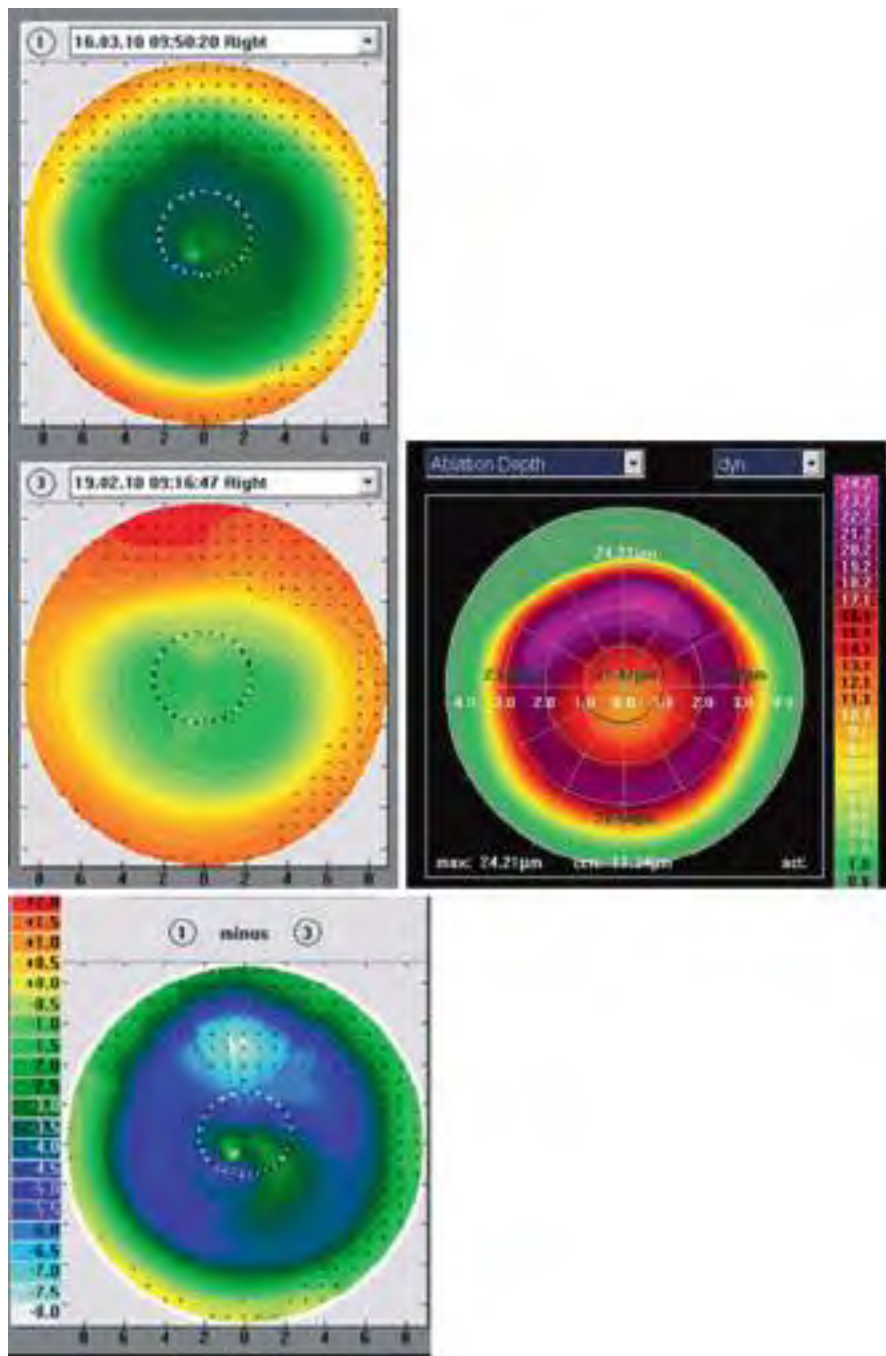
This book discussed Laser assisted keratectomy for refractive and therapeutic purposes and their possible complications. The laser refractive procedures such as LASIK, PRK or SMILE with their variations take refractive parameters of sphere, cylinder, axis, sometimes with added parameters of supposed (wavefront optimized) or measured (wavefront based) HOAs, and ablate the corneal surface into a desired sphero-cylindric ellipsoid while attempting to reduce the unavoidable induction of HOAs. Any complication of these procedures may be classified as causing distorted shape of the anterior cornea or as causing loss of transparency of the stromal tissue (or both).

Distorted shape of the anterior cornea, normally referred as irregular astigmatism, can not be corrected with sphero cylindrical visual aid or sphero cylindrical ablation, thus causes loss of DCVA and reduced visual quality. Reasons for irregular astigmatism are numerous, among which are corneal refractive laser complications (irregular flap, flap stria, DLK, epithelial ingrowth, severe dry eyes, haze, irregular/decentered ablation, post LASIK ectasia, corneal scar etc.) as well as other corneal pathologic deformations (Keratokonus, corneal scars, corneal dystrophies, post corneal transplantation, post radial keratotomy, keratitis etc.). Proper complication prevention and management and treatment of the corneal diseases may still end with a steady state irregular astigmatism, in which a cornea that may be optically clear, and the smoothing effect of the epithelium reaching its maximal potential, still have an irregular non-sphero-cylindrical surface. The topography based keratectomy (TBK) allows us to topographically measure the difference between the actual irregular astigmatism and the desired sphero-cylindrical shape, and to ablate and smooth down the irregularities in stromal level with the Excimer laser. Lately it has been suggested to perform TBK as a primary refractive surgery alternative to refraction based Excimer ablation. A recent FDA study [26] including 249 myopic eyes of 212 patients reported improvement of visual quality and stable results 1 year after TBK-LASIK.

### *Indication for Therapeutic TBK*

TBK is indicated for irregular corneal surface causing reduced visual acuity and quality. Common pathologies that may benefit from TBK are:

1. Healed irregular LASIK flap
2. Post irregular Excimer ablation such as too small optical zone (Fig. 13.9)
3. Stable keratoconus
4. Post corneal transplantation
5. Post corneal scars



**Fig. 13.9** Topography before (3) and after widening of a too small optical zone (1). The subtraction of the topographies (3 minus 1) shows the achieved change in topography. A Topolyser map of planned ablation depth may induce unwanted refraction that should be neutralized by including a compensating refractive ablation (Courtesy of Dr. A. Cummings)



Not every irregular cornea is a good candidate for TBK. Some corneas may accompany other eye pathologies that reduce vision. Even the meticulous analysis of the corneal topography can not predict the prognosis of TBK. The best prognostic tool is demonstrating the visual acuity and quality while smoothing down the irregularities. This may be done by fitting a hard contact lens and over refracting to get the best visual performances. This hard contact lens test (CLT) may be done in the office with difference base curves and over refraction and hopefully achieves very good DCVA, reduction of glare, halos, double vision and other photopic phenomena (positive CLT). A positive test allows the clinician to plan the next steps of TBK, motivates the patient to go through a series of treatments, and if tolerated for a long time offers an TBK-alternative of wearing hard contact lens permanently. A much coarser test to anticipate the prognosis of TBK is a pin-hole test.

A good candidate for TBK should fulfill these conditions:

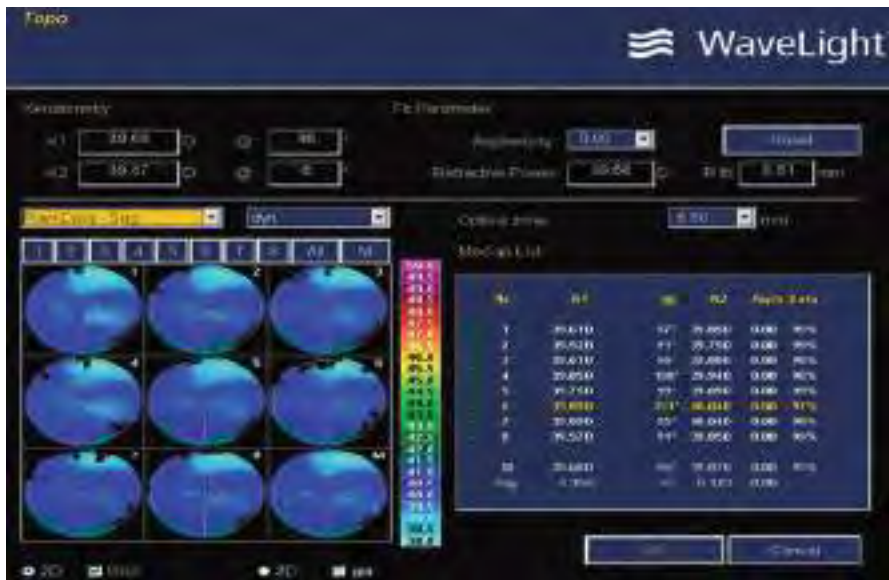1. Low DCVA and or low visual quality
2. Stable keratometry. A progressing ectasia is not a good candidate.
3. Clear media along the optical axis
4. Positive CLT
5. Corneal thickness allowing ablation, normally  $>400 \mu\text{m}$
6. Good quality and reproducible keratometric maps using the designated topographer

### ***Ablation Plan of TBK***

Different topographers, ablation softwares and flying spot Excimer lasers in the market can perform TBK. Among others are the Orbscan video-topographer with TOSCA software and Meditec MEL 70 Excimer, the Wavelight T-CAT ablation profile and others. Our experienced is based on the Topolyser topographer (Fig. 13.10) based on placid disc video-topography and the Oculyzer based on Scheimpflug imaging topography, T-CAT/Contura Vision software and Wavelight 400 and EX500 Excimer lasers from Alcon. The candidate corneas for therapeutic TBK usually show irregular astigmatism with resultant HOAs typically coma, trefoil and spherical aberrations. These corneas usually suffer of uneven tear film, scars and the patient with low visual quality may be unable to focus on the target image in the topographer. For this reason multiple scans (Fig. 13.11) of good quality are needed to produce an averaged reliable demonstration of the irregular surface. This surface is analyzed by the appropriate software into keratometry maps, heights maps, Zernike polynomials and inter-scans differences.

Theoretically the TBK ablates off the differences between the actual contours and the best fit spherocylindrical surface, so cleaning off the spherical aberrations (C12 in Zernike polynomials), and comas (C7, C8) without producing changes in sphere and cylinder (C4). In fact removing tissue to correct HOA does produce

**Fig. 13.10** Allegretto excimer laser and topolyzer (Courtesy Dr Katz, Care Vision)



**Fig. 13.11** Multiple topographic scans should be averaged into 1 reproducible and complete corneal map (Courtesy of Dr. A. Cummings)

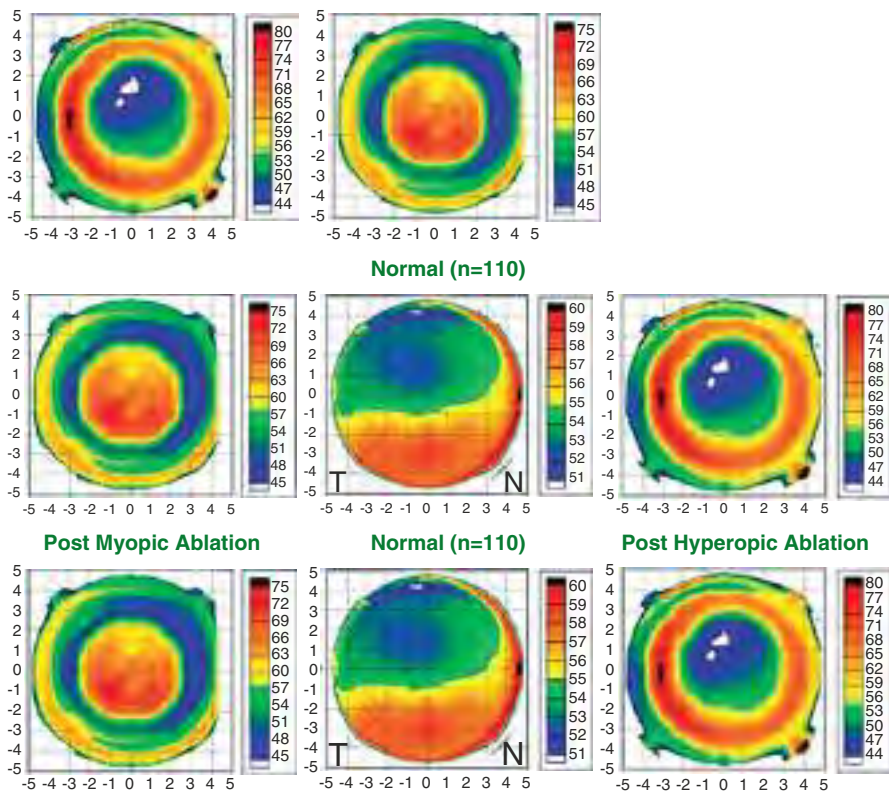
changes in sphere and cylinder. The surgeon should plan accordingly an additional spherocylindrical correction, either to compensate for the HOA correction or to intentionally correct the spherocylindrical refraction if desired. So far there is no published nomogram for all TBK platforms. The ablation plan is an art practiced by few surgeons and is still a trial and error process.

An irregular astigmatism is expected after non complicated penetrating keratoplasty, and unavoidable in spite of different suturing methods. In a study [27] comprising 16 eyes post keratoplasty were treated with PTK-TBK. The mean DCVA has improved from 0.23 to 0.45 after 12 months, with reduction of astigmatism but persistence of HOA.

### ***LASIK vs. SA TBK***

The TBK profile may be technically used with surface ablation, with flap creation or with lifting of an existing flap. TBK-SA with MMC is most widely used due to the following advantages: saving stromal tissue for future ablations, treating complicated flaps, avoiding epithelial ingrowth and ablating superficial scars. A TBK-LASIK has the LASIK known advantages as well as better congruity of the surface over-epithelium topography with the stromal ablation, easy of treatment with existing regular flap or after penetrating keratoplasty, and patients' acceptance when operating a refractive TBK. Epithelial thickness as measured by Reinstein et al. varies by more than 30 microns over normal corneas and varies even more after myopic or hyperopic LASIK (Fig. 13.12), in keratoconus and in other corneal surface irregularities [28]. The Epithelium has a smoothing effect on the corneal stromal surface, filling up holes and dents with thick epithelium, and becoming thinner above stromal peaks and conuses. This smoothing effect has double importance in TBK. On one hand the acquisition of the target topography for TBK is done on such epithelium, thus masking the true corneal stromal irregularity. LASIK-TBK is thus more accurate than PRK-TBK since we preserve the epithelial contour before and after TBK. On the other hand basing the TBK treatment on epithelial topography only partially corrects the stromal high peak in keratoconus or the decentered stromal ablation we wish to correct. The epithelial topography post TBK may continue to change unpredictably by smoothing a newly formed stromal surface.

The masking effect of the epithelium may be imaged and subtracted to demonstrate the "true" stromal irregularity. In a technique described by Reinstein et al. [29] for correcting irregular astigmatism after incomplete flap, the epithelial thickness profile was measured by high frequency ultrasound (Artemis) and was digitally subtracted from anterior corneal height map to create a stromal height map. A TBK-PTK based on the stromal map was performed. After 1 month the corneal asymmetry was reduced, the corneal curvature decreased by 4 diopters and the epithelial thickness was more regular with symptomatic improvement of night vision.



**Fig. 13.12** Epithelial thickness post hyperopic and myopic stromal ablations reduce the ablation effect

### ***TBK Combined with Cross Linking for Keratoconus***

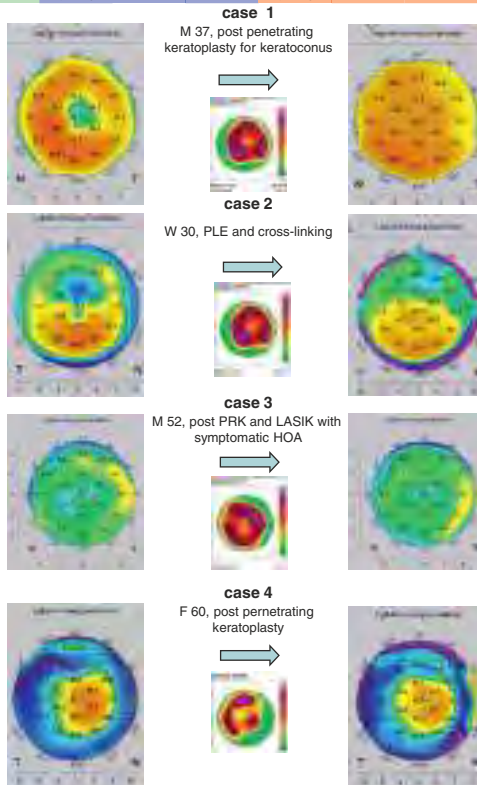
TBK is experimentally used by keratoconus eyes, combined with either 2-step or simultaneous cross-linking. The target is to change the irregular topography and improve the DCVA and contact lens tolerance but consume as less tissue as possible and avoid keratoconus progression. Because of the high variation there is no fixed nomogram. In a treatment per Athens protocol [30], Kanellopoulus has compared the efficacy and safety of TBK followed by cross linking in 325 keratokonus eyes, performed either in 6-month interval or as a single procedure. The TBK-PRK treatments were done with Topolyser and Wavelight Allegretto laser, aimed at eliminating the irregularity, and correcting up to 70% of the cylinder and sphere diopters over an optical zone of 5.5 mm, and up to 50 micron of stromal depth. Alcohol was used to remove epithelium and MMC to reduce haze. The cross linking was done with a standard Riboflavin 0.1% and 30 min of 3 mw/cm<sup>2</sup> UV radiation. After follow-up of 24–68 months. Both groups showed improvement in UCVA, DCVA, reduction of SE and mean keratometry, with advantage to the simultaneously treated eyes.

**TBK Examples (Fig. 13.13)**

The following 4 cases from our experience demonstrate the typical candidates for TBK and the resultant visual improvement. Typically the corneal asymmetry indices improve and the visual symptoms caused by the HOA improve. The refraction and UDVA can not be well predicted. Often we see reduction of astigmatism with increase in the average flattening (hyperopia) or steepening (myopia) of the visual

	case 1		case 2		case 3		case 4	
	Pre-Op	Post-OP	Pre-Op	Post-OP	Pre-Op	Post-OP	Pre-Op	Post-OP
UCVA	0.02	0.01	0.4	0.02	0.7	1	0.1	0.06
DCVA	0.02	0.01	0.7	0.9	0.8	1.25	0.2	0.4
Sphere	0.2	0.5	-1.5	-5.5	1.25	2	-0.5	-3.75
Cylinder	-8	-15	-3.75	-3.5	-0.75	-1.25	-2	-1
ISV	-2	-1.75	111	70	23	15	119	15
IHA	104	43	19.5	0.1	13.7	4.2	65.4	4.2
Visual quality	-	+	-	+	--	++	-	+

UCVA, DCVA in decimal scale  
 Sphere, Cylinder in Diopter  
 ISV: index of surface variance  
 IHA: index of height asymmetry



**Fig. 13.13** Examples refractions, visus, and assymetry indices (table above) and figures of topography before TBK (left), the TBK ablation profile (middle) and the topography after TBK (right) of 4 eyes with irregular corneas

axis. Additional regular Excimer ablations may be needed if the corneal transparency and thickness allow.

## **Summery**

TBK is a very useful tool in correcting irregular astigmatism caused by laser refractive surgery complications on the spot where the problem was first caused. This is the only precise tool which allows to save tissue while smoothing down the irregularities. Its uses and accuracy will be expanded with the development of epithelial thickness imaging and proved nomograms.

## **References**

### ***Phototherapeutic Keratectomy (PTK)***

1. Rapuano CJ. Phototherapeutic keratectomy: who are the best candidates and how do you treat them? *Curr Opin Ophthalmol.* 2010;21(4):280–2.
2. Kornmehl EW, Steinert RF, Puliafito CA. A comparative study of masking fluids for excimer laser phototherapeutic keratectomy. *Arch Ophthalmol.* 1991;109(6):860–3.
3. Zaidman GW, Hong A. Visual and refractive results of combined PTK/PRK in patients with corneal surface disease and refractive errors. *J Cataract Refract Surg.* 2006;32(6):958–61.
4. Orndahl MJ, Fagerholm PP. Treatment of corneal dystrophies with phototherapeutic keratectomy. *J Refract Surg.* 1998;14(2):129–35.
5. Orndahl MJ, Fagerholm PP. Phototherapeutic keratectomy for map-dot-fingerprint corneal dystrophy. *Cornea.* 1998;17(6):595–9.
6. Weiss JS, Moller HU, Aldave AJ, et al. IC3D classification of corneal dystrophies—edition 2. *Cornea.* 2015;34(2):117–59.
7. Reidy JJ, Paulus MP, Gona S. Recurrent erosions of the cornea: epidemiology and treatment. *Cornea.* 2000;19(6):767–71.
8. Vo RC, Chen JL, Sanchez PJ, et al. Long-term outcomes of epithelial debridement and diamond burr polishing for corneal epithelial irregularity and recurrent corneal erosion. *Cornea.* 2015;34(10):1259–65.
9. Wong VW, Chi SC, Lam DS. Diamond burr polishing for recurrent corneal erosions: results from a prospective randomized controlled trial. *Cornea.* 2009;28(2):152–6.
10. Linke SJ, Steinberg J, Katz T. Therapeutic excimer laser treatment of the cornea. *Klin Monbl Augenheilkd.* 2013;230(6):595–603.
11. Kohlhaas M. Iatrogenic keratectasia: a review. *Klin Monbl Augenheilkd.* 2015;232(6):765–72.
12. Randleman JB, Woodward M, Lynn MJ, Stulting RD. Risk assessment for ectasia after corneal refractive surgery. *Ophthalmology.* 2008;115(1):37–50.
13. Khairuddin R, Katz T, Baile RB, et al. Superficial keratectomy, PTK, and mitomycin C as a combined treatment option for Salzmann's nodular degeneration: a follow-up of eight eyes. *Graefes Arch Clin Exp Ophthalmol.* 2011;249(8):1211–5.
14. Das S, Langenbucher A, Seitz B. Excimer laser phototherapeutic keratectomy for granular and lattice corneal dystrophy: a comparative study. *J Refract Surg.* 2005;21(6):727–31.
15. Hafner A, Langenbucher A, Seitz B. Long-term results of phototherapeutic keratectomy with 193-nm excimer laser for macular corneal dystrophy. *Am J Ophthalmol.* 2005;140(3):392–6.

16. Dinh R, Rapuano CJ, Cohen EJ, Laibson PR. Recurrence of corneal dystrophy after excimer laser phototherapeutic keratectomy. *Ophthalmology*. 1999;106(8):1490–7.
17. Lisch W, Seitz B. New international classification of corneal dystrophies (CD). *Ophthalmologie*. 2011;108(9):883–96. quiz 97.
18. Seitz B, Lisch W. Stage-related therapy of corneal dystrophies. *Dev Ophthalmol*. 2011;48:116–53.
19. Kandori M, Inoue T, Shimabukuro M, et al. Four cases of Acanthamoeba keratitis treated with phototherapeutic keratectomy. *Cornea*. 2010;29(10):1199–202.
20. Taenaka N, Fukuda M, Hibino T, et al. Surgical therapies for Acanthamoeba keratitis by phototherapeutic keratectomy and deep lamellar keratoplasty. *Cornea*. 2007;26(7):876–9.
21. Li LM, Zhao LQ, Qu LH, Li P. Excimer laser phototherapeutic keratectomy for the „, treatment of clinically presumed fungal keratitis. *J Ophthalmol*. 2014;2014:963287.
22. Fagerholm P, Ohman L, Orndahl M. Phototherapeutic keratectomy in herpes simplex keratitis. Clinical results in 20 patients. *Acta Ophthalmol (Copenh)*. 1994;72(4):457–60.
23. Kaufman SC. Use of photorefractive keratectomy in a patient with a corneal scar secondary to herpes zoster ophthalmicus. *Ophthalmology*. 2008;115(2 Suppl):S33–4.
24. Asbell PA. Valacyclovir for the prevention of recurrent herpes simplex virus eye disease after excimer laser photokeratectomy. *Trans Am Ophthalmol Soc*. 2000;98:285–303.
25. Dhaliwal DK, Romanowski EG, Yates KA, et al. Valacyclovir inhibition of recovery of ocular herpes simplex virus type 1 after experimental reactivation by laser in situ keratomileusis. *J Cataract Refract Surg*. 2001;27(8):1288–93.

### ***Topography Based Keratectomy (TBK)***

26. Stulting RD, et al. Results of topography-guided laser in situ keratomileusis custom ablation treatment with a refractive excimer laser. *J Cataract Refract Surg*. 2016;42:11–8.
27. Hjortdal J, Ehlers N. Treatment of post-keratoplasty astigmatism by topography supported customized laser ablation. *Acta Ophthalmol Scand*. 2001;79:376–80.
28. Reinstein D, Yap TE, Archer TJ, Gobbe M, Ronald H, Silverman RH. Comparison of corneal epithelial thickness measurement between fourier-domain OCT and very high-frequency digital ultrasound. *J Refract Surg*. 2015;31(7):438–45.
29. Reinstein D, Gobbe M, Archer TJ, Youssefi G, Sutton H. Stromal surface topography guided custom ablation as a repair tool for corneal irregular astigmatism. *J Refract Surg*. 2015;31(1):54–9.
30. Kanellopoulos A. Comparison of sequential vs same-day simultaneous collagen cross-linking and topography-guided PRK for treatment of keratoconus. *J Refract Surg*. 2009;25:S812–8.

# Chapter 14

## Complications and Management in Laser Transplant Surgery

Berthold Seitz, Moatasem El-Husseiny, and Achim Langenbucher

### Specific Complications Using the Femtosecond Laser for Trephination Include

Today, the expectations with regard to the results after PKP are limited not only to the achievement of a clear graft. The only criterion that matters to the patient is good visual acuity, preferably without contact lenses, but with a well-tolerated pair of spectacles. Donor and recipient trephination should be performed with the same system from the epithelial side. The horizontal position of the limbus plane is essential. The graft size should be adapted individually to the cornea size (“as large as possible, as small as necessary”) and limbal centration preferred to pupil centration in cases of doubt (especially with keratoconus). Furthermore, excessive graft over- or undersizing should be avoided. At the end of the operation, adjustment of the continuous cross-stitch suture should be carried out using a Placido disk. Nonmechanical excimer laser trephination results in lower astigmatism, higher topographic regularity and better visual acuity (especially in younger patients with keratoconus). In the case of an unstable cornea (e.g. after RK, iatrogenic keratectasia after LASIK, pellucid marginal degeneration, descemetocoele, perforated ulcer), trephination with excimer laser is possible.

---

B. Seitz, ML, FEBO (✉) • M. El-Husseiny  
Department of Ophthalmology, Saarland University Medical Center UKS,  
Kirberger Straße 100, Homburg/Saar D-66424, Germany  
e-mail: [berthold.seitz@uks.eu](mailto:berthold.seitz@uks.eu); <http://www.unilasik-homburg.de>

A. Langenbucher, Dipl.-Ing.  
Department of Experimental Ophthalmology, Saarland University, Homburg/Saar, Germany



## ***Summary of How to Avoid Complications in Corneal Transplant Surgery***

Besides routine postoperative follow-up the prophylaxis of complications in penetrating keratoplasty (PKP) includes special preoperative and intraoperative aspects.

**Preoperative prophylaxis** consists of the therapy of systemic diseases and eyelid abnormalities, determining individual optimal graft size, avoiding PKP in cases of uncontrolled intraocular pressure, avoiding PKP in cases of acute corneal hydrops, pretreatment of vascularized cornea, amniotic membrane transplantation before PKP in cases of ulcerative keratitis, quality controlled organ-cultured transplants and preoperative counselling by the surgeon to ensure patient compliance.

**Intraoperative prophylaxis** consists of controlled arterial hypotension and complete relaxation during general anesthesia. Sixteen precautions for intraoperative prophylaxis of astigmatism include:

1. An attempt should be made to receive information about history of previous refractive surgery or keratoconus/high astigmatism of the donor. Ideally, donor topography/tomography should be determined preoperatively to allow for “harmonization” of donor and recipient topography/tomography [1].
2. *General anaesthesia* has clear safety advantages over local anaesthesia, especially in young keratoconus patients. The arterial blood pressure should be kept as low as possible when the eye is open (“*controlled arterial hypotension*” – “*as low as possible – as high as necessary*”) and Mivacurium as non-depolarizing muscle relaxant should be avoided to reduce “*Vis à tergo*”.
3. Donor and recipient trephination should be performed from the epithelial side with the same system, which is the prerequisite for congruent cut surfaces and angles in donor and recipient. For this purpose an artificial anterior chamber is used for donor trephination.
4. Typically, the *pupil is constricted with pilocarpine* in order to protect the lens of the phakic eye.
5. Paracentesis at the limbus is recommended before trephination.
6. Horizontal positioning of the head and limbal plane are indispensable for state-of-the-art PKP surgery in order to avoid decentration, vertical tilt, and horizontal torsion.
7. In aphakic vitrectomised eyes, the transconjunctival suturing (e.g. with 8–0 Vicryl sutures) of a Flieringa ring to stabilise the open globe is recommended [2].
8. Orientation structures in donor and host facilitate the correct placement of the first four or eight cardinal sutures to avoid horizontal torsion [3]. The correct position of the *second cardinal suture* is absolutely crucial for a correct graft alignment.
9. Since 1989 more than 4000 nonmechanical PKPs have been performed successfully with the Zeiss-Meditec MEL70® and, recently, with the Schwind Amaris® excimer laser in Erlangen and Homburg/Saar.

10. Graft size should be adjusted individually (“as large as possible, as small as necessary”).
11. Limbal centration should be preferred over pupil centration (especially in keratoconus).
12. Excessive graft over- or undersize should be avoided to prevent stretching or compression of peripheral donor tissue.
13. A peripheral iridotomy at 12 o’clock prevents pupillary block and, therefore, an acute glaucoma attack. In case of keratoconus after the administration of atropine, this may appear as a so-called Urrets-Zavalía syndrome with a persistent maximally dilated pupil due to an iris sphincter necrosis [4].
14. As long as Bowman’s layer is intact a double running cross-stitch suture (according to Hoffmann) is preferred since it results in higher topographic regularity, earlier visual rehabilitation, and less suture loosening requiring only rarely suture replacement.
15. All knots are buried in the stroma to avoid mechanical irritation and the attraction of neovascularisation. We aim to produce deep lamellar “pre-descemetal” stitches. Typically, the Descemet’s membrane should be pushed forwards as a triangle in front of the tip of the needle (“wave of Descemet’s”).
16. Intraoperative keratoscopy should be applied after removal of lid specula and fixation sutures [5–7].

## Introduction

Corneal transplantation is the oldest, most common and most successful transplantation in humans overall. In the USA approximately 45,000 keratoplasties are performed annually, with the equivalent figure being more than 6000 in Germany. In Homburg/Saar we performed 363 keratoplasties in 2015. In the year 2014, 50.7 % of all corneal transplants were of the posterior lamellar type, with only 3.9 % being anterior lamellar grafts (DALK) and 45.4 % still being carried out as penetrating keratoplasties (PKP). This survey is based on the German Keratoplasty Register, which has been maintained since 2002 by the DOG-Sektion Kornea.

With a better understanding of immunological transplant reactions and “secondary glaucomas” after PKP, the demands placed on microsurgeons with regard to corneal transplantation have increased. Today, a crystal-clear cornea after PKP with high and/or irregular astigmatism, especially in combination with high anisometropia, can no longer be considered successful in normal-risk keratoplasty.

With the increasing experience of the microsurgeon, the *technique of keratoplasty* goes far beyond the replacement of two collagen discs and is crucial for the functional postoperative outcome. General anaesthesia has safety advantages over local anaesthesia, especially in young keratoconus patients. The arterial blood pressure

should be kept as low as possible (“controlled arterial hypotension” with maximum relaxation) and the upper body should be positioned at an angle of 30° when the eye is open. In children, consideration should be given to the pre-operative intravenous administration of acetazolamid and mannitol. In every case the anaesthetist should have been trained in the specific aspects of penetrating keratoplasty *before* a large opening is made in the eye ball – especially in children [8].

Unfortunately, conventional mechanical trephination is always associated to some extent with the deformation of corneal tissue, including distortion of the cut edges, with irregular incision surfaces as a consequence of the axial and radial forces which are induced by the use of these trephines [6, 7]. The incision angles deviate from the perpendicular and are often incongruent in the donor and recipient, especially when the donor trephination is performed with a punch from the endothelial side [9–11]. The fitting of the donor tissue into an unstable recipient bed is sometimes very difficult to achieve in a perfectly symmetrical manner. After the suturing of incongruent cut edges and the resulting induction of a vertical tilt [12], the healing of the wound can result in pronounced distortion of the graft topography, especially after suture removal [13–16]. Moreover, the asymmetrical placement of the cardinal sutures can lead to the asymmetric distribution of donor tissue in the recipient bed, in particular if the second cardinal suture is not positioned exactly 180° opposite to the first cardinal suture (“horizontal torsion” [6]).

On principal, prevention of complications in keratoplasty can be divided up into immunological and optical [17]:

- Preoperative prevention of complications (incl. detailed patient counselling and adequate preoperative preparation/selection of donor tissue),
- **Prevention of intraoperative complications,**
- Prevention of early postoperative complications after keratoplasty and
- Prevention of late postoperative complications after keratoplasty.

The prophylaxis of complications includes a patient briefing before surgery by the microsurgeon. “Treat them and street them” is certainly not the motto to follow [17]! Briefing includes:

- the operative risk, including loss of the eye due to expulsive haemorrhage,
- the slow recovery of visual function over weeks and months,
- the possibility of immunological graft rejection, even after several years,
- the risk and symptoms of suture loosening,
- the risk of epithelial defects with a risk of infection,
- hypesthesia of the graft over several years.

Furthermore, the patient is instructed, that in case she/he experiences “red eye”, tears, pain or blurred vision, she/he should *immediately* seek medical attention. This personal briefing by the surgeon on the evening before surgery and also before demission contributes towards ensuring patient compliance and the long-term success of the operation! The following principle applies: “If you are in doubt, do not wait 3 days and hope for spontaneous improvement!”

**In this chapter especially the potential intraoperative complications of laser trephination for keratoplasty should be stressed. Laser trephination is in particular applied to reduce postoperative astigmatism and improve visual acuity after keratoplasty.**

## Causes of Astigmatism After Keratoplasty

Each individual step, from the selection of the donor, intraoperative trephination and the suture technique to the quality of the postoperative follow-up treatment, can be decisive not only for corneal transparency, but also for the final refractive outcome [18–20].

In addition to tissue-intrinsic factors in the donor and recipient, early astigmatism *with sutures in place* appears to depend strongly on the suture placement technique and the approaches used for intra- and postoperative suture adjustments (the “signature” of the microsurgeon) [6]. After suture removal the corneal curvature normally becomes more regular [22], although the “net astigmatism” can significantly increase [11, 14–16].

We have to distinguish between the **early postoperative astigmatism with sutures in place** and the **late persisting astigmatism after suture removal**. Concerning the *pathomechanism of the increase in astigmatism* after suture removal, the following suggestions are made: The low quality of the trephination wound and geometric incongruences (horizontal and vertical) require higher suture tension in order to guarantee a watertight wound closure and pseudo-optimal topography during the early post-operative phase. Asymmetrical regional forces between the donor and recipient can lead to inhomogeneous wound healing processes. The removal of the sutures results in the release of forces due to geometric incongruences and inhomogeneous wound healing. For this reason, horizontal, vertical and topographical discrepancies between the donor and recipient *intraoperatively* appear to be responsible for the increase in astigmatism *after* removal of the sutures. Thus, it is reasonable to conclude that in addition to wound healing, factors associated directly or indirectly with the quality of the wound geometry (quality of the incision, wound configuration (horizontal/vertical), symmetry of the graft fit) have a strong impact on long-term astigmatism *after removal of the sutures* [13, 21].

In principal, a “*perfect trephination*” requires [22, 23]:

- full visual control,
- no contact,
- optimal donor and recipient centration,
- identical shape of donor and recipient (typically circular round),
- congruent incision angles,
- 360° symmetrical donor-recipient alignment,
- Full depth trephination (no scissors required),

- no damage to intraocular structures (iris, lens),
- *in the future*: self-sealing donor-recipient apposition (“key-lock-principle”).

The main intraoperative determinants (Table 14.1, Fig. 14.1) for high and/or irregular astigmatism after suture removal are [6, 7, 22]:

- decentration (donor and/or recipient trephination)
- “vertical tilt” (incongruent cut angle between donor and recipient)
- “horizontal torsion” (horizontal discrepancy between the donor and recipient form and/or asymmetrical graft fit – “**The second cardinal suture is crucial!**”).

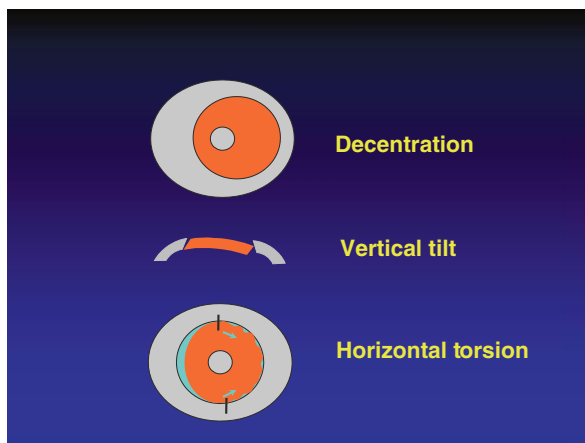
### *Individually Optimized Graft Size and Oversize*

As a matter of principle, graft size should be selected individually for each keratoplasty. The graft size is determined preoperatively for each individual, e.g. using a slit lamp with a measuring device. In a quantitative study we were able to show that the corneal diameter in keratoconus patients is significantly greater than in Fuchs

**Table 14.1** Intraoperative determinants of high and/or irregular astigmatism after penetrating keratoplasty [56]

Decentration of donor and/or recipient trephination
“Vertical tilt” due to incongruent wound configuration
Application of different trephines for the donor and recipient
Trephine tilt (i.e. not parallel to the optical axis)
Limbus level not supported horizontally
Slipping of the trephine in the stroma during the incision process
Intraocular pressure too high/too low
“Horizontal torsion”
Asymmetrical placement of the second cardinal suture (angle unequal 180°)
Incorrect fit of the donor and recipient due to incongruity
Focal overlap or dehiscence of the donor disc in the recipient bed
Excessively over/undersized donor disc
Distortion or compression of the cornea
Trauma to the cornea caused by instruments
Properties of the suture
Suture material
Suture technique (interrupted suture, single running suture, double running suture, combinations)
Length of the stitch
Depth of the stitch
Angle of the stitch to the donor-recipient junction
“Depth disparity”
Suture tension
Simultaneous intraocular surgery (e.g. triple procedure, artificial lens replacement, etc.)
Flieringa ring and lid speculum
Personal experience of the microsurgeon

**Fig. 14.1** Main reasons for high astigmatism after keratoplasty. (a) Decentration of the donor and/or recipient trephination, (b) “vertical tilt” due to uneven incision angle, (c) “horizontal torsion” due to asymmetrical suture placement



patients (mean horizontal diameter of 11.8 mm in keratoconus compared to 11.3 mm in patients with Fuchs dystrophy [24]). In general, larger graft dimensions have a favourable effect on the optical qualities, while a low rate of immunological rejection and lower risk of postoperative ocular hypertension is affected by a small graft. The graft size should be determined on an individual basis: **“as large as possible, but as small as necessary”**. In keratoconus, grafts of 8.0–8.5 mm are preferred, whereas in the case of Fuchs dystrophy with typically smaller and more elliptical corneal dimensions, a 7.5-mm-graft is often suitable if this eye is not eligible for DMEK or DSAEK [7, 21, 24].

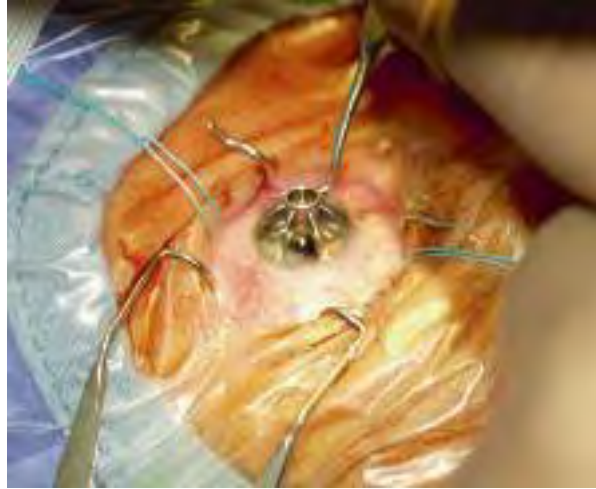In **repeat PKP** an attempt should be made to excise the previous graft completely and re-center the trephination if the cornea is large enough and a host rim of about 1.5 mm is left [26, 35]. This is especially of importance in eyes with high and/or irregular astigmatism as the reason for repeat grafting.

### *Pupil or Limbal Centration?*

Centration is essential, both in terms of the immunological graft reaction and the astigmatism after keratoplasty [19, 27, 28]. Typically, an attempt is made to reach a compromise between limbus and pupil centration in non-traumatized pupils. However, limbus centration is preferred especially in case of keratoconus, scars after trauma or irregular astigmatism due to other causes. In such eyes, the center of the entrance pupil is optically displaced from the position of the actual anatomical pupil due to asymmetrical refraction properties of the diseased cornea [29]. E.g., the pupil in the typical keratocoma eye tends to be optically displaced superonasally due to the inferotemporal location of the cone.

We use a radial keratotomy marker with eight lines in order to ensure limbal centration (Fig. 14.2). Additional central punctate marking can be helpful for certain trephine systems (e.g. Hessburg-Barron trephine, GTS after Krumeich).

**Fig. 14.2** Radial keratotomy marker for recipient centration with respect to the limbus



### *Suture Technique*

The type of trephination has a major impact on the correct placement of the first four or eight cardinal sutures [7]. The main purposes of these cardinal sutures include:

- The symmetrical horizontal distribution of donor tissue in the recipient bed
- Good adaptation of the donor to the recipient wound edge on the level of Bowman's layer
- Stabilization of the anterior chamber to ensure that further suturing is uniform.

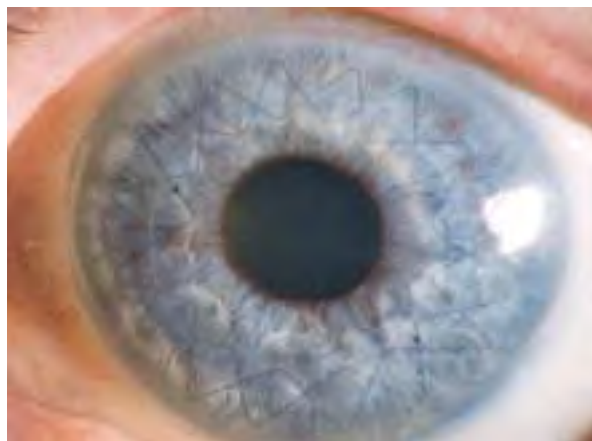Concerning donor-host-alignment, external steps must be avoided, although internal steps sometimes have to be tolerated in the case of thin recipient corneas, for example in pellucid marginal degeneration or herpetic scars (Fig. 14.3).

As far as the correct placement of the second cardinal suture is concerned, unintentional deviations from circular recipient openings can represent a challenge even for the experienced keratoplasty surgeon. After removal of the cardinal sutures, the quality of the trephination and the correct positioning of the graft are the main determinants for a watertight wound closure. With a better trephination, a lower final suture tension is necessary to avoid leakages after removal of the cardinal sutures. The lower the final suture tension is, the lower local mechanical distortions and the more quickly an improvement in visual acuity can be expected. In case of an intact Bowman's layer, a 16-stitch double-running diagonal cross-stitch suture (10-0 nylon) according to Hoffmann is typically preferred in Germany [30] (Fig. 14.4). The faster visual rehabilitation with running sutures – in contrast to multiple interrupted sutures and combined suture techniques – is attributable to the regular topography of the cornea and the avoidance of a relative cornea plana. In addition, with this double running suture the risk of suture loosening is reduced [31].



**Fig. 14.3** Anterior steps (+ step=donor too high, – step=donor too low) must be avoided during surgery when placing sutures. For peripheral stroma thinning due to underlying disease, posterior steps are often unavoidable in keratoconus or pellucid marginal degeneration (donor overrides host cornea into the anterior chamber)

**Fig. 14.4** Excimer laser keratoplasty (8.0/8.1 mm) with typical double-running 10–0 nylon cross-stitch suture, each with eight stitches [30] in keratoconus



## Excimer Laser Assisted Keratoplasty

With the assumption that the wound characteristics are considerably more important for the persistent astigmatism after suture removal and the optical quality of the graft than various suture techniques or methods of subsequent suture adjustments, the technique of nonmechanical corneal trephination has been developed and optimized in Erlangen since 1986 [32]. Originally, the elliptical shape was proposed on the basis of the idea that an elliptical graft could best be fitted to the natural elliptical outline of the human cornea, both from the optical and the immunological perspective [33, 34]. A total of 42 elliptical keratoplasties were performed in humans from 1989 to 1991 [35]. Subsequently, this method was abandoned for optical reasons, because the need for interrupted sutures to prevent rotation of the graft in the recipient bed and the need for asymmetric suture tension in these multiple interrupted sutures had ultimately not resulted in improved curvature, neither with nor without sutures [36]. Today, we still use elliptical excimer laser keratoplasty in case of elliptical ulcers with descemetoceles or penetration for the purposes of keratoplasty à chaud (a typical example of elliptical ulceration would be *Acanthamoeba keratitis*) [37].

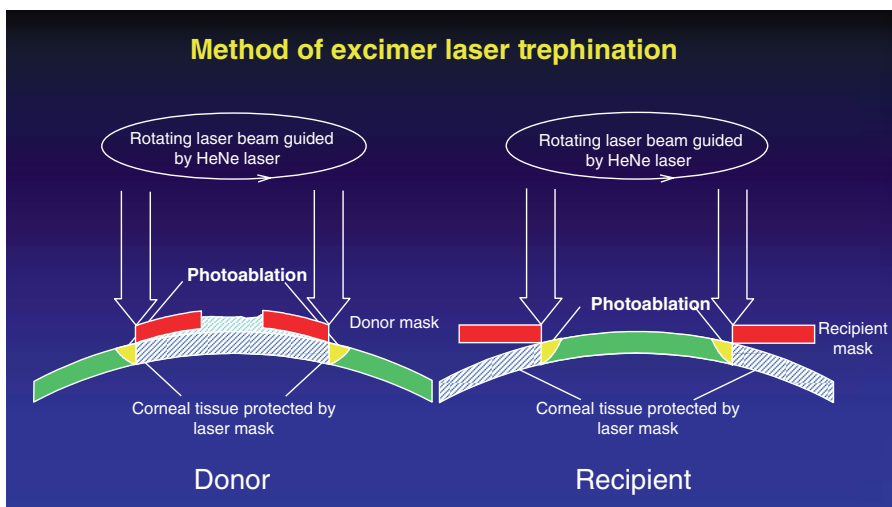


Since July 01, 1989 more than 4000 eyes have been successfully operated in Erlangen and Homburg/Saar with the MEL60/70 excimer laser made by Zeiss-Meditec (Fig. 14.5) and, recently, with the AMARIS excimer laser made by Schwind (Fig. 14.6).

**Technique** Before trephination, the limbus is centred along the vertical aiming beam in the donor and patient in order to ensure a reproducible position to the laser beam and therefore symmetric incision angles in the entire circumference. For *donor trephination* from the epithelial side, a round open metal mask (diameter 5.6–8.6 mm, central opening 3.0 mm for centring and visual control, thickness 0.5 mm, weight 0.2 g, 8 “orientation teeth”) is placed on a corneoscleral disc (16 mm) which is fixed in an artificial anterior chamber under microscopic control (Fig. 14.7a). The pressure within the artificial anterior chamber is adjusted to approximately 22 mmHg using Maklakoff tonometer [38].

For *recipient trephination* which is performed clinically with the manually or automated guided laser beam, a corresponding recipient mask is used (outer diameter 12.9 mm, central opening 5.5–8.5 mm, 8 “orientation notches”). The diameter of donor mask is selected to be consequently 0.1 mm larger compared to the recipient mask. Before the start of trephination, centration relative to the limbus is achieved through the association of the eight notches in the mask with the eight linear marks of a blue stained radial keratotomy marker which has been previously applied under microscopic control (Fig. 14.7b).

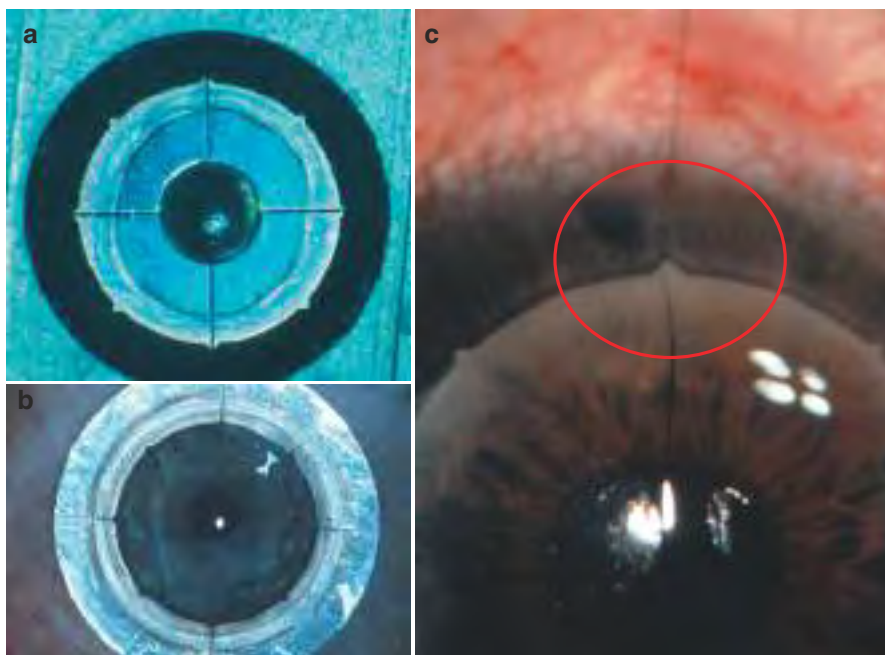
**Advantages of nonmechanical trephination** The main advantage of this excimer laser approach, which is performed from the epithelial side in donor and recipient, is the avoidance of mechanical distortions during trephination (Table 14.2). These



**Fig. 14.5** Principle of excimer laser trephination in the donor and recipient (schematic sketch, sagittal view)



**Fig. 14.6** Pseudo-ring-shaped automated Schwind AMARIS excimer laser ablation profile along the outer edge of a donor mask on a corneoscleral disc in an artificial anterior chamber



**Fig. 14.7** (a) Curved donor mask (8.1 mm in diameter) with eight “orientation teeth” on the outside, lying directly on the corneoscleral disc fixed in the artificial anterior chamber. The laser is guided along the outer edge. (b) Recipient mask (8.0 mm in diameter) with eight “orientation notches” on the inside lying directly on the patient cornea. The laser is guided along the inner edge. (c) Exact positioning of the second cardinal suture in penetrating excimer laser keratoplasty through the use of a small tooth and a corresponding notch to prevent “horizontal torsion” (intraoperatively)

results in smooth incision edges which are congruent in both the donor and recipient, so that the “vertical tilt” is reduced [12]. “Orientation teeth” on the edge of the graft [3] and corresponding notches in the edge of the recipient for predictable symmetrical positioning of the first eight cardinal sutures reduce the “horizontal torsion”

**Table 14.2** Advantages of nonmechanical trephination with the 193 nm excimer laser along metal masks with “orientation teeth/notches”

1. No trauma to intraocular tissues
2. Prevention of deformation and compression of the tissue during trephination
3. Reduction of “horizontal torsion” (“orientation teeth”)
4. Reduction of “vertical tilt” (almost perfect congruent incision edges)
5. Improvement of recipient and donor centration
6. Possibility of “harmonization” of donor and recipient topography
7. Reduction of anterior chamber inflammation after keratoplasty
8. <i>Reduction of astigmatism after suture removal</i>
9. Increase in the regularity of the topography of the cornea
10. <i>Significantly better spectacle-corrected visual acuity</i>
11. <i>Feasibility of trephination of an instable cornea</i> (e.g. “open eye”, descemetocoele, status post radial keratotomy, iatrogenic keratectasia after LASIK)
12. Arbitrary shape possible (e.g. elliptical)

(Fig. 14.7c). Furthermore, donor and recipient centration is improved [27, 28]. These beneficial influences on the main intraoperative determinants of astigmatism after keratoplasty (Table 14.1) result in lower keratometric astigmatism, higher topographic regularity and improved spectacle-corrected visual acuity after suture removal [39, 40].

In addition to less disruption to the blood-aqueous barrier in the early phase after keratoplasty [41], the laser trephination does not result either in increased cataract formation [42] or higher endothelial cell loss of the graft [43]. In addition, the frequencies of the immunological graft reaction [44] and secondary ocular hypertension were comparable in both techniques [45]. The use of metal masks allows an arbitrary trephination outline/shape [35, 36]. Moreover, the use of the laser allows trephination even in instable corneas, such as in a perforated corneal ulcers (or descemetocoeles) or after radial keratotomy or in iatrogenic keratectasia after laser in-situ keratomileusis LASIK [37, 46, 47].

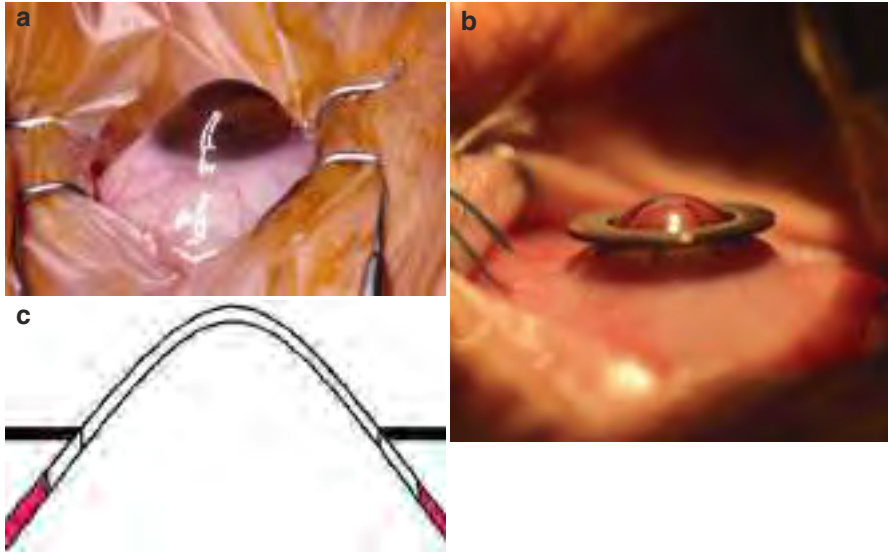
**Favourable practical considerations of excimer laser trephination for the microsurgeon** The somewhat longer trephination time (around 90 s with the Schwind laser) is largely compensated for by the practical advantages for the microsurgeon during the subsequent course of the surgery [6, 23, 32, 39, 40, 47]:

- Laser is not sensitive to the surgeon’s handwriting
- Laser application under direct visual control
- Laser-Eye-Tracking system feasible because of low repetition rate and comparatively large focus
- *Eye safe*, i.e. no threatening through laser beam, because UV-C light will not pass through the ocular media, but it will be absorbed in the superficial cornea
- Injury to intraocular structures is impossible with the laser, as tissue ablation ceases as soon as the aqueous humour fills the trephination groove after focal perforation.

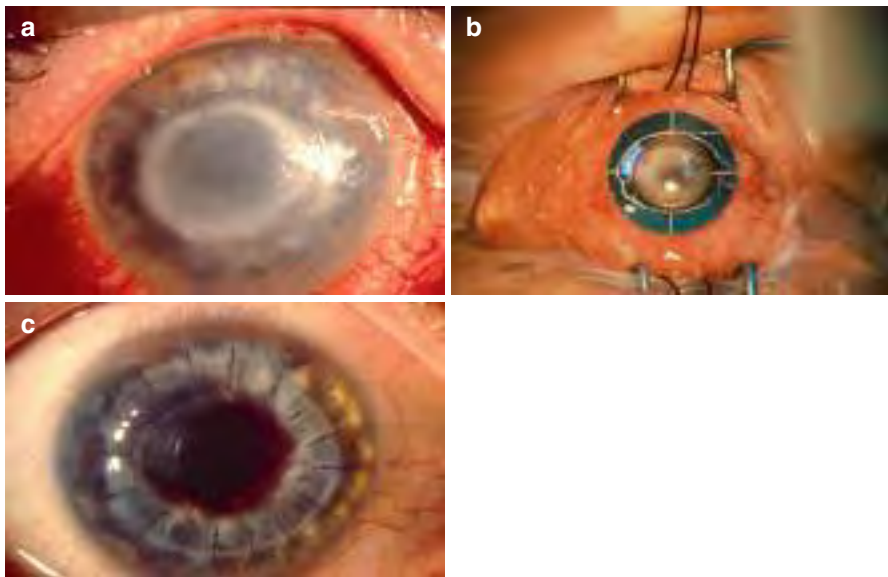
- The need to complete the cut using microscissors is reduced to a minimum.
- During trephination of a keratoconus cornea, the metal recipient mask (8.0 mm in diameter) is well centered around the cone without deformation. The laser is guided along the inner edge of the mask (Fig. 14.8).
- The location of the first eight cardinal sutures is unequivocally specified by the eight “orientation teeth/notches”.
- Crescent-shaped tissue deficits in the region of the donor-recipient junction (such as in the case of non-circular recipient openings e.g. in keratoconus) are avoided, so that a latent water-tight closure without major leakage is often achieved after just four cardinal sutures.
- During the subsequent suturing procedure, the anterior chamber remains largely stable as a rule.
- The final double-continuous suture only has to be tightened to a very slight extent in order to maintain an anterior-step-free wound adaptation without leakage – even after the removal of the eight cardinal sutures.
- For this reason, additional interrupted sutures with an unfavourable effect on the graft topography are needed only very rarely at the end of surgery.
- Furthermore, the so-called “barrel-top formation” at the proximal ends of the sutures, which result in a relative cornea plana and, therefore, delayed optical rehabilitation, is largely avoided.
- After removal of the eyelid speculum and the fixation sutures, the use of a Placido disc after intra-operative suture adjustment often provides circular mires.
- Non-vascularized scars and oedematous tissue in case of major endothelial decompensation is NOT a problem for excimer laser trephination – in contrast to FSL trephination
- Elliptical incisions feasible (e.g. in case of therapy-resistant Acanthamoeba keratitis) (Fig. 14.9).

### ***Specific Complications Using the Excimer Laser for Trephination***

- Incision only feasible by using masks to protect the underlying corneal tissue.
- In principal, the masks may show an incorrect geometry (i.e. may be produced not correctly by the manufacturer), e.g. the shape, size and the position of the “orientation teeth” at the donor mask may not match with the recipient mask.
- Even worse consequences may arise if accidentally not matching pairs of donor and recipient masks are used: if you e.g. put a 7.6 mm donor in an 8.0 mm host opening, increased suture tension will result in major cornea plana and irregular astigmatism. If you e.g. put an 8.1 mm donor in a 7.5 mm host opening, squeezing of superfluous tissue will result in an increased steepening of the graft with major induced myopic shift.
- Using the MEL70 laser, donor trephination took sometimes 4–5 min until perforation at one spot (Schwind Amaris trephination takes around 90 s).



**Fig. 14.8** (a) Side view of a very prominent keratoconus intraoperatively before trephination. (b) During host trephination with the excimer laser the metal recipient mask (8.0 mm in diameter) is well centred to the limbus and placed around the cone without deformation of the cornea. The laser is guided along the inner edge of the mask. (c) Schematic sagittal view of the cone protruding through the central hole of the metal recipient mask allowing a trephination without deformation



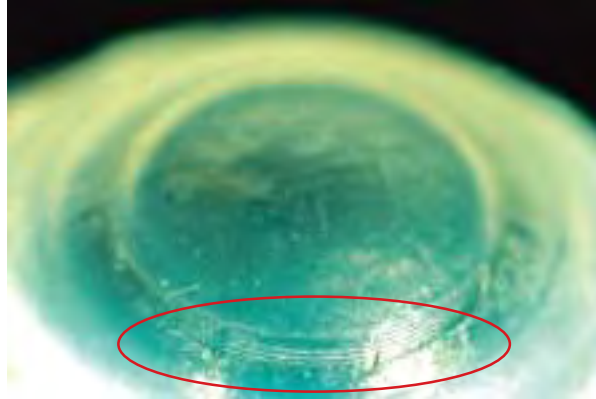
**Fig. 14.9** (a) Deep elliptical corneal ulcer in case of therapy-resistant *Acanthamoeba* keratitis. (b) Intraoperatively, for excimer laser assisted trephination an elliptical recipient mask is placed onto the cornea of the patient. (c) Final fixation of the graft in the host bed is achieved with multiple interrupted sutures

- Incomplete trephination of both the donor and recipient as a routine. Thus, deep stromal lamellae must be separated mechanically using microscissors.
- Experienced microsurgeon can use the laser created incision as a guide and finish the incision by microscissors in the given direction, However, posterior overriding stromal tissue shelves may induce a focal flat topographic irregularity due to compression of the superfluous tissue, thereby protruding the peripheral donor in the area of the deep stromal shelves.
- Thermal effects (“thermoring”) due to heating of the metal mask may appear in the center of the donor and the incision margin of the host. It may be prevented by using thicker and curved donor masks and putting viscoelastic in the central hole of the donor mask. Even the use of ceramic masks has been suggested but was not practically applied [48, 49].
- The mask may slide during laser action if the surface is not dried completely before putting the mask onto the cornea or if the mask is not laid down exactly horizontally (Fig. 14.10).
- Excimer laser action goes along with superficial ablation, no intrastromal incisions or 3D geometries feasible – no profiled incision!
- Tissue loss – therefore no possibility of suturing in the excised pathological patient cornea in case of inadvertent intraoperative donor loss.
- Too much viscoelastic in the anterior chamber during laser trephination will result in increased “Vis à tergo” after opening of the eye (“pressure” results in “counter-pressure”).
- Bleeding in case of vascularized patient cornea. In this case excimer laser trephination can be performed under full visual control until the “ablation groove” is filled with blood, then the mask is removed and the incision is finished manually with microscissors.
- Position of the paracentesis is always a compromise: too central means that the running suture may open it – too peripheral means that bleeding may occur even without corneal neovascularization. In excimer laser trephination, the mask must not be placed onto the cornea before the bleeding has stopped completely. Otherwise the ablation groove will fill with blood and the laser trephination will stop too early. Cold alpha-sympathicomimetic drops will help to contract the tiny vessel thus stopping the bleeding faster.

## **Excimer Laser-Assisted Deep Lamellar Keratoplasty (“Excimer DALK”)**

It is well-known that deep lamellar keratoplasty (DALK) only results in good visual acuity when the Descemet’s membrane was exposed intraoperatively [50, 51]. When the Descemet’s membrane is perforated, this usually results in a “conversion” to PKP. In order to ensure that the typically young keratoconus patient does not experience any disadvantages as a result of the planned DALK, we prepare the donor and recipient trephination with the excimer laser in the typical manner (see above). However, we do not perforate the patient’s cornea. If the “big

**Fig. 14.10** The mask may slide during laser action if the corneal surface and/or the mask are not dry before putting the mask onto the cornea or if the mask is not laid down exactly horizontally. The resulting step-shaped incision edge may resemble a “screw graft”



bubble” [52] is successfully achieved and we can bare Descemet’s membrane – without perforating – we terminate the operation as DALK. If this does not succeed to our satisfaction, the operation can be completed as excimer laser PKP with all of the advantages described above without any disadvantage for the patient. *Primum nil nocere* ....

## Femtosecond Laser Assisted Keratoplasty

The femtosecond laser (FSL) operates in the red or near infrared domain of the spectrum (wavelength of about 1  $\mu\text{m}$ ) in contrast to the excimer laser (193 nm UV). The cornea is transparent to the FSL. The excimer laser is absorbed by the cornea. The pulse duration of the excimer laser is a few nanoseconds (typically 20 ns), whereas that of the FSL is 50–200 femtoseconds. The repetition rate of the excimer laser today reaches up to 750 Hz, and in the FSL within the range of several kHz. The energy density of the excimer laser fluctuates between 150 and 400  $\text{mJ}/\text{cm}^2$ , and that of the FSL between 1 and 10  $\text{J}/\text{cm}^2$ . The spot size of the excimer laser varies between 0.6 and 6 mm, whereas in the FSL it is a few  $\mu\text{m}$ . The tissue interaction of the excimer laser is based on direct photoablation, while the tissue interaction of the FSL is plasma-mediated.

The principal advantages of the femtosecond laser use are that no masks are needed and that only minimal tissue loss or thermal effects occur. In contrast to the excimer laser, which only allows surface ablation, with the *femtosecond laser* (a femtosecond corresponds to  $10^{-15}$  s) intrastromal incisions in the cornea can be performed, so that actual three-dimensional profiles with or without opening the eye are feasible. With real 3-D sections it may be possible to achieve self-sealing wounds. We proposed the “inverse mushroom” (now commonly referred to as the “top hat” configuration) in 2005 in order to achieve self-sealing wound adaptation [53].

### ***The Fundamental Problem of Femtosecond Laser Trephination***

Over the last 10 years, femtosecond laser keratoplasty has caused a good deal of excitement reaching over to Europe from the USA. The advantages of femtosecond laser keratoplasty are combinations of arbitrary horizontal and vertical shapes, including the “top hat”, “mushroom”, “zigzag”, “Christmas tree”, “octagon”, “deca-gon”, “dovetail” etc. [54, 55]. The fundamental problem of femtosecond laser trephination is that immersion between an optical cone and the corneal shape is necessary and any disparity between the shape of a flat or even curved cone to the corneal shape induces mechanical stress and deformation. In advanced keratoconus in particular, this results in “non-circular” excisions in the patient’s cornea and, therefore, “horizontal torsion” as *the* main intra-operative determinant of high/irregular astigmatism after PKP [56].

In “regular trephination” during keratoplasty, maximum intraocular pressure values up to 135 mmHg are measured with the Intralase, 65 mmHg with the VisuMAX, 205 mmHg with the Femtec and 184 mmHg with the Femto LDV in experimental use [57]. Furthermore, in advanced keratoconus in particular, appa-nation will result in “non-circular” (often oval or pear-shaped) apertures in the patient’s cornea and therefore horizontal torsion as *the* main intra-operative deter-minant of high/irregular astigmatism after PKP [58]. The eight lines which are applied, for example for the Intralase femtosecond laser, in the donor and recipient can sometimes not be matched intraoperatively in the treatment of keratoconus (Fig. 14.11) [59].

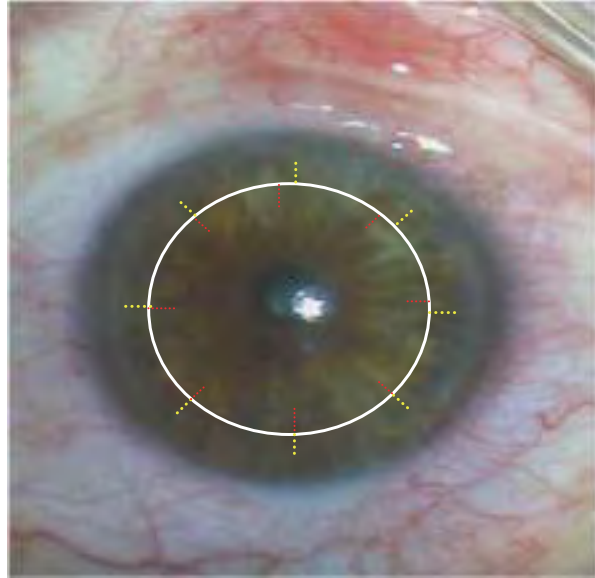
Some authors claimed that femtosecond laser PKP has advantages in the short-term follow-up concerning refractive cylinder and visual acuity [54, 60–62]. However, there is a large amount of missing data with respect to the potential advan-tages of femtosecond laser keratoplasty after complete suture removal. Only few researchers have published results pertaining to the situation after complete suture removal [63, 64]. After a mean follow-up of  $14 \pm 5$  months, the topographic astig-matism with all-sutures-out in the mushroom profile was  $6.4 \pm 3.0$  dpt, and in the top hat profile  $5.8 \pm 4.6$  dpt [63]. The degree of the astigmatism after femtosecond PKP is, therefore, comparable with that after motor trephination (now withdrawn from the market [39, 40]). Moreover, in the mushroom profile the rate of the post-operative immune reactions is significantly increased [65].

### ***Prospective Randomised Study Comparing Femtosecond Laser-Assisted and Excimer Laser-Assisted PKP***

FSL keratoplasty has been very interesting, but no prospective randomised study has so far been carried out in which both trephination procedures (FSL and excimer laser) for PKP in keratoconus and Fuchs dystrophy have been compared. Such a study has just been finished in Homburg/Saar [59].



**Fig. 14.11** In at least three positions, radial incisions in donor and recipient (for better visualization colored red in donor and yellow in recipient) after femtosecond laser trephination in keratoconus do not match. Ideally, these markers are supposed to indicate where the first eight cardinal sutures should be located



In all cases, we used energy of  $0.1 \mu\text{J}$  less than the maximum energy in the posterior side cut,  $0.5 \mu\text{J}$  less than the maximum energy in the anterior side cut, and  $0.4 \mu\text{J}$  less than the maximum energy in the ring lamellar cut ( $2.3\text{--}2.9 \mu\text{J}$ ). The eight alignment incisions in both the donor and recipient were created as follows: energy of  $1.5 \mu\text{J}$ , length of  $1000 \mu\text{m}$ , width of  $50 \mu\text{m}$ , spot separation of  $6 \mu\text{m}$ , line separation of  $6 \mu\text{m}$ , and layer separation of  $5 \mu\text{m}$ . The radial offsets were  $+2$  in all recipients (meaning that all the alignment incisions were outside the trephination) and  $-2$  in all donors (meaning that all the alignment incisions were inside the trephination). On the anterior side cuts, the spot separation and the layer separation were  $3 \mu\text{m}$ ; in the ring lamellar cut (spiral pattern), the tangential spot separation was  $5 \mu\text{m}$  and the radial spot separation was  $4 \mu\text{m}$ ; on the posterior side cut, the spot separation was  $3 \mu\text{m}$  and the layer separation was  $2 \mu\text{m}$ . The depth of the lamellar cut of the donor and recipient was  $2/3$  of the mean corneal thickness at the  $7.5\text{--}8.5 \text{ mm}$  optic zone of the graft (measured intraoperatively by an ultrasound pachymetry) and recipient's eye (measured preoperatively by anterior segment OCT), respectively. All diameters (anterior side cut, lamellar cut, and posterior side cut) were performed,  $0.1 \text{ mm}$  larger than the resulting diameter, thus overlapping each other. The donor cornea was placed into an artificial anterior chamber type Barron (Katena, Denville, USA) to achieve trephination from the epithelial side. Each laser procedure requires a disposable glass interface for immersion, which applanates the cornea completely during the laser procedure.

For laser trephination of the recipient's cornea, the eye was fixated by means of a vacuum suction ring. The glass cone interface was placed within the suction ring so that the cornea was completely applanated. We performed a complete penetrating laser trephination after which the corneal button was removed with forceps and a

spatula under microscopic control. If necessary, a microscissors was used to complete the incision. The top hat profile was used in Fuchs dystrophy, whereas the mushroom profile was used in keratoconus patients.

On principle, the **minimal requirements for comparative studies on various trephination techniques in PKP** are (in each case before **and after suture removal**) [21]:

- visual acuity with spectacle correction (not contact lens acuity!) and central refracting power,
- keratometric or topographic astigmatism (not only refractive manifest cylinder!),
- measure of the topographic regularity (e.g. SRI (surface regularity index) or SAI (surface asymmetry index) of the TMS system and ISV (index of surface variance) or IVA (index of vertical asymmetry) of the Pentacam),
- Endothelium (quantitative & qualitative)
- Immune reaction (type & frequency)

**Preliminary results** With FSL-PKP in keratoconus using a double running suture, we found more decentration, more Vis à tergo, and more often the need for additional single sutures to achieve donor-host apposition without steps and gaps [59]. After suture removal, topographic astigmatism after FSL trephination in keratoconus ( $6.8 \pm 3.1$  D) was significantly larger than after excimer laser trephination ( $3.3 \pm 2.2$  D). In addition, the surface regularity index (SRI) of the TMS-5 system in keratoconus was significantly unfavorable after FSL trephination ( $0.8 \pm 0.3$ ) than after excimer laser trephination ( $0.5 \pm 0.4$ ). Best spectacle corrected visual acuity after suture removal in keratoconus was  $0.8 \pm 0.2$  after excimer laser and  $0.7 \pm 0.2$  after FSL laser trephination [unpublished data].

Certainly “manifest cylinder” is not appropriate to compare the outcome of different trephination procedures for PKP [62]. In case of a highly irregular surface the portion of corneal astigmatism tolerated as manifest refractive cylinder in the refractive correction is severely decreased (and may be even zero) [21]. True benefits of excimer laser versus femtosecond laser trephination for PKP are summarized in Table 14.3.

### ***Favourable Practical Considerations of Femtosecond Laser Trephination for the Microsurgeon***

- Laser action starts in the anterior chamber because gas bubbles are obscuring the area behind laser action
- Profiled incision feasible
- Theoretically good match of donor and recipient due to profiled incisions (Fig. 14.12)
- Potential of “no-stitch” keratoplasty?
- No tissue loss – therefore the excised pathological patient cornea can be temporarily re-sutured into the host opening in case of inadvertent intraoperative donor loss

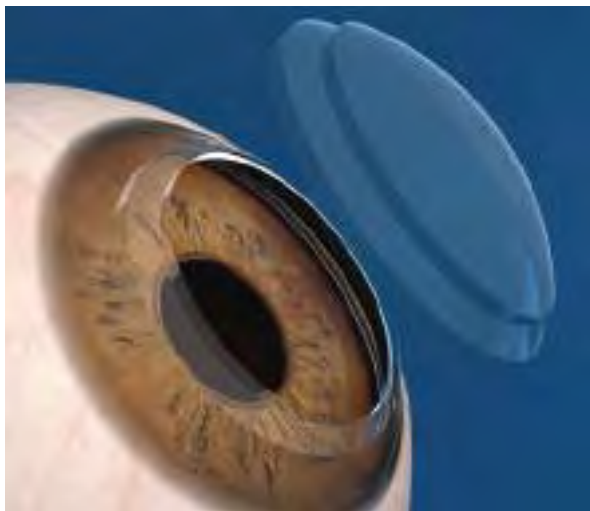
**Table 14.3** True benefits comparing excimer laser (EXL) versus femtosecond laser (FSL) trephination – practical considerations (+++= very favorable, --- = very unfavorable)

	EXL	FSL
“Cumbersome procedure”	+	--
Tissue loss	---	+++
Centration	+++	+
Avoid deformation and compression of tissue during trephination	+++	---
High IOP during laser action	+++	-
Minimizing amount of completion of incision by scissors	(+)	++
Location of first 8 cardinal sutures unequivocally given	+++	+
Stable anterior chamber during suturing	++	+++
Feasibility of double running suture	+++	+++
No need for additional single sutures	+++	+
Feasibility of trephination with instable cornea	+++	---
Feasibility of trephination in repeat keratoplasty	+++	-
Helpful for DALK	++	++
Potential for DSAEK ( <u>donor</u> / recipient)	---	+
(BUT: “suboptimal” stromal surface quality!)		
<b>Immune reactions</b>	+	--

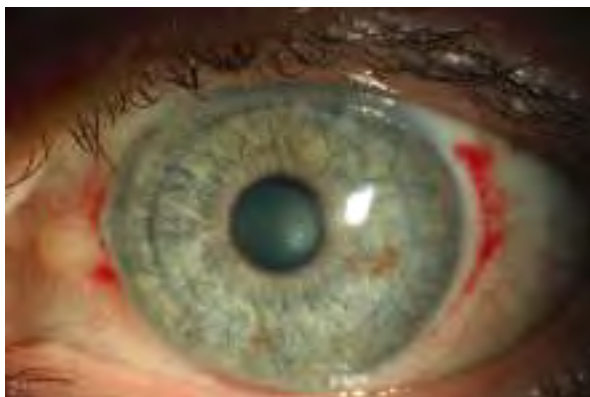## Specific Complications Using the Femtosecond Laser for Trephination

- Laser application without direct visual control of the operation area.
- Stop of power supply will stop procedure, incision has to be finished manually with microscissors.
- Hypophagma due to suction – lasting for about 10 days (Fig. 14.13).
- Centration is difficult – especially in advanced keratoconus.
- High intraocular pressure due to suction – risk of retinal artery occlusion [57]
- Scars will impair incision, manual completion with spatula or even with scissors necessary
- Difficult trephination and false lamellar cut depth in edematous corneas
- Laser-Eye-Tracking system not feasible because of very high repetition rate and comparatively tiny laser focus.
- Not *eye safe*, because visible or near-IR laser must produce plasma via non-linear processes, otherwise potential deposition of laser energy on the retina.
- Deformation of the cornea during suction and appplanation (recipient) resulting in distortion of the trephination outline (e.g. oval or pear shaped) and incongruent host incisions – FSL trephination not reasonable for pathological curvatures of the cornea.
- Ever after maximal suture adjustments, Placido disk application at the end of surgery often will still give you elliptical or even irregular projections on the graft after FSL trephination in keratoconus – due to geometrical mismatch ...

**Fig. 14.12** Excellent fit of donor in the host bed after femtosecond laser trephination in theory: “Inverse Mushroom Graft” = “Top Hat Graft”



**Fig. 14.13** Hyposphagma after application of a suction ring during patient trephination using the femtosecond laser



- High and irregular astigmatism after suture removal – especially in advanced keratoconus.
- Problem of achieving the correct plane of the side cut in tophat or mushroom configurations, e.g. if an edematous donor has to be prepared for a thinned keratoconus cornea. Thickness measurement before trephination in donor using multiple ultrasound measurements on the corneoscleral disk in the artificial anterior chamber (Domilens), in the recipient using the AS-OCT thickness profile. Always is some extent of fudging required ...
- Epithelial down-growth and accumulation of debris under the thin peripheral lamellar rim in mushroom configuration.
- Often Femtosecond laser is not placed in the sterile Operating Room. Therefore, either tissue bridges have been intentionally left in place or even situative single sutures are placed after laser action to avoid expulsive hemorrhage during

transportation from the laser suite to the OR – e.g. in a different floor – or even through the city.

- Very bad surface quality in case of producing the DSAEK posterior lamellar grafts with the femtosecond laser – and not with an automated microkeratome.

## Summary of How to Avoid Complications in Corneal Transplant Surgery

Besides routine postoperative follow-up the prophylaxis of complications in penetrating keratoplasty (PKP) includes special preoperative and intraoperative aspects.

**Preoperative prophylaxis** consists of the therapy of systemic diseases and eyelid abnormalities, determining individual optimal graft size, avoiding PKP in cases of uncontrolled intraocular pressure, avoiding PKP in cases of acute corneal hydrops, pretreatment of vascularized cornea, amniotic membrane transplantation before PKP in cases of ulcerative keratitis, quality controlled organ-cultured transplants and preoperative counselling by the surgeon to ensure patient compliance.

**Intraoperative prophylaxis** consists of controlled arterial hypotension and complete relaxation during general anesthesia. Sixteen precautions for intraoperative prophylaxis of astigmatism include:

1. An attempt should be made to receive information about history of previous refractive surgery or keratoconus/high astigmatism of the donor. Ideally, donor topography/tomography should be determined preoperatively to allow for “harmonization” of donor and recipient topography/tomography [1].
2. *General anaesthesia* has clear safety advantages over local anaesthesia, especially in young keratoconus patients. The arterial blood pressure should be kept as low as possible when the eye is open (“*controlled arterial hypotension*” – “*as low as possible – as high as necessary*”) and Mivacurium as non-depolarizing muscle relaxant should be avoided to reduce “*Vis à tergo*”.
3. Donor and recipient trephination should be performed from the epithelial side with the same system, which is the prerequisite for congruent cut surfaces and angles in donor and recipient. For this purpose an artificial anterior chamber is used for donor trephination.
4. Typically, the *pupil is constricted with pilocarpine* in order to protect the lens of the phakic eye.
5. Paracentesis at the limbus is recommended before trephination.
6. Horizontal positioning of the head and limbal plane are indispensable for state-of-the-art PKP surgery in order to avoid decentration, vertical tilt, and horizontal torsion.
7. In aphakic vitrectomised eyes, the transconjunctival suturing (e.g. with 8–0 Vicryl sutures) of a Flieringa ring to stabilise the open globe is recommended [2].
8. Orientation structures in donor and host facilitate the correct placement of the first four or eight cardinal sutures to avoid horizontal torsion [3]. The correct

position of the *second cardinal suture* is absolutely crucial for a correct graft alignment.

9. Since 1989 more than 4000 nonmechanical PKPs have been performed successfully with the Zeiss-Meditec MEL70® and, recently, with the Schwind Amaris® excimer laser in Erlangen and Homburg/Saar.
10. Graft size should be adjusted individually (“as large as possible, as small as necessary”).
11. Limbal centration should be preferred over pupil centration (especially in keratoconus).
12. Excessive graft over- or undersize should be avoided to prevent stretching or compression of peripheral donor tissue.
13. A peripheral iridotomy at 12 o’clock prevents pupillary block and, therefore, an acute glaucoma attack. In case of keratoconus after the administration of atropine, this may appear as a so-called Urrets-Zavalía syndrome with a persistent maximally dilated pupil due to an iris sphincter necrosis [4].
14. As long as Bowman’s layer is intact a double running cross-stitch suture (according to Hoffmann) is preferred since it results in higher topographic regularity, earlier visual rehabilitation, and less suture loosening requiring only rarely suture replacement.
15. All knots are buried in the stroma to avoid mechanical irritation and the attraction of neovascularisation. We aim to produce deep lamellar “pre-descemetal” stitches. Typically, the Descemet’s membrane should be pushed forwards as a triangle in front of the tip of the needle (“wave of Descemet’s”).
16. Intraoperative keratoscopy should be applied after removal of lid specula and fixation sutures [5–7].

## Conclusions

Today, the expectations with regard to the results after PKP are limited not only to the achievement of a clear graft. The only criterion that matters to the patient is good visual acuity, preferably without contact lenses, but with a well-tolerated pair of spectacles. Donor and recipient trephination should be performed with the same system from the epithelial side. The horizontal position of the limbus plane is essential. The graft size should be adapted individually to the cornea size (“as large as possible, as small as necessary”) and limbal centration preferred to pupil centration in cases of doubt (especially with keratoconus). Furthermore, excessive graft over- or undersizing should be avoided. At the end of the operation, adjustment of the continuous cross-stitch suture should be carried out using a Placido disk. Nonmechanical excimer laser trephination results in lower astigmatism, higher topographic regularity and better visual acuity (especially in younger patients with keratoconus). In the case of an unstable cornea (e.g. after RK, iatrogenic keratectasia after LASIK, pellucid marginal degeneration, descemetocoele, perforated ulcer), trephination with excimer laser is possible. New “key-lock” variants for the possible

self-sealing fit of the donor disc in the recipient bed were looming on the horizon 10 years ago (future “no-stitch keratoplasty”) after introduction of femtosecond laser application. However, recent [all-suture-out data](#) demonstrate that the potential superiority of this high price and difficult to maintain option cannot be proven! Thus, today the femtosecond laser application for PKP must be called “**the excitement of yesterday**”.

## Bibliography

1. Janunts E, Langenbacher A, Seitz B. In vitro corneal tomography of donor corneas using anterior segment OCT. *Cornea*. 2016;35(5):647–53.
2. Ninios K, Matoula P, Szentmáry N, et al. Results of excimer laser penetrating keratoplasty in aphakic eyes. *Graefes Arch Clin Exp Ophthalmol*. 2013;251:1185–9.
3. Behrens A, Seitz B, Kühle M, et al. “Orientation teeth” in nonmechanical laser corneal trephination: 2.94-microm Er:YAG laser vs. 193-nm ArF excimer laser. *Br J Ophthalmol*. 1999;83:1008–12.
4. Urrets-Zavalía A. Fixed dilated pupil, iris atrophy and secondary glaucoma. A distinct clinical entity following penetrating keratoplasty for keratoconus. *Am J Ophthalmol*. 1963;56:257–65.
5. Belmont SC, Troutman RC, Buzard KA. Control of astigmatism aided by intraoperative keratometry. *Cornea*. 1993;12:397–400.
6. Naumann GOH. Part II: corneal transplantation in anterior segment diseases. The Bowman Lecture (Number 56) 1994. *Eye*. 1995;9:395–421.
7. Seitz B, Langenbacher A, Naumann GOH. Trephination in penetrating keratoplasty. In: Reinhard T, Larkin F, editors. *Essentials in ophthalmology – corneal and external eye disease*. Berlin: Springer; 2006. p. 123–52.
8. Seitz B, Hager T, Szentmáry N, Langenbacher A, Naumann GOH. [Keratoplasty in children – still a dilemma]. *Klin Monatsbl Augenheilkd*. 2013;230:587–94.
9. Cohen KL, Holman RE, Tripoli NK, Kupper LL. Effect of trephine tilt on corneal button dimensions. *Am J Ophthalmol*. 1986;101:722–5.
10. Javadi MA, Mohammadi MJ, Mirdehghan SA, Sajjadi SH. A comparison between donor-recipient corneal size and its effect on the ultimate refractive error induced in keratoconus. *Cornea*. 1993;12:401–5.
11. Perl T, Charlton KH, Binder PS. Disparate diameter grafting. Astigmatism, intraocular pressure and visual acuity. *Ophthalmology*. 1981;88:774–80.
12. Langenbacher A, Seitz B, Kus MM, Naumann GOH. [Transplant vertical tilt after perforating keratoplasty – comparison between non-mechanical trephination with excimer laser and motor trephination]. *Klin Monatsbl Augenheilkd*. 1998;212:129140.
13. Cohen KL, Tripoli NK, Pellom AC, et al. Effect of tissue fit on corneal shape after transplantation. *Invest Ophthalmol Vis Sci*. 1984;25:1226–31.
14. Filatov V, Alexandrakis G, Talamo JH, Steinert RF. Comparison of suture-in and suture-out postkeratoplasty astigmatism with single running suture or combined running and interrupted sutures. *Am J Ophthalmol*. 1996;122:696–700.
15. Mader TH, Yuan R, Lynn MJ, et al. Change in keratometric astigmatism after suture removal more than one year after penetrating keratoplasty. *Ophthalmology*. 1993;100:119–27.
16. Musch DC, Meyer RF, Sugar A. The effect of removing running sutures on astigmatism after penetrating keratoplasty. *Arch Ophthalmol*. 1988;106:488–92.
17. Seitz B, El-Husseiny M, Langenbacher A, Szentmáry N. [Prophylaxis and management of complications in penetrating keratoplasty]. *Ophthalmologe*. 2013;110:605–13.

18. Hoppenreijns VPT, Van Rij G, Beekhuis WH, Rijnveld WJ, Rinkel-Van Driel E. Causes of high astigmatism after penetrating keratoplasty. *Doc Ophthalmol*. 1993;85:21–34.
19. Van Rij G, Cornell FM, Waring III GO, Wilson LA, Beekhuis H. Postoperative astigmatism after central vs eccentric penetrating keratoplasties. *Am J Ophthalmol*. 1985;99:317–20.
20. Van Rij G, Waring III GO. Configuration of corneal trephine opening using five different trephines in human donor eyes. *Arch Ophthalmol*. 1988;106:1228–33.
21. Seitz B, Langenbucher A, Kuchle M, Naumann GOH. Impact of graft diameter on corneal power and the regularity of postkeratoplasty astigmatism before and after suture removal. *Ophthalmology*. 2003;110:2162–7.
22. Seitz B, Langenbucher A, Naumann GOH. [The penetrating keratoplasty – a 100-year success story]. *Ophthalmologe*. 2005;102:11281139.
23. Seitz B, Langenbucher A, Naumann GOH. [Perspectives of excimer laser-assisted keratoplasty]. *Ophthalmologe*. 2011;108:817–24.
24. Seitz B, Langenbucher A, Zagrada D, Budde W, Kus MM. [Corneal dimensions in various types of corneal dystrophies and their effect on penetrating keratoplasty]. *Klin Monatsbl Augenheilkd*. 2000;217:152–8.
25. Graef S, Maier P, Boehringer D, Auw-Haedrich C, Reinhard T. Femtosecond laser-assisted repeat keratoplasty: a case series. *Cornea*. 2011;30:687–91.
26. Szentmáry N, Seitz B, Langenbucher A, Naumann GOH. Repeat keratoplasty for correction of high or irregular postkeratoplasty astigmatism in clear corneal grafts. *Am J Ophthalmol*. 2005;139:826–30.
27. Langenbucher A, Seitz B, Kus MM, Vilchis E, Naumann GOH. Graft decentration in penetrating keratoplasty – nonmechanical trephination with the excimer laser (193 nm) versus the motor trephine. *Ophthalmic Surg Lasers*. 1998;29:106–13.
28. Seitz B, Langenbucher A, Meiller R, Kus MM. [Decentration of donor cornea in mechanical and excimer laser trephination for penetrating keratoplasty]. *Klin Monatsbl Augenheilkd*. 2000;217:144–51.
29. Langenbucher A, Kus MM, Neumann J, Seitz B. [Calculating the localization and dimension of the real pupil in keratoconus with ray tracing of corneal topography data]. *Klin Monatsbl Augenheilkd*. 1999;215:163–8.
30. Hoffmann F. [Suture technique for perforating keratoplasty]. *Klin Monatsbl Augenheilkd*. 1976;169:584–90.
31. Jonas JB, Budde WM. Loosening of single versus double running sutures in penetrating keratoplasty for keratoconus. *Graefes Arch Clin Exp Ophthalmol*. 1999;237:522–3.
32. Naumann GOH, Seitz B, Lang GK, Langenbucher A, Kus MM. [193 excimer laser trepanation in perforating keratoplasty]. Report of 70 patients. *Klin Monatsbl Augenheilkd*. 1993;203:252–61.
33. Lang GK, Schröder E, Koch JW, et al. Excimer laser keratoplasty. Part 2: elliptical keratoplasty. *Ophthalmic Surg*. 1989;86:342–6.
34. Lang GK, Naumann GOH, Koch JW. A new elliptical excision for corneal transplantation using an excimer laser. *Arch Ophthalmol*. 1990;108:914–5.
35. Szentmáry N, Langenbucher A, Kus MM, et al. Elliptical nonmechanical corneal trephination: intraoperative complications and long-term outcome of 42 consecutive excimer laser penetrating keratoplasties. *Cornea*. 2007;26:414–20.
36. Szentmáry N, Langenbucher A, Kus MM, Naumann GOH, Seitz B. Long-term refractive results of elliptical excimer laser penetrating keratoplasty (EELPK). *Curr Eye Res*. 2007;32:953–9.
37. Kuchle M, Seitz B, Langenbucher A, Naumann GOH. Nonmechanical excimer laser penetrating keratoplasty for perforated or predecemetal corneal ulcers. *Ophthalmology*. 1999;106:2203–9.
38. Amigo G. The Maklakoff applanation tonometer. *Aust J Optom*. 1967;50:92–7.
39. Seitz B, Langenbucher A, Kus MM, Kuchle M, Naumann GOH. Nonmechanical corneal trephination with the excimer laser improves outcome after penetrating keratoplasty. *Ophthalmology*. 1999;106:1156–65.



40. Szentmáry N, Langenbucher A, Naumann GOH, Seitz B. Intra-individual variability of penetrating keratoplasty outcome after excimer laser versus motorized corneal trephination. *J Refract Surg.* 2006;22:804–10.
41. Kühle M, Nguyen NX, Seitz B, et al. Blood-aqueous barrier following mechanical or nonmechanical excimer laser trephination in penetrating keratoplasty. *Am J Ophthalmol.* 1998;125:177–81.
42. Behrens A, Seitz B, Langenbucher A, et al. Lens opacities after nonmechanical vs. mechanical corneal trephination for penetrating keratoplasty in keratoconus. *J Cataract Refract Surg.* 2000;26:1588–95.
43. Seitz B, Langenbucher A, Nguyen NX, et al. Graft endothelium and thickness after penetrating keratoplasty comparing mechanical and excimer laser trephination – a prospective randomised study. *Graefes Arch Clin Exp Ophthalmol.* 2001;239:12–7.
44. Seitz B, Langenbucher A, Diamantis A, et al. [Immunological graft reactions after penetrating keratoplasty – a prospective randomized trial comparing corneal excimer laser and motor trephination]. *Klin Monatsbl Augenheilkd.* 2001;218:710–9.
45. Seitz B, Langenbucher A, Nguyen NX, et al. Long-term follow-up of intraocular pressure after penetrating keratoplasty for keratoconus and Fuchs' dystrophy – comparison of mechanical and laser trephination. *Cornea.* 2002;21:368–73.
46. Seitz B, Rozsival P, Feuermannova A, Langenbucher A, Naumann GOH. Penetrating keratoplasty for iatrogenic keratoconus after repeat myopic laser in situ keratomileusis: histologic findings and literature review. *J Cataract Refract Surg.* 2003;29:2217–24.
47. Seitz B, Langenbucher A, Nguyen NX, Kus MM, Kühle M, Naumann GOH. [Results of the first 1000 consecutive elective nonmechanical keratoplasties with the excimer laser – a prospective study over more than 12 years]. *Ophthalmologie.* 2004;101:478–88.
48. Langenbucher A, Seitz B, Kus MM, Naumann GOH. Thermal effects in excimer laser trephination of the cornea. *Graefe's Arch Clin Exp Ophthalmol.* 1996;234:S142–8.
49. Langenbucher A, Kühle M, Seitz B, Kus MM, Behrens A, Weimel E, Naumann GOH. Thermal load of laser aperture masks in nonmechanical trephination for penetrating keratoplasty with the Er:YAG laser: comparison between stainless steel and ceramic masks. *Graefe's Arch Clin Exp Ophthalmol.* 2000;238:339–45.
50. Seitz B, Cursiefen C, El-Husseiny M, Viestenz A, Langenbucher A, Szentmáry N. [DALK and penetrating laser keratoplasty for advanced keratoconus]. *Ophthalmologie.* 2013;110:839–48.
51. Shehadeh-Mashor R, Chan CC, Bahar I, Lichtinger A, Yeung SN, Rootman DS. Comparison between femtosecond laser mushroom configuration and manual trephine straight-edge configuration deep anterior lamellar keratoplasty. *Br J Ophthalmol.* 2014;98(1):35–9.
52. Anwar M, Teichmann KD. Big-bubble technique to bare Descemet's membrane in anterior lamellar keratoplasty. *J Cataract Refract Surg.* 2002;28:398–403.
53. Seitz B, Brünner H, Viestenz A, Hofmann-Rummelt C, Schlötzer-Schrehardt U, Naumann GOH, Langenbucher A. Inverse mushroom-shaped nonmechanical penetrating keratoplasty using a femtosecond laser. *Am J Ophthalmol.* 2005;139:941–4.
54. Bahar I, Kaiserman I, Lange AP, Levinger E, Sansanayudh W, Singal N, Slomovic AR, Rootman DS. Femtosecond laser versus manual dissection for top hat penetrating keratoplasty. *Br J Ophthalmol.* 2009;93:73–8.
55. Gaster RN, Dumitrascu O, Rabinowitz YS. Penetrating keratoplasty using femtosecond laser-enabled keratoplasty with zig-zag incisions versus a mechanical trephine in patients with keratoconus. *Br J Ophthalmol.* 2012;96:1195–9.
56. Seitz B, Langenbucher A, Naumann GOH. [Astigmatism in keratoplasty]. In: Seiler T, editor. *Refraktive Chirurgie.* Stuttgart: Enke; 2000. p. 197–252.
57. Vetter JM, Holzer MP, Teping C, et al. Intraocular pressure during corneal flap preparation: comparison among four femtosecond lasers in porcine eyes. *J Refract Surg.* 2011;27:427–33.
58. Seitz B, Szentmáry N, Langenbucher A, Hager T, Viestenz A, Janunts E, El-Husseiny M. [Penetrating keratoplasty PKP in advanced keratoconus – from hand/motor trephine up to the excimer laser and back to the femtosecond laser]. *Klin Monatsbl Augenheilkd.* 2016; 233(6):727–36.

59. El-Husseiny M, Seitz B, Langenbucher A, et al. Excimer vs. femtosecond laser assisted penetrating keratoplasty in keratoconus and Fuchs dystrophy: intraoperative pitfalls. *J Ophthalmol.* 2015;2015:645830.
60. Farid M, Steiner RF, Gaster RN, Chamberlain W, Lin A. Comparison of penetrating keratoplasty performed with the femtosecond laser zig-zag incision versus conventional blade trephination. *Ophthalmology.* 2009;116:1638–43.
61. Kamiya K, Kobashi H, Shimizu K, Igarashi A. Clinical outcomes of penetrating keratoplasty performed with the VisuMax femtosecond laser system and comparison with conventional penetrating keratoplasty. *PLoS One.* 2014;9(8):e105464.
62. Levinger E, Trivizki O, Levinger S, Kremer I. Outcome of “mushroom” pattern femtosecond laser-assisted keratoplasty versus conventional penetrating keratoplasty in patients with keratoconus. *Cornea.* 2014;33:481–5.
63. Birnbaum F, Wiggermann A, Maier PC, Böhringer D, Reinhard T. Clinical results of 123 femtosecond laser-assisted keratoplasties. *Graefes Arch Clin Exp Ophthalmol.* 2013;251:95–103.
64. Chamberlain WD, Rush SW, Mathers WD, Cabezas M, Fraunfelder FW. Comparison of femtosecond laser-assisted keratoplasty versus conventional penetrating keratoplasty. *Ophthalmology.* 2011;118:486–91.
65. Szentmáry N, Goebels S, El-Husseiny M, et al. [Immune reactions following excimer laser and femtosecond laser-assisted penetrating keratoplasty]. *Klin Monatsbl Augenheilkd.* 2013;230:486–9.

# Index

## A

- Acanthamoeba keratitis, 188–189
- Ambrósio's relational thickness (ART) values, 164
- Angle kappa, 36
- Astigmatism
  - after keratoplasty
    - cardinal suture placement, 206, 207
    - causes of, 203–207
    - graft size, 204–205
    - intraoperative determinants, high and/or irregular, 204, 205
    - limbus and pupil centration, 205, 206
  - correction with LASIK, 20–21
  - hyperopic astigmatism correction, 24–25
    - in PRK vs. LASIK, 26–28
  - intraoperative prophylaxis, 200–201
  - irregular, 93
  - reasons for, 190
  - topography based keratectomy (*see* Topography based keratectomy (TBK))
  - myopic astigmatism correction, 25–26
    - PRK vs. LASIK, 28–29
  - surgically induced, 18
  - target induced, 18

## B

- Belin-Ambrósio Enhanced Ectasia Display (BAD), 164
- Bowman's membrane, 68, 129, 178–179, 182
- Broad-beam lasers, 4

## C

- Cardinal sutures, purpose of, 200, 202, 206, 216
- Connective tissue and autoimmune diseases, 40
- Contact lens test (CLT), 192
- Corneal dystrophies, 44, 187, 188
- Corneal scars, PTK for
  - ablation depth, 184
  - after herpes keratitis, 189
  - benefit, 184
  - hypertrophic corneal scars, 185
  - pathology, 195
  - posttraumatic corneal scars, 185
  - rheumatoid ulcers, 185
  - Salzmann's nodular degeneration, 186
- Corneal thickness spatial profile (CTSP) concept, 163
- Corneal tomography, ectasia, 166
  - Ambrósio's relational thickness values, 164
  - best-fit sphere, 163
  - best-fit toric ellipsoid, 163
  - corneal elevation maps, 162
  - description, 162
  - enhanced elevation concept, 163
  - after LVC, 166
  - pachymetric progression index, 163
  - PTI and CTSP concept, 163
  - segmental tomography, 165
- Cycloplegia, 35

**D**

- Decentered flap, 52–53
- DED. *See* Dry eye disease (DED)
- Diabetes mellitus (DM), 40
- Diffuse lamellar keratitis (DLK), 71
  - description, 76
  - incidence of, 76
  - internal patient factors, 76
  - intraoperative erosio corneae and smoking, 79
  - late onset, 77
  - management of, 77–79
  - staging of, 77
  - vs. superficial punctate keratitis, 77, 79

**Diplopia**

- causes of, 45
- monocular, 93
- postoperative, 46

**DLK. *See* Diffuse lamellar keratitis (DLK)****Dry eye disease (DED), 82**

- description, 86
- incidence and symptoms of, 86
- tear film osmolarity, 87
- tests for, 87

**E****Early postoperative LASIK complications**

- diffuse lamellar keratitis, 76–79
- dry eye disease, 86–87
- epithelial ingrowth, 84–86
- flap striae, 82–84
- infectious keratitis, 79–82

**Ectasia**

- Belin/Ambrósio enhanced ectasia display, 160
- clinical characteristics of, 165
- corneal tomography, 166
  - Ambrósio's relational thickness values, 164
  - best-fit sphere, 163
  - best-fit toric ellipsoid, 163
  - corneal elevation maps, 162
  - description, 162
  - enhanced elevation concept, 163
  - pachymetric progression index, 163
  - PTI and CTSP concept, 163
  - segmental tomography, 165
- due to thick corneal flap, 166, 167
- focal biomechanical failure, 165
- incidence rate, 157–158
- optical coherence tomography, 165
- pathophysiology, 158
- postoperative diagnosis, 165–166
- preoperative screening

- anterior curvature sagittal map, 159, 160

- central corneal thickness, 159
- corneal geometry analysis, 159
- description, 158–159
- ERSS, 159
- forme fruste keratoconus concept, 159–160
- Placido-disk based corneal topography, 159
  - progressive unilateral ectasia, 160, 161
- risk factors for, 158, 159
- treatment

- corneal cross-linking procedures, 168
- flap geometry analysis, 169
- glass and contact lens fitting, 168
- intracorneal ring segment implantation, 168–169
- medico-legal issues, 168
- options for, 166, 167

**Ectasia Risk Scoring System (ERSS), 159****Ectasia susceptibility score (ESS-1), 162, 164****Efficacy index (EI), 12, 25****Epi-LASIK, 129**

- epithelium removal, 131
- haze, 144

**Epithelial-basement-dystrophy (EBMD), 182****Epithelial erosions**

- consequences of, 63
- during keratectomy, 32
- risk minimization, 63

**Epithelial ingrowth (EIG), 86**

- circumferential running suture, 85, 86
- double running sutures, 85, 86
- flap lift, 85
- incidence of, 84
- morphological patterns of, 85, 86
- predisposing factors for, 84
- single interrupted sutures, 85, 86

**Errors, in corneal refractive surgery**

- cycloplagic refraction, 35
- excimer nomograms, 35–36
- flap and epithelium, 35
- refraction measurement, 33–34
- technical errors and failures, 37

**Excimer laser-assisted deep lamellar**

- keratoplasty (Excimer DALK), 213–214

**Excimer lasers, 3**

- ablation procedure, 4
- keratoplasty with, 207–213
- therapeutic application of, 5
- trephination
  - complications, 211, 213

- donor, 208, 209
- nonmechanical trephination,
  - advantages of, 208–210
  - practical considerations, 210–212
  - principle of, 208
  - recipient, 208, 209
- Excimer nomograms, 35–36
- Excimer pulses, 36
- Excimer surgery, accuracy of, 33

**F**

- Fantes grading, corneal haze, 138, 139
- Femtolaser assisted lenticule extraction (FLEX), 7
- Femtosecond laser (FSL)
  - advantages of, 214
  - flap, 51–53 (*see also* Flap malformations; Irregular flap)
  - keratoplasty
    - advantages of, 215
    - after complete suture removal, 215
    - vs. excimer laser, for PKP, 215–217
    - postoperative outcomes for, 7
  - keratotomies
    - vs. blade keratotomies, 65
    - complications of, 69–70
    - optical approaches, 66
  - technology, 6–7
  - trephination, 199–200
    - complications, 218–220
    - drawback of, 7
    - problem of, 215
- Femtosecond lenticule extraction (FLEX), 112
- Flap

- amputation procedure
  - healthy flap, 99
  - indication for, 100
  - myope with small free flap case study, 101–105
- anatomical qualities of, 51
- button hole, 55
- free, 95, 96
- incomplete (short), 53, 54
- irregular flap
  - description, 52
  - end results of, 61–62
  - technical failure/human error, 52
- malformations
  - complications of, 58
  - intra operative treatment of, 57–60
  - late management of, 61
  - minimization of, 56–57
  - topography based ablation, 61
  - types of, 52–56

- regular, 53
- small, 52, 53
- striae, 82–84
- thin, 57
- torn, 53–54
- Flying-spot lasers, 4
- Forme fruste keratoconus (FFKC) concept, 159–160
- Fuchs' dystrophy, 44, 205, 215, 217

**G**

- Glaucoma, 44–45
- Granular corneal dystrophy, PKT
  - advanced, 187, 188
  - recurrence of, 187

**H**

- Haze
  - advanced, clinical symptoms of, 138
  - after hyperopic PRK, 141
  - after myopic PRK, 139, 141
  - description, 138
  - Fantes grading of, 138
  - late-onset, 144–145
  - sub-epithelial trace haze, 139
- Herpes simplex keratitis, 43
- Hyperopia correction
  - LASIK, 21
    - astigmatism, 24–25
    - in PRK vs. LASIK, 26–28
- Hyperopic PRK, 24–25
  - vs. LASIK, 26–28
- Hypertrophic corneal scars, 185
- Hyposphagma, 218, 219

**I**

- Iatrogenic keratectasia, 121–122
- Infectious keratitis, 121, 136
  - post LASIK
    - corneal cross linking, 82
    - early onset, 80
    - gram-positive bacteria and atypical mycobacteria, 80
    - incidence of, 79
    - risk factors for, 82
    - topical therapy, 81
  - PTK for
    - acanthamoeba keratitis, 188–189
    - corneal scars after herpes keratitis, 189
- Intracorneal ring segment (ICRS)
  - implantation, 168–169

Intraocular (IOP) pressure  
 measurement, 44

Intrastromal keratotomies, 70

Irregular high-order aberrations, LASIK  
 after complicated photorefractive corneal  
 surgery, 92  
 centration, 92–93  
 corneal irregularity, 93–95  
 corneal wavefront analysis, 93  
 decentration of ablation, 92–93  
 keratectasia, 95  
 Zernike terms, 93

after uncomplicated excimer refractive  
 corneal surgery, 90–92

chromatic aberrations, 89  
 diffraction and scatter, 89  
 low-order aberrations, 88  
 topography-driven treatments, 95–96  
 treatment of, 95–96  
 vision blurring, causes and sources of,  
 88–89

wavefront-guided method, 96

Isotretinoin, 42

## K

Keratoconjunctivitis sicca. *See* Dry eye disease  
 (DED)

Keratoconus eyes, TBK, 195–196

Keratitis. *See* Infectious keratitis

Keratoplasty. *See also* Penetrating keratoplasty  
 (PKP)

astigmatism after  
 cardinal suture placement, 206, 207  
 causes of, 203–207  
 graft size, 204–205  
 high and/or irregular astigmatism,  
 intraoperative determinants of, 204,  
 205  
 limbus and pupil centration, 205, 206

femtosecond laser keratoplasty  
 advantages of, 215  
 after complete suture removal, 215  
 vs. excimer laser, for PKP, 215–217  
 postoperative outcomes for, 7  
 prevention of complications, 202

## L

LASEK, 129  
 epithelium removal, 130  
 haze, 138–141  
 pain, 133–134  
 vs. transepithelial PRK, 143

Laser, 3. *See also* Excimer lasers,  
 Femtosecond laser (FSL)

Laser-assisted in situ keratomileusis (LASIK),  
 5, 6, 33, 111  
 advantages, 19  
 astigmatic correction, 20–21  
 early postoperative complications  
 diffuse lamellar keratitis, 76–79  
 dry eye disease, 86–87  
 epithelial ingrowth, 84–86  
 flap striae, 82–84  
 infectious keratitis, 79–82

epithelial erosions  
 consequences of, 63  
 during keratectomy, 62  
 risk minimization, 63

femtosecond-laser associated  
 complications  
 diffuse lamellar keratitis, 71  
 light sensitivity syndrome, 71  
 opaque bubble layer, 71  
 suction loss and consecutive cutting  
 errors, 71–72  
 vertical gas breakthrough, 72

FSL-flap preparation, 70–72  
 for hyperopia correction, 21  
 ideal flap, anatomical qualities of, 51  
 intraoperative microkeratome-related  
 complications  
 epithelial erosions, 62–63  
 flap malformations, 52–61  
 irregular flap, 52, 61–62

late postoperative complications  
 irregular high-order aberrations,  
 88–96  
 persistent dry eye, 87–88  
 therapeutic flap amputation, 99–105  
 traumatic flap dislocation, 96–98  
 for myopia with astigmatism, 20  
 vs. PRK, efficacy of, 26–29  
 vs. topography based keratectomy, 195

Laser-induced optical breakdown process, 6

Laser vision correction (LVC) procedure, 157,  
 165

LASIK-induced neurotrophic epitheliopathy  
 (LINE), 88

Light sensitivity syndrome, 71

## M

Macrostromiae, 82–83

Manifest refractive spherical equivalent  
 (MRSE), 20

Manifest subjective refraction (MSR), 34, 35

- Microkeratome-related intraoperative complications, LASIK
  - epithelial erosions, 62–63
  - flap malformations, 52–61
  - irregular flap, 52, 61–62
- Microstriae, 82
- Mid-infrared pulses, 8
- Mitomycin-C (MMC), 142
- Myopic astigmatism correction, 25–26
  - PRK vs. LASIK, 28–29
- Myopic PRK, 25–26
  - vs. LASIK, 28–29
  
- N**
- Neuro-ophthalmic disorders, 41–42
- Non-steroidal anti-inflammatory drugs, 134–135
  
- O**
- Ocular adnexa, 43
- Opaque bubble layer (OBL), 55, 71, 116
- Ophthalmic lasers, 3
  
- P**
- Pain
  - epithelial healing time and, 133
  - non-steroidal anti-inflammatory drugs, 134–135
  - postoperative management, after surface ablation, 133, 134
  - reduction strategies, 135
  - topical anesthetics, 134
- Penetrating keratoplasty (PKP)
  - excimer vs. femtosecond laser trephination benefits of, 217, 218
  - prospective randomised study, 215–217
  - intraoperative prophylaxis, 220–221
  - preoperative prophylaxis, 200
  - trephination techniques, requirements for, 217
- Percentage thickness increase (PTI) concept, 163
- Persistent dry eye, 87–88. *See also* Dry eye disease (DED)
- Photocoagulation, 3
- Photorefractive keratectomy (PRK), 5–6, 44, 130
  - description, 5
  - drawback, 129
  - dry eye disease, 146
  - early postoperative complications
    - haze, 138–141
    - infectious keratitis, 136
    - mitomycin-C, 142
    - sterile keratitis, 137
  - for hyperopic and hyperopic astigmatism correction, 24–25
  - intraoperative complications
    - bandage contact lens, 135
    - epithelial healing time and pain, 133
    - epithelium removal, 130
    - NSAIDs, 134
    - recommendations, 131–133
  - and LASIK, 5, 24
  - late-onset haze, 144, 145
  - for myopic and myopic astigmatism correction, 25–26
  - refractive regression, 145
- Phototherapeutic keratectomy (PTK)
  - ablation profiles, 181–182
  - complication management, in refractive surgery, 189
  - corneal dystrophies, 187, 188
  - for corneal scars
    - ablation depth, 184
    - benefit, 184
    - hypertrophic corneal scars, 185
    - pathology, 185
    - posttraumatic corneal scars, 185
    - rheumatoid ulcers, 185
    - Salzmann's nodular degeneration, 186
  - goal of, 177
  - homogenous corneal surface after, 178, 179
  - indications for, 127–130, 178
  - infectious keratitis
    - acanthamoeba keratitis, 188–189
    - corneal scars after herpes keratitis, 189
  - irregular Bowman-lamella/stromal surface, 178, 179
  - paracentral corneal irregularities/scars, 178
  - for recurrent erosion
    - Allegretto Wavelight Excimer Laser System, 181
    - clinical signs, 182
    - epithelial-basement-dystrophy, 182, 183
    - and PRK, 183
    - treatment, 182–183
    - risk factor, 181
- Picosecond infrared laser (PIRL) keratoplasty, 8
- Posttraumatic corneal scars, 185
- Progressive iatrogenic keratectasia, 157, 158

Pseudo-ring-shaped automated Schwind  
 AMARIS excimer laser ablation  
 profile, 208, 209  
 Psychiatric disorders, 41  
 PTK. *See* Phototherapeutic keratectomy (PTK)  
 Purkinje image, 36

## R

Radial keratotomy (RK), 66–67  
 marker, 205, 206  
 Recurrent corneal erosion, PTK for  
 Allegretto Wavelight Excimer Laser  
 System, 181  
 clinical signs, 182  
 epithelial-basement-dystrophy, 182, 183  
 and PRK, 183  
 treatment, 182–183  
 Refractive corneal surgery  
 corneal dystrophies, 43  
 effectiveness and safety, 12–13  
 efficacy index, 12  
 general clinical history, 39  
 glaucoma, 44–45  
 herpes simplex keratitis, 43  
 immunosuppression by drugs, 42  
 ocular adnexa, 43  
 patient satisfaction, 11  
 phototherapeutic keratectomy (*see*  
 Phototherapeutic keratectomy  
 (PTK))  
 predictability of  
 cylindrical correction, 16, 18  
 dioptic change, 13, 15–16  
 spherical equivalent, 15–17  
 pregnancy and breastfeeding, 42  
 retinal lesions, 46  
 safety index, 12–13  
 Snellen chart lines, 12–14  
 strabismus, 45–46  
 in systemic diseases  
 connective tissue and autoimmune  
 diseases, 40–41  
 diabetes mellitus, 40  
 HIV and hepatitis, 41  
 neuro-ophthalmic disorders, 41–42  
 psychiatric disorders, 41  
 skin queloids, 41  
 target of, defined, 11  
 topography based keratectomy (*see*  
 Topography based keratectomy  
 (TBK))  
 uveitis, 45  
 visual acuity, 11–13

Refractive lenticule extraction (ReLEx®)  
 advantages, 113  
 femtosecond lenticule extraction, 112  
 myopia and myopic astigmatism  
 correction, 112  
 VisuMax® femtosecond laser, 112  
 Relaxing keratotomy  
 vs. astigmatic keratotomies, 68  
 description, 67  
 limited precision of, 67  
 Rheumatoid corneal ulcers/scars, 185

## S

Safety index (SI), 12–13  
 Salzmann's nodular degeneration, 186  
 Scanning-slit lasers, 4  
 Scars, corneal  
 after herpes keratitis, 189  
 hypertrophic, 185  
 rheumatoid, 185  
 posttraumatic, 185  
 with PTKI, 183  
 Skin queloids, 41  
 Small incision lenticule extraction (SMILE), 7  
 advantages of, 114  
 cutting error, 73, 74  
 description, 72  
 efficacy of, 112  
 peri-operative complications  
 black spots, 116  
 cap perforation/tear, 117, 118  
 diffuse haze at stromal interface, 117,  
 118  
 epithelial defects, 117  
 incomplete lenticule extraction,  
 116–117  
 incompletely cut lenticules, 115–116  
 opaque bubble layer formation, 116  
 suction loss, 114–115  
 postoperative complications  
 biomechanical changes, 121–122  
 Bowman's microdistortions, 119  
 corrected distance visual acuity, loss in,  
 120  
 epithelial cell island, 119, 120  
 iatrogenic keratectasia, 121–122  
 infectious keratitis, 121  
 interface haze development, 119  
 interface sterile inflammation, 119  
 monocular ghost-image development,  
 120, 121  
 stromal microstriae, 119  
 surface dryness, 118–119



- refractive success rates, 73
  - short time safety of, 113
  - visual rehabilitation, 73
  - Snellen chart lines, 12–14
  - Sterile keratitis, 137
  - Strabismus, 45–46
  - Stromal dystrophies, 44
  - Sumatriptan, 42
  - Superficial punctate keratitis (SPK) *vs.* diffuse lamellar keratitis, 77, 79
  - Surface ablation technique, 5, 6. *See also* Photorefractive keratectomy (PRK)
    - early postoperative complications
      - ablation depth, 144
      - antiinflammatory drugs, 142
      - epithelial removal, 142–144
      - haze, 138–141
      - infectious keratitis, 136
      - mitomycin-C, 142
      - sterile keratitis, 137
    - epithelial removal techniques in, 127, 128
    - intraoperative complications
      - irregular ablation, 130–131
      - pain, 133–135
      - recommendations, 131–133
    - late postoperative complications
      - late-onset haze, 144–145
      - persistent dry eye, 146–147
      - regression, 145–146
    - principle of, 127
  - Surgically induced astigmatism (SIA), 18
  - Symmetric intrastromal arcuate keratomies, 68
- T**
- Target induced astigmatism (TIA), 18
  - TBK. *See* Topography based keratectomy (TBK)
  - Therapeutic flap amputation. *See* Flap, amputation procedure
  - Topical anesthetic eye drops, 134
  - Topical mitomycin-C, 142
  - Topography based keratectomy (TBK), 197
    - ablation plan of, 192–194
    - Allegretto excimer laser and topolyzer, 192, 193
    - contact lens test, 192
    - indications for, 78, 127–130, 190–192
    - keratoconus eyes, 195–196
    - vs.* LASIK, 194
    - visual acuity and quality, 192
  - Transepithelial PRK (t-PRK), 129, 132
  - Transepithelial PTK, 179–181
  - Traumatic flap dislocation, LASIK, 96
    - diagnosis, 97
    - severity of, 97
    - surgical treatment, 98
  - Trephination
    - excimer lasers
      - complications, 211, 213, 214
      - donor, 208, 209
      - nonmechanical trephination, advantages of, 208–210
      - practical considerations, 210–212
      - principle of, 208
      - recipient, 208, 209
    - femtosecond laser, 199–200
    - complications, 218–220
      - drawback of, 7
      - problem of, 215
    - mechanical, 202
- U**
- Uveitis, 45
- V**
- Vacuum, MK/FSL fixation, 37
  - Visual acuity (VA), 11
    - parameters, 12
    - terms and abbreviations, 12, 13
  - VisuMax® femtosecond laser, 112
- W**
- Wave front optimized ablation, 27
  - Wound healing
    - corneal, 5
    - delayed, 131, 178, 189
- Z**
- Z-scan, 73